

Retraction

Retracted: The Value of CT Angiography Based on Intelligent Segmentation Algorithm for Survival of Hemodialysis Patients

Computational and Mathematical Methods in Medicine

Received 5 December 2023; Accepted 5 December 2023; Published 6 December 2023

Copyright © 2023 Computational and Mathematical Methods in Medicine. This is an open access article distributed under the Creative Commons Attribution License, which permits unrestricted use, distribution, and reproduction in any medium, provided the original work is properly cited.

This article has been retracted by Hindawi, as publisher, following an investigation undertaken by the publisher [1]. This investigation has uncovered evidence of systematic manipulation of the publication and peer-review process. We cannot, therefore, vouch for the reliability or integrity of this article.

Please note that this notice is intended solely to alert readers that the peer-review process of this article has been compromised.

Wiley and Hindawi regret that the usual quality checks did not identify these issues before publication and have since put additional measures in place to safeguard research integrity.

We wish to credit our Research Integrity and Research Publishing teams and anonymous and named external researchers and research integrity experts for contributing to this investigation.

The corresponding author, as the representative of all authors, has been given the opportunity to register their agreement or disagreement to this retraction. We have kept a record of any response received.

References

- [1] W. Luo, R. Zhang, D. He et al., “The Value of CT Angiography Based on Intelligent Segmentation Algorithm for Survival of Hemodialysis Patients,” *Computational and Mathematical Methods in Medicine*, vol. 2022, Article ID 6470576, 8 pages, 2022.

Research Article

The Value of CT Angiography Based on Intelligent Segmentation Algorithm for Survival of Hemodialysis Patients

Wei Luo ¹, Ruidong Zhang ¹, Da He ², Zhenyi Sun ¹, Yunlong Zhou ³, Li Cheng ², and Hongbo Li ²

¹Second Department of Orthopaedics, Longkou Hospital of Traditional Chinese Medicine, Longkou, 265700 Shandong Province, China

²Department of Nephrology, Wuhan No. 1 Hospital, Wuhan, 430022 Hubei Province, China

³Department of Medicine, Longkou Hospital of Traditional Chinese Medicine, Longkou, 265700 Shandong Province, China

Correspondence should be addressed to Hongbo Li; 150711058@stu.sxit.edu.cn

Received 24 October 2021; Revised 10 December 2021; Accepted 22 December 2021; Published 19 January 2022

Academic Editor: Osamah Ibrahim Khalaf

Copyright © 2022 Wei Luo et al. This is an open access article distributed under the Creative Commons Attribution License, which permits unrestricted use, distribution, and reproduction in any medium, provided the original work is properly cited.

This study was to explore the application value for central venous stenosis and occlusion in hemodialysis patients under the CT angiography based on intelligent segmentation algorithm, so that patients can survive better. Spiral CT was used to examine upper limb swelling in 62 uremic hemodialysis patients at a speed of 3.8 mL/s. Nonionic iodine contrast agent was injected around the contralateral limb. The total dosage of 90-102 mL, it was scanned by intelligent trigger technology. The trigger scanning threshold was set. The monitoring point was located in the superior vena cava. CT with convolutional neural network intelligent segmentation algorithm was used to process image data. Finally, the quality of life and related biochemical levels of patients before and after hemodialysis were detected. Under the CT angiography of intelligent segmentation algorithm, 77 stenoses were found in 62 uremic patients, including 48 stenoses of the brachial vein and 17 stenoses of the superior vena cava. The correlation coefficient between CT angiography and digital subtraction angiography (DSA) imaging results of intelligent segmentation algorithm was 0.411. Segmentation effect of the algorithm in this study: automatic segmentation accuracy was greater than 79%. After hemodialysis treatment, the scores of physical fitness, pain, social function, and energy status of patients were significantly increased compared with those before treatment, and the levels of albumin, serum phosphorus, and parathyroid hormone were significantly decreased ($P < 0.05$). In summary, CT angiography with intelligent segmentation algorithm can obtain clear, intuitive, and complete vascular walking images, and better display subclavian vein, brachiocephalic vein, and superior vena cava. It can provide more valuable support for surgical intervention and has certain application value for better survival of hemodialysis patients.

1. Introduction

Nephropathy is a common chronic disease, and its incidence rate is increasing year by year, increasing the burden of end-stage renal disease treatment [1]. Hemodialysis is the main treatment and survival method for patients with end-stage renal disease [2], but it has many cardiovascular and cerebrovascular complications and high mortality. Even in economically developed western countries such as the United States, the annual mortality of maintenance hemodialysis patients is still as high as 21-31% [3]. With the continuous improvement of hemodialysis technology, the long-term

survival rate of maintenance hemodialysis patients is also increasing [4]. How to improve the quality of life of maintenance hemodialysis patients has attracted extensive attention of patients and even the whole society and has gradually become a reliable index for comprehensive evaluation of dialysis effect [5]. However, due to the particularity of treatment plan and condition, patients are prone to a series of negative psychological effects, which seriously affect the patient's physiological and social function, quality of life, and dialysis quality [6]. The formation of stenosis is the main reason for the loss of vascular access function in hemodialysis, and central venous occlusive diseases (CVOD) is an important reason

for the loss of arteriovenous fistula function in uremic patients, with an incidence of 29% [7].

In this study, a three-dimensional full-convolutional neural network was used. The objective was to perform fine segmentation of the renal region obtained in the first stage. To solve the problem of unclear boundary differentiation in renal angiography, a shape branch network based on dual attention 3DUnet and gated convolution layer was designed. Studies have shown that the temporary or long-term use of dialysis tube is closely related to central vein stenosis. The incidence of central vein stenosis and occlusion caused by long-term indwelling dialysis tube in central vein can reach 18-40% [8, 9]. The National Kidney Foundation/Kidney Disease Outcomes Quality Initiative (NKF/KDOQI) recommends that the proportion of patients using deep venous catheter as hemodialysis vascular pathway should be controlled below 10.1%, and the proportion of uremic patients using arteriovenous fistula should exceed 49% [10]. The A-V Fistula First Breakthrough Initiative (FFBI) even recommends that all patients suitable for dialysis implement arteriovenous fistula dialysis [11]. It is a consensus at home and abroad to avoid central venous intubation and carry out long-term dialysis by establishing internal fistula [12, 13]. However, when uremic patients are just diagnosed or arteriovenous fistula is not yet mature, temporary or long-term dialysis tubes are still needed to maintain hemodialysis. Therefore, more than 20.2% of patients still use central venous catheter as dialysis vascular pathway [14]. Therefore, early diagnosis and intervention of stenosis is particularly important to prolong the life of vascular access [15]. Doppler ultrasound and angiography are important methods for diagnosing central venous vascular dysfunction [16]. However, due to gas interference, ultrasonic diagnosis of central vein is poor [17]. Although angiography is the gold standard for the diagnosis of vascular diseases, digital subtraction angiography (DSA) is an invasive examination, which can only show the blood flow in the cavity and cannot show the spatial relationship of adjacent tissue structures [18]. Therefore, it is necessary to check CT angiography with intelligent segmentation algorithm before CVOD intervention. It has the advantages of low invasiveness, low contrast agent requirements, and high spatial resolution, combined with a variety of image reconstruction modes supported by computer software. Three dimensional images of blood vessels can be clearly reconstructed [19].

In this study, CT angiography with intelligent segmentation algorithm was used to explore its application value in CVOD for the survival of hemodialysis patients and its guiding value in interventional surgery, so as to help hemodialysis patients survive better.

2. Materials and Methods

2.1. Research Object. From January 2019 to May 2020, 62 hemodialysis patients with upper limb swelling uremia in hospital were included, aged (53.20 ± 15.33) years. There were 24 males, aged from 30 to 78 years, with a median age of 57.64 years. There were 38 females, aged 22-76 years, with a median age of 52.31 years. The main diseases were 23

cases of chronic nephritis, 3 cases of diabetic nephropathy, 2 cases of congenital polycystic kidney, 1 case of congenital renal tubular acidosis, 1 case of membranous nephropathy, 3 cases of benign renal arteriosclerosis, 3 cases of multiple renal calculi, and 26 cases of unknown etiology. Almost all patients underwent long-term dialysis catheter implantation in internal jugular vein or subclavian vein and limb arteriovenous fistula. The number of central venous catheterization was 0.91 times/person. The central venous catheterization sites were left internal jugular vein in 19 cases, right internal jugular vein in 26 cases, left subclavian vein in 2 cases, and right subclavian vein in 10 cases. Clinical manifestations include internal fistula, insufficient blood flow, swelling of upper limbs or face with pigmentation, and chest wall varicose veins.

(1) Inclusion criteria: age ≥ 18 years; patients were willing to accept SGA evaluation and related anthropometric indicators. (2) Exclusion criteria: patients participate in other MatSnip therapeutic studies; renal transplant patients; patients with malignant tumors, active pulmonary tuberculosis, and other liver diseases or metabolic diseases such as hyperthyroidism and adrenal diseases in the past three months; patients fail to meet standards, incomplete data, or not cooperating with the experimenter. This study has been approved by medical ethics committee of hospital, and the family members of the patients participating in the study have signed the consent form

2.2. CT Scan. Spiral CT was used to scan from submandibular surface to diaphragmatic surface. Multislice spiral CT (MSCT) was performed, and then enhanced scanning was performed. 90-102 mL iodine contrast agent and 28 mL normal saline were injected into the nonswelling side of forearm with high-pressure syringe. The injection rate of the contrast agent was controlled at 3.8 mL/s. The intelligent trigger technology is used for scanning, the trigger scanning threshold is set, and the monitoring point is located in the superior vena cava. Its scanning parameters are current 300 mA, voltage 120 kV, speed 0.4 s/coil, width $0.589 \text{ mm} \times 63 \text{ mm}$, and reconstruction thickness 4.9 mm, 515×515 . After scanning, the scanned data is transmitted to the data station for post-processing and reconstruction. For patients with a small amount of residual renal function, dialysis shall be arranged immediately after CT examination, and the contrast medium shall be removed from the body as soon as possible to protect the patient's residual renal function.

2.3. Image Segmentation by Artificial Intelligence Algorithm. The CT images were sent to EBW workstation for MPR, MIP, MINP, and processing. The anatomy was needed to be understood and drawn. The goal of the first stage was to segment the kidney region in advance in the CT sequence image, because the kidney is different. Compared with the background, the number of voxels is more balanced, and the segmentation is relatively simple. In order to improve the feature extraction ability of 3DUnet, a three-dimensional residual dual attention module was designed, and a residual dual attention 3DUnet (RDA-3DUNET) segmentation model was constructed for kidney segmentation

combined with random clipping voxel block size. The purpose of the dual attention mechanism is to pay attention to the spatial information and channel information of feature map in the convolution operation process, so that the information of each dimension gets more attention. The information between the two dimensions of space and channel does not intersect and is independent of each other. However, the difference of 3D fully convolutional neural network is that the spatial information of feature map is changed from 2D to 3D, so the attention mechanism is easy to expand from 2D to 3D. The difference is that all convolution and pool operations are replaced by corresponding three-dimensional operations, and all batch normalization is replaced by instance normalization. The reason is that the data input by the network is three-dimensional data, and the batch size is limited by the memory of the display card. BN is normalized in the batch dimension, and the effect is better when the batch size is large, while IN is normalized in the three spatial dimensions, and it is applicable when the batch size is small and can be based on 3d residual double.

However, the difference of 3D fully convolutional neural network is that the spatial information of feature map is changed from 2D to 3D, so the attention mechanism is easy to expand from 2D to 3D. The difference is that all convolution and pool operations are replaced by corresponding three-dimensional operations, and all batch normalization is replaced by instance normalization. The reason is that the data input by the network is three-dimensional data, and the batch size is limited by the memory of the display card. BN is normalized in the batch dimension, the effect is better when the batch size is large, while IN is normalized in the three spatial dimensions, and it is applicable when the batch size is small. The residual double attention 3DUnet segmentation model can be constructed according to the 3D residual double attention module. Table 1 shows the parameter settings of encoder structure.

The second stage is aimed at fine segmentation of the kidney region obtained in the first stage. Aiming at the problem of unclear boundary differentiation in renal angiography, a shape branch network based on residual dual attention 3DUnet and gated convolution layer operation is designed. A gated shape residual dual attention 3DUnet (GS-RDA-3DUNET) model is established. The characteristic of GS-RDA-3DUNET is that SHAPE branch network can focus on the feature extraction of angiography boundary and assist the backbone network to improve the final segmentation efficiency.

The backbone network is a residual double-attention 3DUnet model, which sets the parameters of encoder and bottleneck layer. The tumor shape branch network consists of cascade gated convolution layer, RADA-3D module, trilinear interpolation, and $1 \times 1 \times 1$ convolution, which is used to transmit the shape features of the tumor from forward to backward. The function of RDA-3D module is to extract boundary features, the function of trilinear interpolation is to adjust the size of feature map, and the function of $1 \times 1 \times 1$ convolution is to reduce the number and dimension of channels. Then, the semantic features of the backbone

TABLE 1: Parameter settings of Unet encoder.

Type	Size	Output size
Convolution layer	$4 \times 4 \times 4/1$	$70 \times 150 \times 150 \times 20$
Maximum pooling layer	$1 \times 3 \times 3/(1, 3, 3)$	$70 \times 70 \times 70 \times 20$
Convolution layer	$4 \times 4 \times 4/1$	$70 \times 70 \times 70 \times 50$
Maximum pooling layer	$3 \times 3 \times 3/3$	$30 \times 30 \times 30 \times 50$
3D module	—	$70 \times 150 \times 150 \times 20$
Maximum pooling layer	$3 \times 3 \times 3/3$	$70 \times 150 \times 150 \times 20$
3D module	—	$70 \times 150 \times 150 \times 20$
Maximum pooling layer	$3 \times 3 \times 3/3$	$70 \times 150 \times 150 \times 20$
3D module	—	$70 \times 150 \times 150 \times 20$
Maximum pooling layer	$3 \times 3 \times 3/3$	$70 \times 150 \times 150 \times 20$

network and the boundary features of the shape branch network are fused to obtain accurate segmentation results. The output boundary graph of the shape branch is expressed as $f \in D^{A \times U \times Q}$, and the output characteristic graph of the backbone network is expressed as $C \in D^{A \times U \times Q}$. The feature map of the shape branch network is in series with the output feature map of the main network. After $1 \times 1 \times 1$ convolution and soft-max, the final prediction mask is output. The equation may be expressed as follow.

$$S = \text{soft} - \max \left(Z_{1 \times 1 \times 1} \left(\int f \| c \right) \right). \quad (1)$$

In the training process, the artificial labeled segmentation mask is segmented, and the real tumor boundary mask is obtained. The prediction boundary graph S adopts standard binary cross entropy (BCE) loss, and the prediction semantic segmentation F adopts dice loss (DL). The joint loss function is used to jointly monitor segmentation and boundary graph prediction. The equation is as follows.

$$I_{\text{joint}} = \alpha_1 I_{\text{BCE}}(f, f^{\wedge}) + \alpha_2 I_{\text{RI}}(s, o^{\wedge}). \quad (2)$$

$f^{\wedge} \in D^{A \times U \times Q}$ is the true value of the kidney boundary, $o^{\wedge} \in D^{A \times U \times Q}$ is the true value of the segmentation mask, and α_1, α_2 are two hyperparameters to control the weight between loss. In this study, $\alpha_1 = \alpha_2 = 1$. The structure of classical convolutional neural network composed of convolutional neural layer and normalization layer is shown in Figure 1.

2.4. Image Analysis and Observation Indicators. Two radiologists with more than 10 years of CT diagnosis experience read the images. Vascular access under MIP, VR, and 3D images was evaluated, and the sagittal, coronal, and cross-sections were carefully observed. The dynamic 3D movie can reverse the meaningful vascular site from any angle, comprehensively showing the location of central venous stenosis, the degree and scope of vascular stenosis, and the existence of collateral circulation. The degree of stenosis was determined by vessel diameter at the stenosis site and

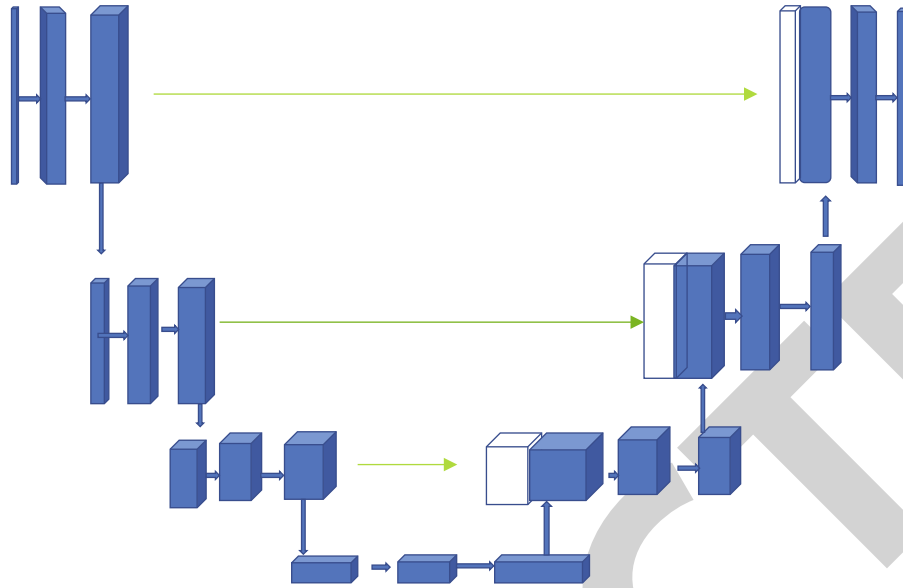


FIGURE 1: UNet network data analysis model.

adjacent normal vessel diameter as measured by MIP reconstruction. 49% to 69% patients held a moderate attitude. 70% ~99.9% are severe. 100% are complete occlusion.

2.5. Evaluation Indicators. The health status questionnaire was used to evaluate the patient, the patients were informed the filling method, and required to complete the questionnaire alone. Indicators included physical fitness, pain, social function, and energy status of patients. Our evaluation indicators also included hospital data. They are prealbumin, blood phosphorus, and parathyroid hormone.

2.6. Statistical Analysis. SPSS16 software was used to complete the statistics. The measurement data was expressed by $(\bar{x} \pm s)$, and the counting data were expressed by frequency or percentage (%). Kappa was used to analyze the correlation between different data. $P < 0.05$ was statistically significant.

3. Results

3.1. Evaluation of CT Image Segmentation Effect Based on Artificial Intelligence Segmentation Algorithm. Kidney segmentation is a part of the digital analog renal surgery planning system. It is a system that can assist the treatment of renal diseases. The new medical equipment provides a visual platform for renal embolization, surgical resection, and interventional radiotherapy. With the help of the simulation system, doctors can make the operation plan and formulate a reasonable operation plan, so as to select the best operation path and reduce the injury, and improvement of the accuracy of renal localization, the complexity of operation, and the success rate of operation are important. The main technical indexes are the automatic segmentation accuracy is greater than 79%, the reconstruction accuracy of multidimensional visible kidney can be observed at any angle, and the reconstruction accuracy is not lower than

the original input CT resolution; the calculation error is less than 8.9%. The following figure is the result of segmentation of target region in CT image by renal CT angiography and algorithm, as shown in Figure 2.

3.2. Imaging Examination. The intelligent segmentation algorithm was used to perform CT angiography for all patients to show the location of central venous stenosis. A total of 77 stenoses were found in 62 uremic patients, as shown in Figure 3, including 48 stenoses of the brachiocephalic vein (31 stenoses of the right brachiocephalic vein and 17 stenoses of the left brachiocephalic vein) and 17 stenoses of the superior vena cava. 12 subclavian vein stenoses (10 right subclavian vein and 2 left subclavian vein). As shown in Figure 4, there were 2 mild stenoses, 20 moderate stenoses, 23 severe stenoses, and 32 complete occlusions. As shown in Figure 5, DSA angiography showed 6 mild stenosis, 15 moderate stenoses, 6 severe stenoses, and 50 complete occlusions. Although there is a certain difference between CT angiography and DSA values of intelligent segmentation algorithm, the correlation coefficient between CT angiography and DSA of intelligent segmentation algorithm is 0.411, and the degree of stenosis is consistent. Lateral circulation was observed in 37 of 62 uremic patients by CT angiography with naked eyes and intelligent segmentation algorithm. All patients had unilateral or bilateral upper limb swelling, and 5 patients had facial swelling.

3.3. Changes in Quality of Life of Patients before and after Hemodialysis. The differences of physical fitness, pain, social function, and energy status of patients before and after hemodialysis were compared through the scale. The results are shown in Figure 6 (Table 2). After hemodialysis, the scores of physical fitness, pain, social function, and energy status of patients were significantly higher than those before dialysis, and the difference was statistically significant ($P < 0.05$).

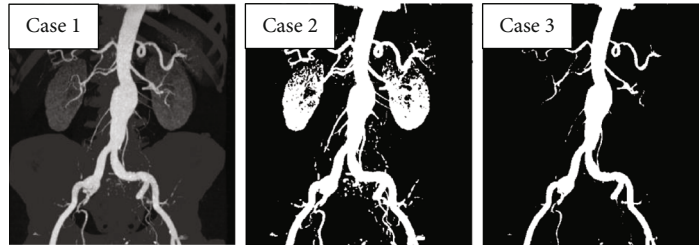


FIGURE 2: Results of target region segmentation in CT images by CT angiography images and algorithms of kidney.

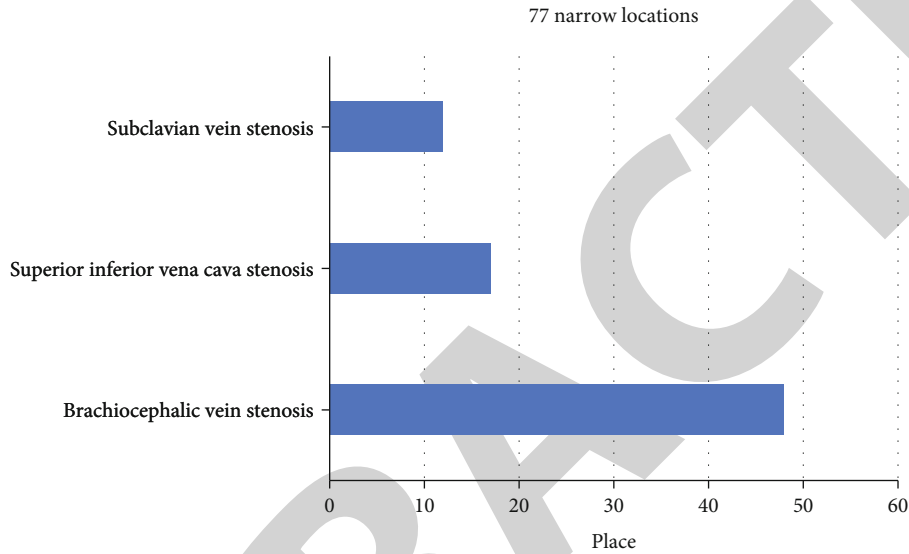


FIGURE 3: The narrow position obtained by CT angiography using intelligent segmentation algorithm.

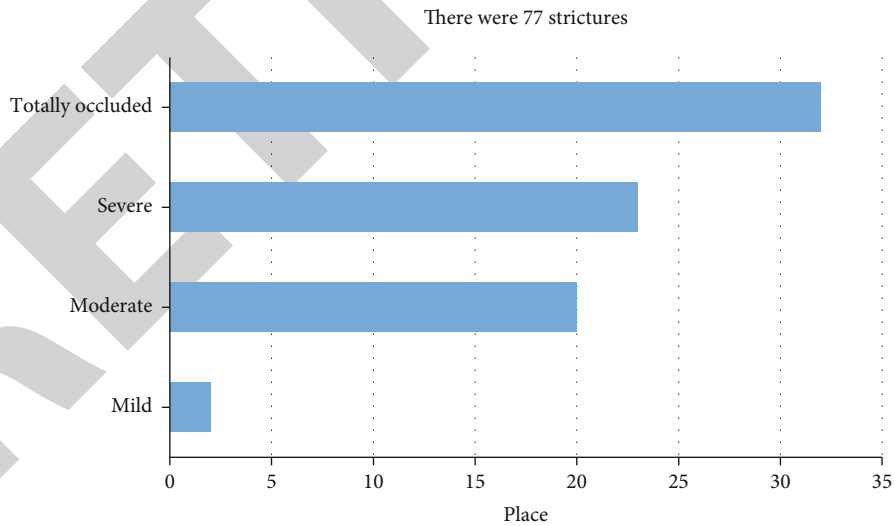


FIGURE 4: Degree of stenosis in CT angiography using intelligent segmentation algorithm.

The changes of albumin, blood phosphorus, and parathyroid hormone before and after hemodialysis were compared. The results are shown in Figure 7. The levels of albumin, blood phosphorus, and parathyroid hormone after hemodialysis were significantly lower than those before dialysis, and the difference was statistically significant ($P < 0.05$).

4. Discussion

In many centers, dysfunction of vascular access has become the primary cause of hospitalization in hemodialysis patients [4]. Stenosis is the main cause of vascular access dysfunction in dialysis, and early diagnosis and intervention of stenosis

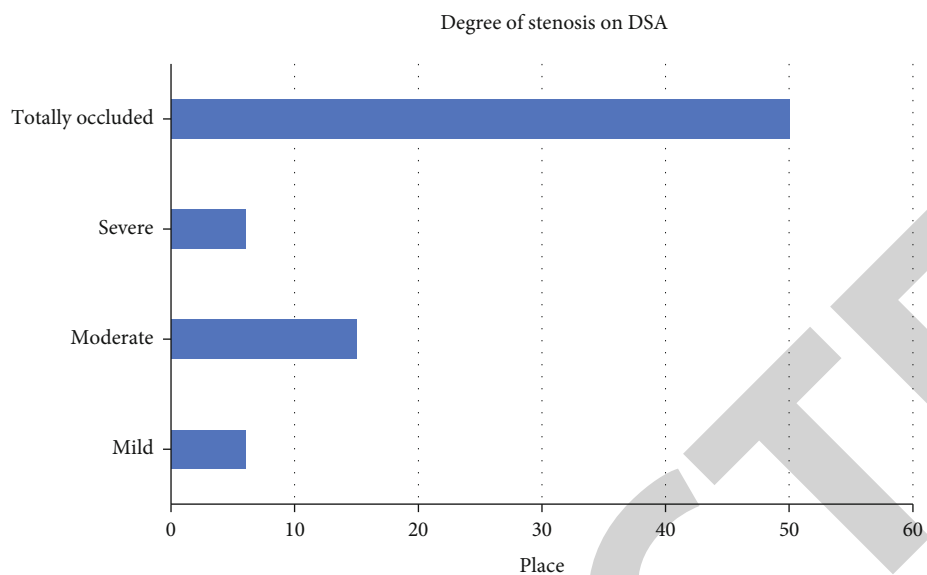


FIGURE 5: The location of stenosis displayed by DSA angiography.

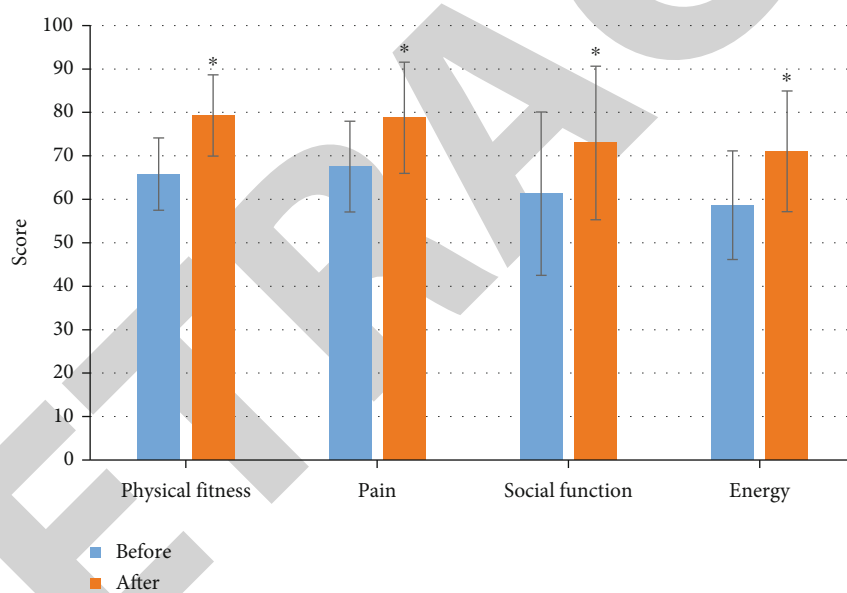


FIGURE 6: Changes of physical fitness, pain, social function, and energy status of patients before and after hemodialysis. (* $P < 0.05$, the difference between groups was statistically significant).

TABLE 2: Changes in quality of life of patients before and after hemodialysis.

Dimension	Before hemodialysis	After hemodialysis	T	P
Physical fitness	65.8 ± 18.33	79.32 ± 19.34	-2.342	0.027
Pain	67.53 ± 30.45	78.76 ± 12.78	-2.546	0.032
Social function	61.31 ± 20.63	72.98 ± 17.68	-2.221	0.039
Energy status	58.62 ± 22.05	71.02 ± 13.89	-2.124	0.028
Prealbumin	2885 ± 89.5	348.2 ± 85.1	-2.223	0.023
Blood phosphorus	$2.380.46 \pm 0.34$	2.11 ± 0.42	2.004	0.039
Parathyroid hormone	553.27 ± 376.43	333.68 ± 245.56	2.043	0.036

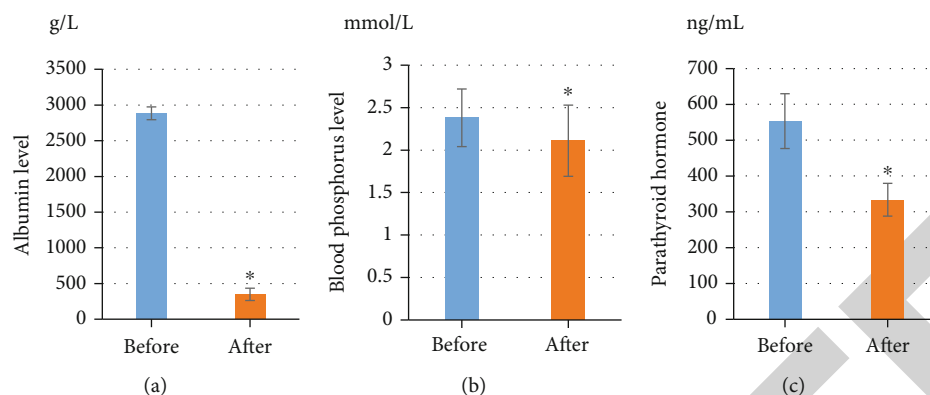


FIGURE 7: Changes of albumin, serum phosphorus, and parathyroid hormone levels in patients before and after hemodialysis. (* $P < 0.05$, the difference between groups was statistically significant).

are critical to prolong the life of vascular access [20, 21]. In this study, 62 patients were treated with interventional surgery guided by CT angiography after intelligent segmentation algorithm. Balloon dilatation was performed in 5 patients with stenosis, and 14 of them were successful only by balloon dilatation. 41 patients with unsatisfactory lumen patency after balloon dilatation underwent stent implantation. After angiography, the collateral circulation was significantly reduced, and the hemodialysis pathway was unobstructed. The upper limb or facial swelling was significantly reduced on the third day after operation. In this study, the proportion of stent implantation is relatively high, accounting for 7/10 of the total number of cases. The main reason is that these patients have a high degree of occlusion, and venous lumen retraction still occurs after PTA expansion [22].

The intelligent segmentation algorithm of CT angiography has extremely important guiding significance for subsequent interventional surgery. By accurately determining the length and location of diseased vessels, it can help to select the mode of interventional therapy [23]. It can accurately judge the tissue structure of adjacent important organs, which is conducive to the evaluation of surgical risk [24]. CT angiography with intelligent segmentation algorithm is based on the image of vascular wall and whether the cavity is filled with contrast agent, so as to judge whether there is potential vascular cavity anatomically [25]. Due to the interference of volume effect, CT angiography by intelligent segmentation algorithm has a higher possibility of false negative in the degree of stenosis. CT angiography with intelligent segmentation algorithm can also reduce the narrow range. As shown by the data in this study, 32 cases of complete occlusion were found by CT angiography with intelligent segmentation algorithm, while 50 cases were confirmed by DSA. However, CT angiography with intelligent segmentation algorithm has its own advantages in evaluating vascular calcification, which is not only an important factor in judging the difficulty of treatment but also plays a certain role in suggesting the course of the original vascular lumen [26].

CT angiography with intelligent segmentation algorithm can clearly show vascular calcification, which is better than DSA. Although CT angiography with intelligent segmentation algorithm can clearly detect central venous stenosis, it

is impossible to determine the old and new degree of thrombosis at the stenosis unless there is calcification [27]. In conclusion, the results of this study show that CT angiography with intelligent segmentation algorithm can detect intravascular ultrasound and determine the nature of vascular configuration and stenosis, which may lead to changes in surgical methods in the future. The CT angiography with intelligent segmentation algorithm can get a clear and complete blood vessel walking image, which can well display the subclavian vein, brachiocephalic vein, and superior vena cava, which can provide meaningful guidance for surgical intervention. Subsequently, the results of this study showed that the quality of life of patients after hemodialysis treatment was significantly improved, and the levels of blood phosphorus, albumin, and parathyroid hormone in blood were reduced.

5. Conclusion

A total of 62 hemodialysis patients with upper limb swelling uremia in our hospital were included. Health status questionnaire was used to evaluate the patients, and the patients' physical strength, pain, social function, and energy status were evaluated, as well as hospital data of prealbumin, blood phosphorus, and parathyroid hormone were also included. Segmentation effect of the algorithm in this study: automatic segmentation accuracy is greater than 79%, the CT angiography of intelligent segmentation algorithm can obtain clear, intuitive, and complete vascular images, better display subclavian vein, brachiocephalic vein, and superior vena cava, provide more valuable support for surgical intervention, and have certain application value for better survival of hemodialysis patients. In this study, the sample size is small, and more people should be included in the experiment. Clinical trials should be carried out in a multi-center, large sample hospitals. It hopes to help hemodialysis patients better survive.

Data Availability

The data used to support the findings of this study are available from the corresponding author upon request.

Conflicts of Interest

The authors declare no conflicts of interest.

References

- [1] V. Premuzic, R. Smiljanic, D. Perkovic, B. B. Gavranic, B. Tomasevic, and B. Jelakovic, "Complications of permanent hemodialysis catheter placement; need for better pre-implantation algorithm?," *Therapeutic Apheresis and Dialysis*, vol. 20, no. 4, pp. 394–394, 2016.
- [2] C. H. Yang, Y. K. Kao, L. Y. Chuang, and Y. D. Lin, "Catfish Taguchi-based binary differential evolution algorithm for analyzing single nucleotide polymorphism interactions in chronic dialysis," *IEEE Transactions on NanoBioscience*, vol. 17, no. 3, pp. 291–299, 2018.
- [3] S. Stoumpos, A. Tan, P. Hall Barrientos et al., "Ferumoxylol MR angiography versus duplex US for vascular mapping before arteriovenous fistula surgery for hemodialysis," *Radiology*, vol. 297, no. 1, pp. 214–222, 2020.
- [4] M. A. Garfinkle, S. Stewart, and R. Basi, "Incidence of CT contrast agent-induced nephropathy: toward a more accurate estimation," *American Journal of Roentgenology*, vol. 204, no. 6, pp. 1146–1151, 2015.
- [5] N. Li, H. Huang, H. Z. Qian, P. Liu, H. Lu, and X. Liu, "Improving accuracy of estimating glomerular filtration rate using artificial neural network: model development and validation," *Journal of Translational Medicine*, vol. 18, no. 1, p. 120, 2020.
- [6] S. Lombardi, H. L. Kutzler, S. Moradi et al., "Deceased donor kidney transplant complicated by spontaneous rupture of native kidney in a HIV patient," *CEN Case Reports*, vol. 9, no. 2, pp. 182–185, 2020.
- [7] A. M. Winkler and C. A. Tormey, "Pathology consultation on monitoring direct thrombin inhibitors and overcoming their effects in bleeding patients," *American Journal of Clinical Pathology*, vol. 140, no. 5, pp. 610–622, 2013.
- [8] N. Sadaghianloo, E. Jean-Baptiste, M. S. Islam, A. Dardik, S. Declémy, and R. Hassen-Khodja, "Vascular access thrombosis in France: incidence and treatment patterns," *Annals of Vascular Surgery*, vol. 29, no. 6, pp. 1203–1210, 2015.
- [9] B. Cimsit, M. Schilsky, M. Moini et al., "Combined liver kidney transplantation: critical analysis of a single-center experience," *Transplantation Proceedings*, vol. 43, no. 3, pp. 901–904, 2011.
- [10] M. A. Nader, R. Aguilar, P. Sharma et al., "In-hospital mortality in cirrhotic patients with end-stage renal disease treated with hemodialysis versus peritoneal dialysis: a nationwide study," *Peritoneal Dialysis International*, vol. 37, no. 4, pp. 464–471, 2017.
- [11] A. Khalifeh, R. Autorino, R. Eyraud et al., "Three-year oncologic and renal functional outcomes after robot-assisted partial nephrectomy," *European Urology*, vol. 64, no. 5, pp. 744–750, 2013.
- [12] K. Kobayashi, T. Kitamura, S. Kohira et al., "Cerebral oximetry for cardiac surgery: a preoperative comparison of device characteristics and pitfalls in interpretation," *Journal of Artificial Organs*, vol. 21, no. 4, pp. 412–418, 2018.
- [13] I. E. Hall, M. D. Doshi, E. D. Poggio, and C. R. Parikh, "A comparison of alternative serum biomarkers with creatinine for predicting allograft function after kidney transplantation," *Transplantation*, vol. 91, no. 1, pp. 48–56, 2011.
- [14] N. D. Eneanya, S. L. Goff, T. Martinez et al., "Shared decision-making in end-stage renal disease: a protocol for a multi-center study of a communication intervention to improve end-of-life care for dialysis patients," *BMC Palliative Care*, vol. 14, no. 1, p. 30, 2015.
- [15] U. Nyman, T. Almén, P. Aspelin, M. Hellström, M. Kristiansson, and G. Sterner, "Contrast-medium-induced nephropathy correlated to the ratio between dose in gram iodine and estimated GFR in ml/min," *Acta Radiologica*, vol. 46, no. 8, pp. 830–842, 2005.
- [16] A. Mella, M. Messina, A. Raghino et al., "Pulmonary toxicity in a renal transplant recipient treated with amiodarone and everolimus: a case of hypothetical synergy and a proposal for a screening protocol," *Case Reports in Nephrology and Urology*, vol. 4, no. 1, pp. 75–81, 2014.
- [17] M. Messina, W. Morale, and A. Vighianesi, "Atypical placement of hemodialysis catheters in patients with complete and irreversible obstruction of central venous vessels," *The Journal of Vascular Access*, vol. 12, no. 1, pp. 21–27, 2011.
- [18] A. J. Peixoto and S. F. Santos, "Blood pressure management in hemodialysis: what have we learned?," *Current Opinion in Nephrology and Hypertension*, vol. 19, no. 6, pp. 561–566, 2010.
- [19] S. Hollander, H. Mojibian, M. Emery, and M. G. Tal, "Power injection of iodinated intravenous contrast material through acute and chronic hemodialysis catheters," *The Journal of Vascular Access*, vol. 13, no. 1, pp. 61–64, 2012.
- [20] S. Sahathevan, B. H. Khor, C. H. Yeong et al., "Validity of ultrasound imaging in measuring quadriceps muscle thickness and cross-sectional area in patients receiving maintenance hemodialysis," *Journal of Parenteral and Enteral Nutrition*, vol. 45, no. 2, pp. 422–426, 2021.
- [21] T. Mueller, A. Gegenhuber, G. Kronabethleitner, I. Leitner, M. Haltmayer, and B. Dieplinger, "Plasma concentrations of novel cardiac biomarkers before and after hemodialysis session," *Clinical Biochemistry*, vol. 48, no. 16-17, pp. 1163–1166, 2015.
- [22] P. Xie, K. Peng, K. Zhang et al., "Anatomy revisited: hemodialysis catheter malposition into the chest," *Blood Purification*, vol. 47, no. 1-3, pp. 58–61, 2019.
- [23] M. B. Pisano, J. Leathers, D. C. Balderramo et al., "Hepatitis E virus infection in hemodialysis patients: a prospective analysis," *In Seminars in Dialysis*, vol. 31, no. 5, pp. 528–529, 2018.
- [24] A. R. McGuire, M. E. DeJoseph, and J. R. Gill, "An approach to iatrogenic deaths," *Forensic Science, Medicine and Pathology*, vol. 12, no. 1, pp. 68–80, 2016.
- [25] M. A. Mekawy, D. M. Habashy, and W. A. Abd El-Mohsen, "Effect of hemodialysis on platelet function in end-stage renal disease Egyptian patients using in vitro closure time test (PFA-100 analyzer)," *Platelets*, vol. 26, no. 5, pp. 443–447, 2015.
- [26] I. J. Arhuidese, J. Wanogho, M. Faateh, E. A. Aji, D. A. Rideout, and M. B. Malas, "Hemodialysis and peritoneal dialysis access related outcomes in the pediatric and adolescent population," *Journal of Pediatric Surgery*, vol. 55, no. 7, pp. 1392–1399, 2020.
- [27] S. Lang, P. Hoelter, and M. Schmidt, "Evaluation of an artificial intelligence-based 3D-angiography for visualization of cerebral vasculature," *Clinical Neuroradiology*, vol. 30, no. 4, pp. 705–712, 2020.