

Research Article

Detection of *Mycobacterium avium* ss. *Paratuberculosis* in Blau Syndrome Tissues

C. Thomas Dow^{1,2} and Jay L. E. Ellingson³

¹Department of Ophthalmology and Visual Sciences, University of Wisconsin, Madison, 600 Highland Avenue, Madison, WI 53792, USA

²Chippewa Valley Eye Clinic, 2715 Damon Street, Eau Claire, WI 54701, USA

³Kwik Trip Inc., 2302 Kwik Trip Way, La Crosse, WI 54602, USA

Correspondence should be addressed to C. Thomas Dow, ctd@discover-net.net

Received 2 January 2010; Revised 1 May 2010; Accepted 11 May 2010

Academic Editor: Edmond J. Yunis

Copyright © 2010 C. T. Dow and J. L. E. Ellingson. This is an open access article distributed under the Creative Commons Attribution License, which permits unrestricted use, distribution, and reproduction in any medium, provided the original work is properly cited.

Background and Aim of the Work. Blau syndrome is an inherited granulomatous inflammatory disorder with clinical findings of uveitis, arthritis, and dermatitis. Although rare, Blau syndrome shares features with the more common diseases sarcoidosis and Crohn's disease. The clinical findings of Blau syndrome are indistinguishable from juvenile sarcoidosis; the mutations of Blau syndrome are on the same gene of chromosome 16 (CARD15) that confers susceptibility to Crohn's disease. The product of this gene is part of the innate immune system. *Mycobacterium avium* ss. *paratuberculosis* (MAP) is the putative cause of Crohn's disease and has been implicated as a causative agent of sarcoidosis. **Methods.** Archival tissues of individuals with Blau syndrome were tested for the presence of MAP. **Results.** DNA evidence of MAP was detected in all of the tissues. **Conclusions.** This article finds that MAP is present in Blau syndrome tissue and postulates that it has a causal role. The presence of MAP in Blau syndrome—an autosomal dominant, systemic inflammatory disease—connects genetic and environmental aspects of “autoimmune” disease.

1. Introduction

Blau syndrome is familial juvenile systemic granulomatosis [1]. Although rare, Blau syndrome has been of interest in current medical literature because of the discovery that places its genetic defect on the same gene as one of the susceptibility genes for Crohn's disease [2, 3]. Linkage studies have placed the gene on chromosome 16; originally referred to as the NOD2 gene, it is now known as the CARD15 gene [4]. The Blau syndrome susceptibility component of the CARD15 gene is at the nucleotide binding site domain [2, 5] while the Crohn's susceptibility is at the N-terminal leucine-rich repeat domain [4, 6]. In addition to Crohn's disease and Blau syndrome, mutations of the CARD15 gene have been linked to psoriatic arthritis [7]. The CARD15 gene is part of the ancestral innate immune system that senses and eliminates bacteria [8, 9], and is part of the newly recognized, larger CATERPILLER gene family which acts as sensors to detect pathogens which regulates inflammatory

and apoptotic responses [10]. Blau syndrome is unique in that it is the only systemic granulomatous disease that has a recognized Mendelian pattern of inheritance: autosomal dominant [11]. The landmark progress associating this gene with systemic granulomatous disease has prompted studies of other granulomatous disease to look for a similar defect [3, 12]. While CARD15 defects confer susceptibility Crohn's disease, Blau syndrome, and psoriatic arthritis [7] no such defects were found in patients with sarcoidosis [13], ankylosing spondylitis [14] Wegener's granulomatosis [15], systemic lupus erythematosus [16], or rheumatoid arthritis [17].

Mycobacterium avium ss. *paratuberculosis* (MAP) is an obligate intracellular organism that causes an enteric granulomatous disease in ruminant animals, Johne's disease [18, 19]. MAP is the putative cause of Crohn's disease, a similar enteric granulomatous disease of humans [20–24].

Traditional methods of detecting bacteria, culture, and stain, are largely ineffective in detecting MAP in humans.

TABLE 1: Results of DNA probing for IS900 and hspX of *Mycobacterium avium* ss. *paratuberculosis* (MAP) in Blau Syndrome tissues.

Source	Rose [36]		DeChadarevian [37]		Ziegler [38]	
Patient	Mother Child		Both tissues from same patient		Mother Child	
Tissue	Liver	Synovium	Synovium	Skin	Kidney	Skin
IS900	+	+	+	+	+	+
hspX		+	+		+	
Gel Lanes	2,3,4	5	6	7	8,9,10	11

The bacteria are very difficult to culture and MAP is able to exist in a spheroplast (cell wall deficient) form in humans [25–27]. The advent of bacterial DNA detection with polymerase chain reaction (PCR) has greatly aided the detection of mycobacteria [28, 29]. In one series, the DNA of MAP was identified in greater than 90% of biopsy specimens from individuals with Crohn’s disease [30]. Viable MAP has been recovered from the blood of patients with Crohn’s disease [31]. Yet, the difficulty in culturing MAP from the blood of individuals with Crohn’s is evident in a recent paper by Parrish [32] in which no samples grew MAP and, in another recent paper successful recovery of MAP was achieved in split samples [33]. In addition to Crohn’s disease, MAP is also implicated in sarcoidosis [34]. Because of the association of Blau syndrome with the gene conferring susceptibility to Crohn’s disease and because clinical findings of Blau syndrome are evocative of juvenile sarcoidosis, we postulated that MAP might play a role in Blau syndrome. Tissues were tested for MAP with DNA probes for IS900 and hspX. IS900 is a multicopy genetic element and is a standard probe for MAP, and hspX is very specific as it probes for a single gene specific to MAP [35].

2. Materials and Methods

Several clinicians who had published articles that included Blau syndrome granulomas were contacted and solicited to send representative samples for DNA probing for MAP. Three authors sent tissues: paraffin blocks of Blau skin, synovium and liver granulomas [36, 37], and unstained slides of Blau skin and renal granulomas [38]. Six different tissues from five patients representing three kindred were received and subjected to DNA probe for MAP. IS900 is the most commonly recognized DNA sequence associated with MAP and has multiple copies within the genome [18, 39]. An additional element has been found, hspX; this marker is more specific for MAP as there is only one copy within the MAP genome [35].

Tissues mounted on slides were prepared as follows: each tissue section was scraped from the glass slide into a sterile microcentrifuge tube using a sterile scalpel. Sections of the same tissue from different slides were pooled. Patient tissues embedded in paraffin were prepared as follows: blocks were effaced until complete tissue sections were obtained, then five, 5-micron sections of each paraffin-embedded tissue was cut and placed into a sterile microcentrifuge tube. Tris-EDTA (TE) buffer (100 μ L; pH 7.5) was then added to each tissue

sample and vortexed for 1 minute. The tubes containing samples were then placed into a boiling water bath for 10 minutes and then immediately vortexed for 2 minutes. The 10-minute boiling step followed by 2 minutes of vortexing was repeated twice (a total of 3 times). Tubes were boiled for an additional 5 minutes, cooled to room temperature and then centrifuged at 10,000 rpm’s for 10 minutes. DNA was extracted from 100 μ L of the supernatant using the Magna Pure LC DNA Isolation Kit III (Roche Diagnostics Corporation, Indianapolis, IN) according to the manufacturer’s instructions. DNA was amplified according to the parameters described by Miller et al. (1999). Amplified PCR reactions were analyzed by agarose gel electrophoresis (1.5% agarose gel). All products were compared to a standard molecular weight ladder and the positive control to determine amplicon size. A sample was considered positive if amplified product was noted at 229 bp for the IS900 primer set and 211 bp with the hspX primer set. (Testing was performed by the Food Services Laboratory at the Marshfield Clinic, Marshfield, Wisconsin.) Polymerase chain reaction (PCR) [40].

3. Results

The tested tissues represented six archival samples of Blau syndrome pathologic specimens. They were from five different patients and represented three different kindred. All tissues tested positive for IS900. Three tissues tested positive for the hspX. (Table 1 and Figure 1).

4. Discussion

In addition to the historic interest of MAP in Crohn’s and sarcoidosis, there is recent interest in MAP as an immune trigger of several autoimmune diseases [41–43]. Increasing evidence suggests a role for MAP in autoimmune (Type 1) diabetes. It is postulated that MAP acts via molecular mimicry between genetic elements of MAP (HSP65) and the pancreatic enzyme glutamic acid decarboxylase (GAD) [44–48]. The presence of MAP DNA in Blau syndrome tissues was postulated because of the genetic connection to Crohn’s disease and because of its clinical similarities to sarcoidosis—both diseases associated with MAP. Recent studies have demonstrated that sporadic cases of “juvenile sarcoidosis” are instead *de novo* CARD15 defects associated with Blau syndrome [49, 50]. This article postulates the CARD15 defect associated with Blau syndrome allows for a persistent

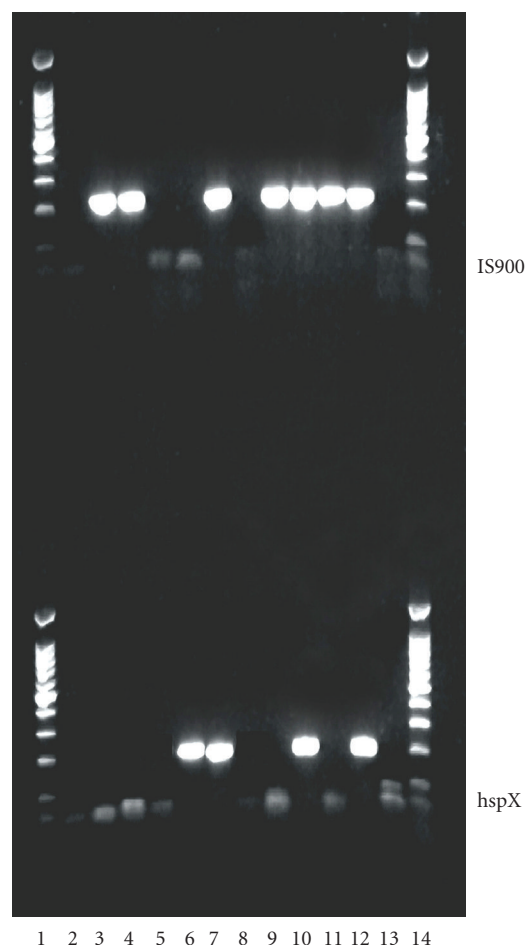


FIGURE 1: *top*—IS900, *bottom*—hspX. LANE 1 100 bp ladder 2–11 See Table 1. 12 Positive control MAP-ATCC 19698 13 Negative control 14 100 bp ladder.

presence of MAP. The presence of MAP in Blau syndrome—an autosomal dominant, systemic, inflammatory disease—connects genetic, and environmental (infectious) aspects of “autoimmune” disease. Larger scale studies of Blau syndrome individuals will need to be completed and include testing for MAP bacteremia to further elucidate the roll of this intriguing pathogen.

Acknowledgments

The authors wish to thank the collaborating physicians, Drs. Rose, Zeigler, and deChadarevian who kindly shared tissues from their previously published cases. The authors also thank Dr. J. Hermon-Taylor, London, for his encouragement.

References

- [1] E. B. Blau, “Familial granulomatous arthritis, iritis, and rash,” *Journal of Pediatrics*, vol. 107, no. 5, pp. 689–693, 1985.
- [2] J. Hampe, J. Grebe, and S. Nikolaus et al., “Association of NOD2 (CARD 15) genotype with clinical course of Crohn’s disease: a cohort study,” *Lancet*, vol. 359, no. 9318, pp. 1661–1665, 2002.
- [3] C. Miceli-Richard, S. Lesage, and M. Rybojad et al., “CARD15 mutations in Blau syndrome,” *Nature Genetics*, vol. 29, no. 1, pp. 19–20, 2001.
- [4] J.-P. Hugot, M. Chamaillard, and H. Zouali et al., “Association of NOD2 leucine-rich repeat variants with susceptibility to Crohn’s disease,” *Nature*, vol. 411, no. 6837, pp. 599–603, 2001.
- [5] X. Wang, H. Kuivaniemi, and G. Bonavita et al., “CARD15 mutations in familial granulomatosis syndromes: a study of the original Blau syndrome kindred and other families with large-vessel arteritis and cranial neuropathy,” *Arthritis and Rheumatism*, vol. 46, no. 11, pp. 3041–3045, 2002.
- [6] S. Lesage, H. Zouali, and J.-P. Cézard et al., “CARD15/NOD2 mutational analysis and genotype-phenotype correlation in 612 patients with inflammatory bowel disease,” *American Journal of Human Genetics*, vol. 70, no. 4, pp. 845–857, 2002.
- [7] P. Rahman, S. Bartlett, and F. Siannis et al., “CARD15: a pleiotropic autoimmune gene that confers susceptibility to psoriatic arthritis,” *American Journal of Human Genetics*, vol. 73, no. 3, pp. 677–681, 2003.
- [8] N. Inohara, Y. Ogura, and A. Fontalba et al., “Host recognition of bacterial muramyl dipeptide mediated through NOD2: implications for Crohn’s disease,” *Journal of Biological Chemistry*, vol. 278, no. 8, pp. 5509–5512, 2003.
- [9] S. E. Girardin, J.-P. Hugot, and P. J. Sansonetti, “Lessons from Nod2 studies: towards a link between Crohn’s disease and bacterial sensing,” *Trends in Immunology*, vol. 24, no. 12, pp. 652–658, 2003.
- [10] J. P.-Y. Ting and B. K. Davis, “CATERPILLER: a novel gene family important in immunity, cell death, and diseases,” *Annual Review of Immunology*, vol. 23, pp. 387–414, 2005.
- [11] G. Tromp, H. Kuivaniemi, and S. Raphael et al., “Genetic linkage of familial granulomatous inflammatory arthritis, skin rash, and uveitis to chromosome 16,” *American Journal of Human Genetics*, vol. 59, no. 5, pp. 1097–1107, 1996.
- [12] Y. Ogura, D. K. Bonen, and N. Inohara et al., “A frameshift mutation in NOD2 associated with susceptibility to Crohn’s disease,” *Nature*, vol. 411, no. 6837, pp. 603–606, 2001.
- [13] T. M. Martin, T. M. Doyle, J. R. Smith, D. Dinulescu, K. Rust, and J. T. Rosenbaum, “Uveitis in patients with sarcoidosis is not associated with mutations in NOD2 (CARD15),” *American Journal of Ophthalmology*, vol. 136, no. 5, pp. 933–935, 2003.
- [14] M. van der Paardt, J. B. A. Crusius, and M. H. M. T. de Koning et al., “CARD15 gene mutations are not associated with ankylosing spondylitis,” *Genes and Immunity*, vol. 4, no. 1, pp. 77–78, 2003.
- [15] B. Newman, L. A. Rubin, and K. A. Siminovitch, “NOD2/CARD15 gene mutation is not associated with susceptibility to Wegener’s granulomatosis,” *Journal of Rheumatology*, vol. 30, no. 2, pp. 305–307, 2003.
- [16] I. Ferreira-Vidal, J. Garcia-Mejide, and P. Carreira et al., “The three most common CARD15 mutations associated with Crohn’s disease and the chromosome 16 susceptibility locus for systemic lupus erythematosus,” *Rheumatology*, vol. 42, no. 4, pp. 570–574, 2003.
- [17] I. Ferreira-Vidal, F. Barros, J. L. Pablos, A. Carracedo, J. J. Gómez-Reino, and A. Gonzalez, “CARD15/NOD2 analysis in rheumatoid arthritis susceptibility,” *Rheumatology*, vol. 42, no. 11, pp. 1380–1382, 2003.
- [18] N. B. Harris and R. G. Barletta, “*Mycobacterium avium subsp. paratuberculosis* in veterinary medicine,” *Clinical Microbiology Reviews*, vol. 14, no. 3, pp. 489–512, 2001.

- [19] M. T. Collins, D. C. Sockett, W. J. Goodger, T. A. Conrad, C. B. Thomas, and D. J. Carr, "Herd prevalence and geographic distribution of, and risk factors for, bovine paratuberculosis in Wisconsin," *Journal of the American Veterinary Medical Association*, vol. 204, no. 4, pp. 636–641, 1994.
- [20] J. Hermon-Taylor, "Mycobacterium avium subspecies paratuberculosis in the causation of Crohn's disease," *World Journal of Gastroenterology*, vol. 6, no. 5, pp. 630–632, 2000.
- [21] R. J. Greenstein, "Is Crohn's disease caused by a mycobacterium? Comparisons with leprosy, tuberculosis, and Johne's disease," *Lancet Infectious Diseases*, vol. 3, no. 8, pp. 507–514, 2003.
- [22] I. Abubakar, D. Myhill, S. H. Aliyu, and P. R. Hunter, "Detection of Mycobacterium avium subspecies paratuberculosis from patients with Crohn's disease using nucleic acid-based techniques: a systematic review and meta-analysis," *Inflammatory Bowel Diseases*, vol. 14, no. 3, pp. 401–410, 2008.
- [23] Y. Ogura, S. Lala, and W. Xin et al., "Expression of NOD2 in Paneth cells: a possible link to Crohn's ileitis," *Gut*, vol. 52, no. 11, pp. 1591–1597, 2003.
- [24] H.-P. Török, J. Glas, P. Lohse, and C. Folwaczny, "Alterations of the CARD15/NOD2 gene and the impact on management and treatment of Crohn's disease patients," *Digestive Diseases*, vol. 21, no. 4, pp. 339–345, 2003.
- [25] L. A. Sechi, M. Mura, F. Tanda, A. Lissia, G. Fadda, and S. Zanetti, "Mycobacterium avium sub. paratuberculosis in tissue samples of Crohn's disease patients," *New Microbiologica*, vol. 27, no. 1, pp. 75–77, 2004.
- [26] S. Wall, Z. M. Kunze, and S. Saboor et al., "Identification of spheroplast-like agents isolated from tissues of patients with Crohn's disease and control tissues by polymerase chain reaction," *Journal of Clinical Microbiology*, vol. 31, no. 5, pp. 1241–1245, 1993.
- [27] M. E. Hines II and E. L. Styer, "Preliminary characterization of chemically generated Mycobacterium avium subsp. paratuberculosis cell wall deficient forms (spheroplasts)," *Veterinary Microbiology*, vol. 95, no. 4, pp. 247–258, 2003.
- [28] J. Lachnik, B. Ackermann, and A. Bohrsen et al., "Rapid-cycle PCR and fluorimetry for detection of mycobacteria," *Journal of Clinical Microbiology*, vol. 40, no. 9, pp. 3364–3373, 2002.
- [29] J. O'Mahony and C. Hill, "A real time PCR assay for the detection and quantitation of Mycobacterium avium subsp. paratuberculosis using SYBR Green and the Light Cycler," *Journal of Microbiological Methods*, vol. 51, no. 3, pp. 283–293, 2002.
- [30] T. J. Bull, E. J. McMin, and K. Sidi-Boumedine et al., "Detection and verification of Mycobacterium avium subsp. paratuberculosis in fresh ileocolonic mucosal biopsy specimens from individuals with and without Crohn's disease," *Journal of Clinical Microbiology*, vol. 41, no. 7, pp. 2915–2923, 2003.
- [31] S. A. Naser, G. Ghobrial, C. Romero, and J. F. Valentine, "Culture of Mycobacterium avium subspecies paratuberculosis from the blood of patients with Crohn's disease," *Lancet*, vol. 364, no. 9439, pp. 1039–1044, 2004.
- [32] N. M. Parrish, R. P. Radcliff, and B. J. Brey et al., "Absence of Mycobacterium avium subsp. paratuberculosis in Crohn's patients," *Inflammatory Bowel Diseases*, vol. 15, no. 4, pp. 558–565, 2009.
- [33] S. A. Naser, M. T. Collins, J. T. Crawford, and J. F. Valentine, "Culture of Mycobacterium avium subspecies paratuberculosis (MAP) from the blood of patients with Crohn's disease: a follow-up blind multi center investigation," *The Open Inflammation Journal*, no. 2, pp. 22–23, 2009.
- [34] F. A. K. el-Zaatari, S. A. Naser, D. C. Markesich, D. C. Kalter, L. Engstand, and D. Y. Graham, "Identification of Mycobacterium avium complex in sarcoidosis," *Journal of Clinical Microbiology*, vol. 34, no. 9, pp. 2240–2245, 1996.
- [35] J. L. E. Ellingson, C. A. Bolin, and J. R. Stabel, "Identification of a gene unique to Mycobacterium avium subspecies paratuberculosis and application to diagnosis of paratuberculosis," *Molecular and Cellular Probes*, vol. 12, no. 3, pp. 133–142, 1998.
- [36] J.-P. De Chadarevian, S. A. Raphael, and G. F. Murphy, "Histologic, ultrastructural, and immunocytochemical features of the granulomas seen in a child with the syndrome of familial granulomatous arthritis, uveitis, and rash," *Archives of Pathology and Laboratory Medicine*, vol. 117, no. 10, pp. 1050–1052, 1993.
- [37] S. K. Saini and C. D. Rose, "Liver involvement in familial granulomatous arthritis (Blau syndrome)," *Journal of Rheumatology*, vol. 23, no. 2, pp. 396–399, 1996.
- [38] S. S. Ting, J. Ziegler, and E. Fischer, "Familial granulomatous arthritis (Blau syndrome) with granulomatous renal lesions," *Journal of Pediatrics*, vol. 133, no. 3, pp. 450–452, 1998.
- [39] E. P. Green, M. L. V. Tizard, and M. T. Moss et al., "Sequence and characteristics of IS900, an insertion element identified in a human Crohn's disease isolate of Mycobacterium paratuberculosis," *Nucleic Acids Research*, vol. 17, no. 22, pp. 9063–9073, 1989.
- [40] J. M. Miller, A. L. Jenny, and J. L. Ellingson, "Polymerase chain reaction identification of Mycobacterium avium in formalin-fixed, paraffin-embedded animal tissues," *Journal of Veterinary Diagnostic Investigation*, vol. 11, no. 5, pp. 436–440, 1999.
- [41] C. T. Dow, "Paratuberculosis and type I diabetes Is this the trigger?" *Medical Hypotheses*, vol. 67, no. 4, pp. 782–785, 2006.
- [42] C. T. Dow, "Cows, Crohn's and more: is Mycobacterium paratuberculosis a superantigen?" *Medical Hypotheses*, vol. 71, no. 6, pp. 858–861, 2008.
- [43] M. D'Amore, S. Lisi, M. Sisto, L. Cucci, and C. T. Dow, "Molecular identification of Mycobacterium avium subspecies paratuberculosis in an Italian patient with Hashimoto's thyroiditis and Melkersson-Rosenthal syndrome," *Journal of Medical Microbiology*, vol. 59, no. 1, pp. 137–139, 2010.
- [44] L. A. Sechi, V. Rosu, A. Pacifico, et al., "Humoral immune responses of type 1 diabetes patients to M. avium subspecies paratuberculosis lend support to the infectious trigger hypothesis," *Clinical and Vaccine Immunology*. In press.
- [45] L. A. Sechi, D. Paccagnini, S. Salza, A. Pacifico, N. Ahmed, and S. Zanetti, "Mycobacterium avium subspecies paratuberculosis bacteremia in type 1 diabetes mellitus: an infectious trigger?" *Clinical Infectious Diseases*, vol. 46, no. 1, pp. 148–149, 2008.
- [46] V. Rosu, N. Ahmed, D. Paccagnini, A. Pacifico, S. Zanetti, and L. A. Sechi, "Mycobacterium avium subspecies paratuberculosis is not associated with type-2 diabetes mellitus," *Annals of Clinical Microbiology and Antimicrobials*, vol. 7, article 9, 2008.
- [47] V. Rosu, N. Ahmed, and D. Paccagnini et al., "Specific immunoassays confirm association of Mycobacterium avium subsp. paratuberculosis with type-1 but not type-2 diabetes mellitus," *PLoS ONE*, vol. 4, no. 2, article e4386, 2009.
- [48] D. Paccagnini, L. Sieswerda, and V. Rosu et al., "Linking chronic infection and autoimmune diseases: Mycobacterium avium subspecies paratuberculosis, SLC11A1 polymorphisms and type-1 diabetes mellitus," *PLoS ONE*, vol. 4, no. 9, article e7109, 2009.

- [49] C. D. Rosé, T. M. Doyle, and G. McIlvain-Simpson et al., “Blau syndrome mutation of CARD15/NOD2 in sporadic early onset granulomatous arthritis,” *Journal of Rheumatology*, vol. 32, no. 2, pp. 373–375, 2005.
- [50] N. Kanazawa, I. Okafuji, and N. Kambe et al., “Early-onset sarcoidosis and CARD15 mutations with constitutive nuclear factor- κ B activation: common genetic etiology with Blau syndrome,” *Blood*, vol. 105, no. 3, pp. 1195–1197, 2005.

