

Research Article

Combined Endovascular and Surgical Treatment of Chronic Carotid Artery Occlusion: Hybrid Operation

Long Yan ¹, Zhe Wang ², Zhanchuan Liu ³, Haoyuan Yin ⁴, and Xuan Chen ⁴

¹Department of Interventional Neuroradiology, Beijing Tiantan Hospital, Capital Medical University, Beijing 100000, China

²Department of Gerontology, The First Hospital of Jilin University, Changchun, Jilin 130021, China

³Department of Neurosurgery, The Second Hospital of Jilin University, Changchun, Jilin 130041, China

⁴Department of Neurosurgery, The First Hospital of Jilin University, Changchun, Jilin 130021, China

Correspondence should be addressed to Xuan Chen; chen_xuan@jlu.edu.cn

Received 12 October 2020; Revised 5 November 2020; Accepted 16 November 2020; Published 1 December 2020

Academic Editor: Weiluan Chen

Copyright © 2020 Long Yan et al. This is an open access article distributed under the Creative Commons Attribution License, which permits unrestricted use, distribution, and reproduction in any medium, provided the original work is properly cited.

Objectives. The optimal treatment choice of chronic carotid artery occlusion (CAO) remains inconclusive. This study was aimed at exploring the safety and effectiveness of hybrid surgery in the treatment of CAO and at determining predictors for successful recanalization. **Methods.** In this study, we enrolled 37 patients with CAO who underwent hybrid surgical treatment during the period 2016–2018. We extracted and analyzed patients' demographic data, disease characteristics, surgical success rates, perioperative complications, and prognosis. **Results.** A total of 37 patients with symptomatic CAO underwent hybrid surgical treatment. Thirty cases (81.1%) were successfully recanalized, while seven were not. Blood reflux after carotid endarterectomy occurred in 18 patients (60%) of the success group and 1 (14.3%) of the failure group (OR, 9.0; 95% CI, 0.95–54.5; $P = 0.042$). The rate of distal ICA reconstruction below the clinoid segment was 20 (66.7%) in the success group and 1 (14.3%) in the failure group (OR, 12.0; 95% CI, 1.3–113.7; $P = 0.029$). In patients with successful recanalization, no ischemic events occurred after surgery and during follow-up, but restenosis of >50% was found in one case. In the failure group, two patients experienced recurrent ischemic events during follow-up. Perfusion imaging in successful recanalization cases is significantly improved, preoperative I/C ratio was 1.44 (IQR 1.27–1.55), and postoperative 1.12 (IQR 1.05–1.23). National Institutes of Health Stroke Scale (NIHSS) score of successful recanalization cases was 5.35 (2.26) before surgery and 2.03 (1.40) at 6 months ($P < 0.01$). **Conclusion.** Hybrid surgery might be a safe and effective way to treat CAO. Distal internal carotid artery reconstruction to below the clinoid segment and blood reflux after carotid endarterectomy are predictors of successful recanalization.

1. Introduction

Chronic carotid artery occlusion (CAO) is an uncommon but important cause of ischemic stroke. The natural course of CAO varies greatly, and it can manifest as stroke, transient ischemic attack (TIA), or no symptoms at all. Territories of which blood supply is occluded rely on compensating collateral flow, but for some patients, these are not sufficient. Among patients with hemodynamic disorders, those with CAO have significantly higher rates of recurrent stroke and mortality [1]. Treatment of CAO is still controversial. Alternative treatments are as follows: conservative treatment includ-

ing antiplatelets and anticoagulants, extracranial-intracranial (EC-IC) bypass, carotid endarterectomy (CEA), and endovascular recanalization.

Hybrid surgery refers to the combination of endovascular recanalization and CEA. Reaching the distal true lumen through the occluded segment is the key to successful recanalization in CAO. Hybrid surgery combines their advantages and overcomes their respective difficulties. CEA removes plaque, allowing the microcatheter and microguidewire to easily pass through to the distal true lumen. Some studies have reported the application of hybrid surgery in CAO [2–4], but the predictors of successful recanalization have not been

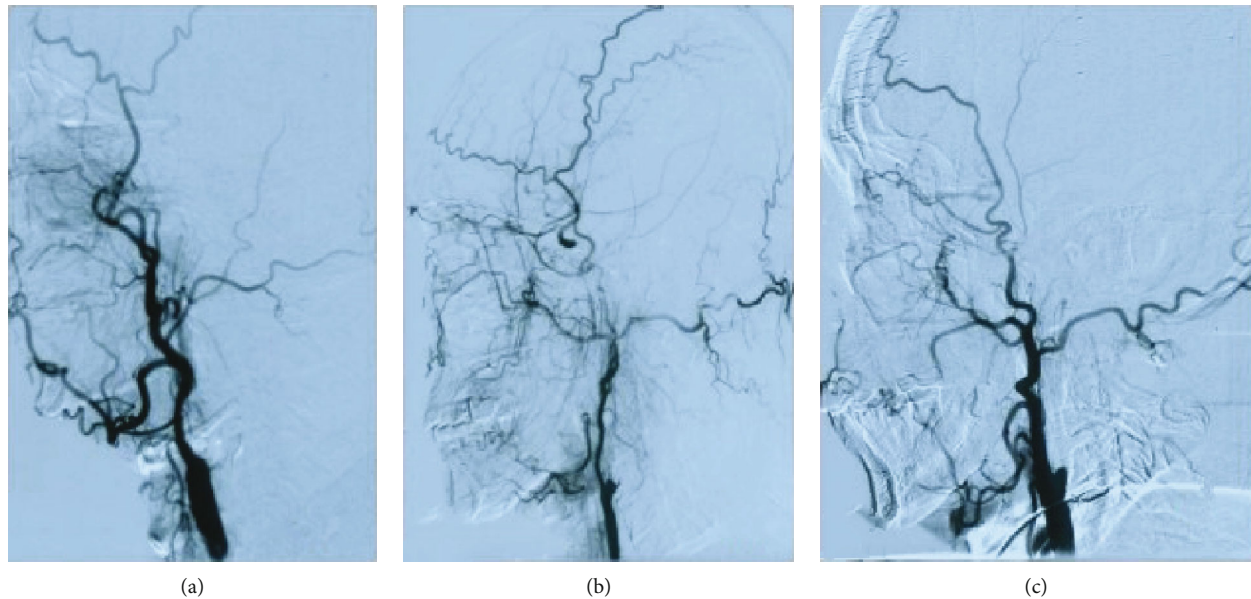


FIGURE 1: Stump condition: (a) no stump; (b) blunt stump; (c) tapered stump.

fully discussed. The purposes of the study are to explore the effectiveness and safety of hybrid surgery for CAO and the predictors of successful recanalization.

2. Materials and Methods

2.1. Patient Selection. This retrospective study was approved by the local institutional review board. We included symptomatic CAO patients who were hospitalized in the Department of Neurosurgery of the First Hospital of Jilin University (Changchun, China) from January 2016 to December 2018. CAO was defined as a duration of ≥ 4 weeks between diagnosis and treatment. Inclusion criteria were as follows: (1) 18–80 years old, (2) complete carotid artery occlusion as confirmed by digital-subtraction angiography (DSA), (3) TIA or stroke occurring in the occluded blood vessel supply area over the past 12 months, (4) computed tomography (CT) or magnetic resonance (MR) perfusion imaging confirming hypoperfusion on the occluded side, (5) CT or MR excluding extensive cerebral infarction, and (6) cases with complete clinical and imaging data to permit follow-up. Exclusion criteria were as follows: (1) severe diseases of the heart, liver, kidney, lung, or other vital organ, with estimated survival time < 3 months; (2) inability to tolerate general anesthesia for surgery; (3) allergy to contrast agents; (4) contraindication of, or resistance to, aspirin and/or clopidogrel; (5) other cerebrovascular diseases (intracranial aneurysms and cerebrovascular malformations) causing stroke; and (6) severe neurological dysfunction and impaired consciousness.

2.2. Data Collection. Baseline information included sex, age, diabetes, hypertension, smoking, drinking, and hyperlipidemia. NIHSS score on admission and duration from the last neurologic event to surgery was also collected. All imaging data are assessed individually by two neurosurgeons. All patients underwent CT perfusion imaging or MR perfusion imaging before and one week after surgery. Mean transit

times (MTTs) of ipsilateral- (side of the occluded ICA-) to-contralateral (I/C) were calculated. The morphological description included the following: stump morphology: (1) blunt stump or no stump and (2) tapered stump (Figure 1). Compensatory vessels included the following: anterior communicating artery, posterior communicating artery, ipsilateral ophthalmic artery, and branches of other arteries. Reflux sites were categorized as follows: (1) below the clinoid segment (cavernous segment, petrous segment, and below) and (2) clinoid segment and above (clinoid segment, ophthalmic segment, or communicating segment). Surgical complications included hyperperfusion, ischemic events, hemorrhage events, carotid cavernous fistula, dissection, and so on.

2.3. Hybrid Surgical Procedure. After general anesthesia, patients were placed in the supine position with their heads tilted to the opposite side from the lesion. A straight incision was made at the front edge of the sternocleidomastoid muscle on the affected side to cut through the skin and platysma muscle after routine disinfection. We separated the skin and muscle along the front edge of the sternocleidomastoid muscle to the ICA sheath so that we could expose and cut the fascia of the ICA in order to lift that artery. The superior thyroid artery, external carotid artery, and distal end of the ICA were clamped in turn. Afterwards, we cut the common carotid artery (CCA) along the long axis to the distal end of the ICA. After stripping off the intima of the ICA containing the plaque and thrombus and then flushing and thoroughly stripping the lumen, we observed the distal end for blood reflux. After stitching up the vessel wall, an 8F catheter sheath was inserted into the right femoral artery to support the catheter to the bifurcation of the CCA. Via angiography, we observed the recanalization status of the distal blood vessels. If it remained occluded, we passed a microcatheter and microguidewire through to the occluded lumen in order to determine stenotic and occluded sites. Then, balloon-angioplasty was used to expand the blood vessel at the site

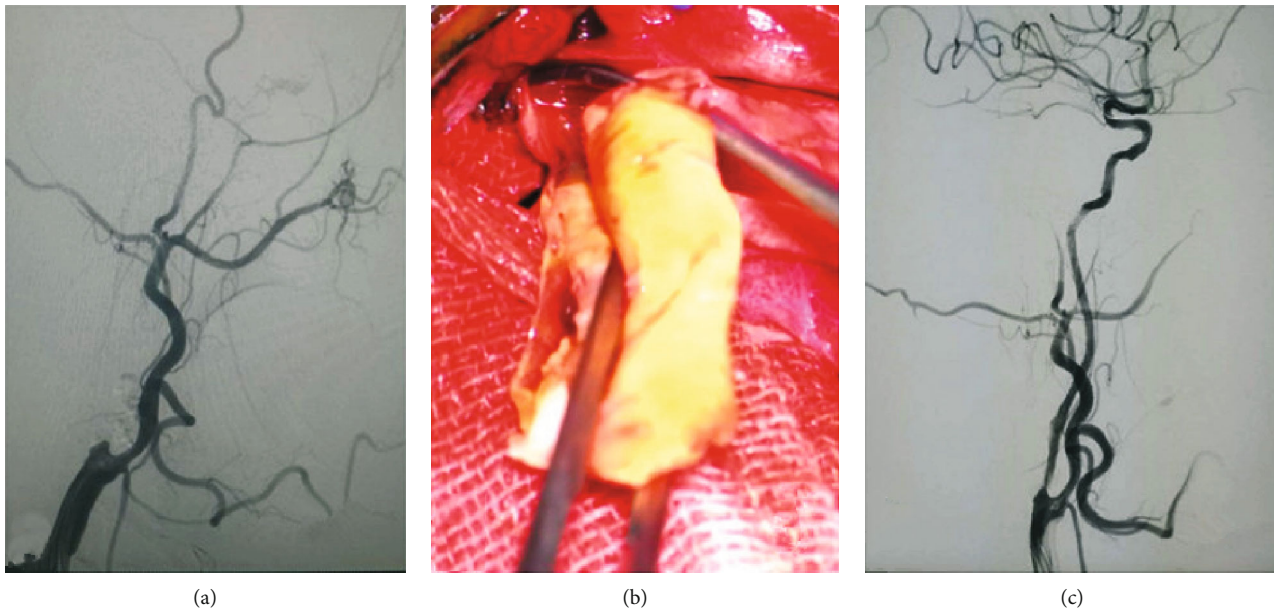


FIGURE 2: (a) Preoperative chronic carotid artery occlusion. (b) Remove carotid plaque. (c) Carotid artery recanalization after hybrid surgery.

of occlusion and stenosis, followed by insertion and release of the appropriate stent. A postsurgery blood flow reaching Thrombolysis in Cerebral Infarction (TICI) grade IIb or higher is defined as successful recanalization (Figure 2).

2.4. Follow-Up. All patients were recommended for follow-up. Clinical follow-up content is as follows: all cases are recommended for outpatient or telephone follow-up and we record the patients' NIHSS score and record hemorrhage and ischemic events. Image follow-up content is as follows: color Doppler ultrasound at 1 month, CTA at 3 months, and DSA at 6 months to record whether the recanalized blood vessel is unobstructed, whether there is reocclusion or restenosis, and whether there are other vascular injuries, such as carotid artery dissection and pseudo aneurysm, and carotid cavernous fistula.

2.5. Statistical Analysis. We performed statistical analysis using SPSS software version 20.0 (IBM Corp., Armonk, New York, US). Normal distribution measurement data were expressed as means and standard deviations (SD), while skew distribution data were expressed as the median and interquartile range (IQR). Counting data were expressed in frequencies and percentages. We compared data between each group using Student's *t* test (normal distribution) or the Mann-Whitney *U* test (skewed distribution), the chi-square test, or Fisher's exact test according to the situation. $P < 0.05$ was considered a statistically significant difference.

3. Results and Discussion

3.1. Results. Of the 59 patients with symptomatic CAO who were admitted during the study period, a total of 37 patients were included in the study (Figure 3). Thirty cases (81.1%) were successfully recanalized and seven were not. Age, male sex, hypertension, diabetes, hyperlipidemia, smoking, and

drinking did not differ significantly between the success and failure groups ($P > 0.05$). Male patients accounted for 89.1% of total cases, a significantly higher proportion than that of female patients. The majority of patients smoked (70.3%). Duration from last onset to surgery was 15.0 (IQR 14.0-33.75) days in cases of the success group and 60.0 (IQR 30.0-120.0) in those of the failure group ($P = 0.007$); therefore, disease last onset was longer in the failure group than in the success group (Table 1).

The lesion was on the left side in 18 cases and on the right side in 19. The occlusion was located in the CCA in 4 cases (10.8%), in the beginning of ICA in 27 cases (73.0%), and in other sites in 6 cases (16.2%). Most of the occlusions were located at the beginning of the ICA. Twenty cases had a tapered stump, and the other 17 cases had a blunt or no stump at all. After CEA, 19 cases showed blood reflux, with 18 successful recanalizations and 1 failure. The other 18 cases showed no blood reflux, with 12 successful recanalizations and 6 failures. ($P = 0.042$). In 16 cases of distal ICA reconstruction at the clinoid segment and above, 10 cases were successfully recanalized and 6 cases were not recanalized; 21 cases below the clinoid segment were successfully recanalized in 20 cases and 1 case was not recanalized ($P = 0.029$) (Table 2).

There were 2 cases of intracranial hemorrhage, 1 case died of sudden breathing, cardiac arrest, and cerebral hemorrhage on the second day after operation; 1 case died of intracranial hemorrhage caused by rupture of the blood vessel during operation. Two cases showed hyperperfusion, which was relieved after medication. There were no ischemic events in the success group after surgery or during follow-up, but restenosis of $>50\%$ was found in one case. Of the seven patients with failed recanalization, two had recurrent ischemic events during follow-up (Table 3).

Preoperative I/C ratio in success group cases was 1.44 (IQR 1.27-1.55); 1 week after surgery, the I/C ratio in these cases was 1.12 (IQR 1.05-1.23), $P < 0.01$. Cerebral perfusion

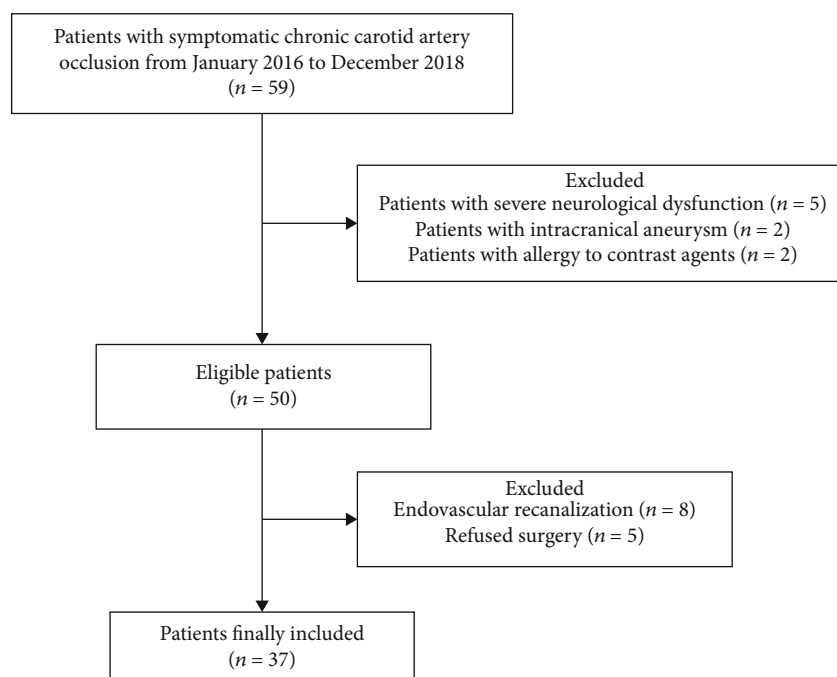


FIGURE 3: Selection of patients.

TABLE 1: Baseline characteristics of patients.

| | Total (n = 37) | Success group (n = 30) | Failure group (n = 7) | P value |
|---|------------------|------------------------|-----------------------|---------|
| Age, mean (SD) | 62.1 (6.4) | 62.9 (6.4) | 58.9 (6.1) | 0.140 |
| Male, n (%) | 33 (89.1%) | 27 (90.0%) | 6 (85.7%) | 1.000 |
| Hypertension, n (%) | 24 (64.9%) | 21 (70.0%) | 3 (42.9%) | 0.213 |
| Diabetes, n (%) | 20 (54.1%) | 16 (53.3%) | 4 (57.1%) | 1.000 |
| Hyperlipidemia, n (%) | 19 (51.4%) | 15 (50.0%) | 4 (57.1%) | 1.000 |
| Smoking, n (%) | 26 (70.3%) | 21 (70.0%) | 5 (71.4%) | 1.000 |
| Drinking, n (%) | 16 (43.2%) | 14 (46.7%) | 2 (28.6%) | 0.674 |
| Duration from last onset to surgery, median (IQR) | 30.0 (14.5-47.5) | 15.0 (14.0-33.75) | 60.0 (30.0-120.0) | 0.007 |

in success group cases was significantly improved. Preoperative NIHSS score in success group cases was 5.35 (2.26); at 6-month follow-up, NIHSS score in these cases was 2.03 (1.40), $P < 0.01$. Neurological function was significantly improved in postoperative patients (Table 4).

3.2. Discussion. Even with intensive drug treatment, the CAO annual stroke recurrence rate is 6% to 20% [1, 5]. It is necessary to establish an alternative treatment with an acceptable safety and efficacy profile. In this study, the recanalization rate of hybrid surgery was 81.1%, with a relatively low risk of complications. We found that distal ICA reconstruction to below the clinoid segment and blood reflux after carotid endarterectomy are predictors of successful recanalization.

Various treatment methods for CAO have developed gradually since the 1960s, including bypass surgery, CEA, and intravascular recanalization under interventional radiology. EC-IC bypass is not recommended due to failing to reduce the risk of recurrent ipsilateral ischemic stroke within 2 years compared with medical therapy [6]. CEA, due to anatomical limitations, is applicable only for occlusion at the ori-

gin of the internal carotid artery (ICA). For long-segment occlusions that extend to the intracranial segment, pure CEA presents challenges to successful recanalization [7]. With the development of neurointerventional technology and materials, endovascular recanalization has been more frequently explored, and more studies have reported the improved possibility of successful endovascular recanalization [8–10]. In one study enrolling 138 patients who underwent endovascular recanalization surgeries, 85 of them (61.6%) were technically successful [11]. However, 6 patients experienced recurrent stroke, death, or intracranial hemorrhage, and 11 (8.0%) had intracranial carotid cavernous fistulae. Thus, the recanalization success rate is still unsatisfactory and the complication rate still high [12].

CEA for the treatment of CAO is limited to occlusion location at places that can be exposed during operation while no long-segment thrombosis exists in the distal blood vessels, which restricts its scope of application. As to endovascular treatment, it was first reported in 2013 for CAO patients [2]; all three patients were successfully recanalized. The cerebral-perfusion imaging showed significant improvement,

TABLE 2: Lesion characteristics of patients.

| | Success group (n = 30) | Failure group (n = 7) | OR (95% CI) | P value |
|------------------------------------|------------------------|-----------------------|------------------|---------|
| Left sided, n (%) | 16 (53.3%) | 2 (28.6%) | 2.9 (0.5-17.1) | 0.405 |
| Occlusion site | | | — | 0.085 |
| CCA, n (%) | 4 (13.3%) | 0 (0.0%) | | |
| Beginning of ICA, n (%) | 23 (76.7%) | 4 (57.1%) | | |
| Other sites, n (%) | 3 (10.0%) | 3 (42.9%) | | |
| Stump condition | | | 0.9 (0.2-4.5) | 1.000 |
| Tapered, n (%) | 16 (53.3%) | 4 (57.1%) | | |
| Blunt or no stump, n (%) | 14 (46.7%) | 3 (42.9%) | | |
| Blood reflux after CEA, n (%) | 18 (60.0%) | 1 (14.3%) | 9.0 (0.95-54.5) | 0.042 |
| Level of distal ICA reconstruction | | | 12.0 (1.3-113.7) | 0.029 |
| Clinoid segment and beyond, n (%) | 10 (33.3%) | 6 (85.7%) | | |
| Below clinoid segment, n (%) | 20 (66.7%) | 1 (14.3%) | | |

CCA: common carotid artery; ICA: internal carotid artery; CEA: carotid endarterectomy.

TABLE 3: Postoperative complications and follow up.

| | Success group (n = 30) | Failure group (n = 7) |
|------------------------|------------------------|-----------------------|
| Hyperperfusion, n (%) | 2 (6.7%) | 0 (0.0%) |
| Ischemic stroke, n (%) | 0 (0.0%) | 2 (28.6%) |
| Hemorrhage, n (%) | 1 (3.3%) | 1 (14.3%) |
| Death, n (%) | 1 (3.3%) | 1 (14.3%) |

TABLE 4: Imaging improvement and functional improvement.

| | Success group | | P |
|-------------------|------------------|------------------|-------|
| | Preoperative | Postoperative | |
| I/C, median (IQR) | 1.44 (1.27-1.55) | 1.12 (1.05-1.23) | <0.01 |
| NIHSS, mean (SD) | 5.35 (2.26) | 2.03 (1.40) | <0.01 |

I/C: mean transit times ipsilateral-to-contralateral; NIHSS: National Institutes of Health Stroke Scale.

and no ischemic events occurred during the 6 months of follow-up. For the past few years, hybrid surgery, combining the CEA and endovascular treatment, has gradually developed to treat CAO. The occlusion site is more likely to locate at the beginning of the ICA for CAO. CEA removes the plaque at the origin ICA, allowing the microcatheter and microguidewire to easily pass through to the distal true lumen. This paves the way for endovascular interventional recanalization, which in turn treats the distal carotid artery lesion using balloons and stents. Theoretically, combining the advantages of the two surgical modalities may improve the success rate. Liu et al. reported [13] that of 21 patients who received hybrid surgical treatment, 15 (71.4%) were successfully recanalized without causing carotid dissections, intracranial hemorrhages, or new neurological deficits. In the current study, we enrolled a total of 37 patients and 30 (81.1%) were successfully recanalized. Therefore, it showed that hybrid surgery may be an effective surgical method for CAO.

Many studies reported the successful recanalization of CAO with hybrid surgery [2-4, 13], but few reported the predictors for successful recanalization. In this study, distal ICA

reconstruction to below the clinoid segment and blood reflux after carotid CEA are predictors of successful recanalization. Both of these predictors indicate a shorter occlusion length. Hybrid surgery makes it possible to reach the distal true lumen through the occluded segment. The occlusion length may be another key factor of successful recanalization. We need more cases and more advanced inspection methods such as high resolution magnetic resonance imaging to verify.

The goal of treatment is to restore blood supply, improve hypoperfusion, and reduce the incidence of recurrent stroke. Studies have shown that hemodynamic damage in patients with CAO is significantly correlated with the incidence of stroke [14, 15]. CT/MR perfusion imaging has in fact been widely used in clinical practice for pre-and postevaluation of CAO cases. A study comparing CT perfusion imaging with positron emission tomography (PET) perfusion imaging in CAO patients showed that MTT parameters of CT perfusion imaging were significantly correlated with oxygen extraction fraction (OEF) as measured by PET [16]. Mukherjee et al. reported [17] that MR perfusion imaging in patients with CAO was linearly correlated with cerebral blood flow (CBF) as measured by PET. Due to the large differences in absolute-value measurement between different modalities, semiquantitative comparisons with the ipsilateral side of the lesion are mostly used at present, and their accuracy has been recognized [18]. All patients in this study underwent CT or MR perfusion before surgery and again 1 week after surgery. Successful cases had a preoperative I/C ratio of 1.44 (IQR 1.27-1.55) and a postoperative ratio I/C of 1.12 (IQR 1.05-1.23), which showed that perfusion was significantly improved before and after surgery.

There were some limitations to this study. First, it was a retrospective study and it is inevitable that the collection of relevant data will be biased; second, the number of cases in this study was small and could not be stratified in more detail based on the level of distal ICA reconstitution. Due to the small sample size, statistical methods used in this study were Student's *t* test (normal distribution) or Mann-Whitney *U* test (skewed distribution), the chi-square test,

or Fisher's exact test; univariate and multivariate analyses could not be performed.

4. Conclusions

Hybrid surgery may be a safe and effective method of treating CAO, with a higher success rate and fewer complications than traditional methods. Distal ICA reconstruction to below the clinoid segment and blood reflux after carotid endarterectomy are predictors of successful recanalization.

Data Availability

The data that support the findings of this study are available from the corresponding author upon reasonable request.

Conflicts of Interest

The authors declare that there is no conflict of interest regarding the publication of this paper.

Acknowledgments

We thank all of the patients and health care providers who participated in this study. We sincerely thank Professor Qi Luo (from the Department of Neurosurgery, the First Hospital of Jilin University, Changchun, Jilin, China) for guidance on the article.

Supplementary Materials

See table in the Supplementary Material for comprehensive data analysis. (*Supplementary Materials*)

References

- [1] M. L. Flaherty, K. D. Flemming, R. McClelland, N. W. Jorgensen, and Brown RD Jr, "Population-based study of symptomatic internal carotid artery occlusion - incidence and long-term follow-up," *Stroke*, vol. 35, no. 8, pp. E349–e352, 2004.
- [2] Y.-T. Shih, W. H. Chen, W. L. Lee, H. T. Lee, C. C. Shen, and Y. S. Tsuei, "Hybrid surgery for symptomatic chronic total occlusion of carotid artery: a technical note," *Neurosurgery*, vol. 73, suppl_1, pp. onsE117–onsE123, 2013.
- [3] Y. Yang, X. Liu, R. Wang, Y. Zhang, D. Zhang, and J. Zhao, "A treatment option for symptomatic chronic complete internal carotid artery occlusion: hybrid surgery," *Frontiers in Neuroscience*, vol. 14, 2020.
- [4] J. Li, C. Wang, S. Zou, Y. Liu, and L. Qu, "Hybrid surgery for nontaper or nonstump lesions in symptomatic subacute or chronic internal carotid occlusion: a better solution," *World Neurosurgery*, vol. 122, pp. E1416–e1425, 2019.
- [5] C. J. M. Klijn, L. J. Kappelle, C. A. F. Tulleken, and J. van Gijn, "Symptomatic carotid artery occlusion," *Stroke*, vol. 28, no. 10, pp. 2084–2093, 1997.
- [6] W. J. Powers, W. R. Clarke, R. L. Grubb et al., "Extracranial-intracranial bypass surgery for stroke prevention in hemodynamic cerebral ischemia the carotid occlusion surgery study randomized trial," *JAMA*, vol. 306, no. 18, pp. 1983–1992, 2011.
- [7] J. E. Thompson, D. J. Austin, and R. D. Patman, "Carotid endarterectomy for cerebrovascular insufficiency: long-term results in 592 patients followed up to thirteen years," *Annals of Surgery*, vol. 172, no. 4, pp. 663–679, 1970.
- [8] H.-L. Kao, M.-S. Lin, C.-S. Wang et al., "Feasibility of endovascular recanalization for symptomatic cervical internal carotid artery occlusion," *Journal of the American College of Cardiology*, vol. 49, no. 7, pp. 765–771, 2007.
- [9] M. Shojima, S. Nemoto, A. Morita et al., "Protected endovascular revascularization of subacute and chronic total occlusion of the internal carotid artery," *American Journal of Neuro-radiology*, vol. 31, no. 3, pp. 481–486, 2010.
- [10] Y.-L. Fan, J. Q. Wan, Z. W. Zhou et al., "Neurocognitive improvement after carotid artery stenting in patients with chronic internal carotid artery occlusion," *Vascular and Endovascular Surgery*, vol. 48, no. 4, pp. 305–310, 2014.
- [11] C. F. Yeh, Y. H. Chen, M. S. Lin et al., "Carotid-cavernous fistula after endovascular intervention for chronic carotid artery total occlusion," *Catheterization and Cardiovascular Interventions*, vol. 91, no. 4, pp. 735–741, 2018.
- [12] Y.-H. Chen, W.-S. Leong, M.-S. Lin et al., "Predictors for successful endovascular intervention in chronic carotid artery total occlusion," *Jacc-Cardiovascular Interventions*, vol. 9, no. 17, pp. 1825–1832, 2016.
- [13] B. Liu, W. Wei, Y. Wang, X. Yang, S. Yue, and J. Zhang, "Estimation and recanalization of chronic occluded internal carotid artery: hybrid operation by carotid endarterectomy and endovascular angioplasty," *World Neurosurgery*, vol. 120, pp. E457–e465, 2018.
- [14] R. L. Grubb Jr., C. P. Derdeyn, S. M. Fritsch et al., "Importance of hemodynamic factors in the prognosis of symptomatic carotid occlusion," *JAMA*, vol. 280, no. 12, pp. 1055–1060, 1998.
- [15] C. P. Derdeyn, K. D. Yundt, T. O. Videen, D. A. Carpenter, R. L. Grubb Jr., and W. J. Powers, "Increased oxygen extraction fraction is associated with prior ischemic events in patients with carotid occlusion," *Stroke*, vol. 29, no. 4, pp. 754–758, 1998.
- [16] A. Kamath, W. S. Smith, W. J. Powers et al., "Perfusion CT compared to H₂¹⁵O/O¹⁵O PET in patients with chronic cervical carotid artery occlusion," *Neuroradiology*, vol. 50, no. 9, pp. 745–751, 2008.
- [17] P. Mukherjee, H. C. Kang, T. O. Videen, R. McKinstry, W. J. Powers, and C. P. Derdeyn, "Measurement of cerebral blood flow in chronic carotid occlusive disease: comparison of dynamic susceptibility contrast perfusion MR imaging with positron emission tomography," *American Journal of Neuro-radiology*, vol. 24, no. 5, pp. 862–871, 2003.
- [18] M. Koenig, M. Kraus, C. Theek, E. Klotz, W. Gehlen, and L. Heuser, "Quantitative assessment of the ischemic brain by means of perfusion-related parameters derived from perfusion CT," *Stroke*, vol. 32, no. 2, pp. 431–437, 2001.