

Retraction

Retracted: Clinical Application of Thoracoscopic Resection of Anterior Mediastinal Tumors under the Xiphoid Process

BioMed Research International

Received 26 December 2023; Accepted 26 December 2023; Published 29 December 2023

Copyright © 2023 BioMed Research International. This is an open access article distributed under the Creative Commons Attribution License, which permits unrestricted use, distribution, and reproduction in any medium, provided the original work is properly cited.

This article has been retracted by Hindawi, as publisher, following an investigation undertaken by the publisher [1]. This investigation has uncovered evidence of systematic manipulation of the publication and peer-review process. We cannot, therefore, vouch for the reliability or integrity of this article.

Please note that this notice is intended solely to alert readers that the peer-review process of this article has been compromised.

Wiley and Hindawi regret that the usual quality checks did not identify these issues before publication and have since put additional measures in place to safeguard research integrity.

We wish to credit our Research Integrity and Research Publishing teams and anonymous and named external researchers and research integrity experts for contributing to this investigation.

The corresponding author, as the representative of all authors, has been given the opportunity to register their agreement or disagreement to this retraction. We have kept a record of any response received.

References

- [1] X. Zhu, K. Jin, X. Wu, and G. Yu, "Clinical Application of Thoracoscopic Resection of Anterior Mediastinal Tumors under the Xiphoid Process," *BioMed Research International*, vol. 2022, Article ID 2012457, 6 pages, 2022.

Research Article

Clinical Application of Thoracoscopic Resection of Anterior Mediastinal Tumors under the Xiphoid Process

Xingfeng Zhu,¹ Kuanzhe Jin,¹ Xiaobo Wu,¹ and Guiping Yu² 

¹Department of Thoracic Surgery, The Affiliated Wuxi People's Hospital of Nanjing Medical University, Wuxi, Jiangsu 214023, China

²Department of Cardiothoracic Surgery, Jiangyin Clinical College of Xuzhou Medical University, Wuxi, Jiangsu 214400, China

Correspondence should be addressed to Guiping Yu; 760020210133@xzhmu.edu.cn

Received 30 June 2022; Revised 18 July 2022; Accepted 2 August 2022; Published 23 August 2022

Academic Editor: Zhijun Liao

Copyright © 2022 Xingfeng Zhu et al. This is an open access article distributed under the Creative Commons Attribution License, which permits unrestricted use, distribution, and reproduction in any medium, provided the original work is properly cited.

Objective. To explore the feasibility and advantages of thoracoscopic resection of anterior mediastinal tumors through subxiphoid and lateral thoracic approaches. **Method.** 74 patients with anterior mediastinal tumors hospitalized in our hospital from January 2019 to January 2022 were retrospectively analyzed. They were divided into the lateral chest group (31 cases) and the infraxiphoid group (43 cases) according to different operation methods. The tumor size, operation time, intraoperative bleeding, postoperative pain score, postoperative complications, postoperative drainage tube removal time, and hospital stay were compared between the two groups. **Result.** The intraoperative bleeding and postoperative pain scores in the subxiphoid group were better than those in the lateral chest group. There was no significant difference in operation time and postoperative complications between the two groups. **Conclusion.** Compared with the lateral thoracic approach, the thoracoscopic subxiphoid approach can be more safe and effective in resectioning anterior mediastinal tumors.

1. Introduction

Anterior mediastinal tumors are common diseases in thoracic surgery and are often treated clinically by surgical means. The traditional open thoracotomy incision is large, which is easy to increase the pain of the patient, and it is also easy to cause postoperative complications such as sternum infection, which is not conducive to the patient's postoperative recovery [1]. Thoracoscopic resection has been widely used in treating clinical diseases because of its advantages of minimally invasive, small incision, small intraoperative bleeding, and mild postoperative pain [2]. Early thoracoscopic resection of anterior mediastinal tumor often uses the lateral thoracic approach, but it is easy to cause damage to the intercostal nerves and muscles of patients, causing acute and chronic pain after surgery, which is not conducive to postoperative recovery [3]. Therefore, new surgical approaches must be found to reduce intercostal injuries and postoperative pain. Thoracoscopic resection of anterior mediastinal tumors under the xiphoid process was first reported by Hsu in 2002 [4]. This method has been gradually

popularized with the development of video-assisted thoracoscopy in recent years [5–8]. The visual field of thoracoscopic resection of anterior mediastinal tumors via the subxiphoid process approach is obviously better than that of the lateral thoracic approach [9]. However, because most thoracic surgeons are more accustomed to lateral thoracic approaches, there is a big difference between the subxiphoid and lateral thoracic approaches [10–13]. Therefore, thoracoscopic resection of anterior mediastinal tumors under the xiphoid process has not been very popular at present. We retrospectively analyzed 74 patients with anterior mediastinal tumors who underwent surgery in our hospital from January 2019 to January 2022. They were divided into the lateral chest group (31 cases) and the subxiphoid process group (43 cases) according to different surgical methods. The advantages and disadvantages of the two surgical methods were compared.

2. Materials and Methods

2.1. General Information. A total of 74 patients with anterior mediastinal tumor who were hospitalized in our hospital

from January 2019 to January 2022, including 38 males and 36 females aged 16-77 years, underwent thoracoscopic subxiphoid resection of anterior mediastinal tumor 43. For example, 31 cases of anterior mediastinal tumor resection were performed by thoracoscopic lateral thoracic surgery. All patients successfully completed the operation and were discharged from the hospital after recovery. Pulmonary infection occurred in 3 cases after the operation, and pneumothorax occurred in 2 cases after extubation. The pathological diagnosis is shown in Table 1.

2.2. Surgical Methods and Perioperative Management. The patients who underwent lateral thoracic approach took the resection of the thymic tumor through the right thoracoscope as an example. After successful anesthesia (double-lumen endotracheal intubation), the left lateral decubitus position was taken, and the 1 cm incision was made into the fifth intercostal space of the right midaxillary line as the observation hole, and the thoracic lens was placed. The 2 cm incision was made as the main operation hole at the fourth intercostal space, and the 1 cm incision was made as the auxiliary operation hole at the third interaxillary anterior line. The mediastinal pleura was opened in front of the phrenic nerve from the inferior pole of the thymus, and the pleura was opened along the lower part of the internal thoracic vessels. The ultrasonic knife was used to separate the thymic tissue from the pericardium and sternum, and the attractor pushed open the contralateral mediastinal pleura and dissociated the left inferior pole of the thymus. The isthmus of the thymus was exposed upward, and the thymic vein was severed. Dissociate to the left near the beginning of the internal thoracic vessels on the right and the surface of the adjacent superior vena cava, and then, dissociate the superior pole of the right lobe of the thymus after exposing the origin of the left innominate vein. Pull the inferior pole of the right lobe of the thymus backward and downward, continue to dissociate the space between the superior pole of the thymus and the sternum to the upper pole of the left lobe, and completely remove all the thymic tissue, including the tumor. A chest tube was retained after the operation. After the operation, the chest tube was removed and discharged according to the drainage condition.

For patients with a subxiphoid approach, thoracoscopic resection of the subxiphoid thymic tumor was taken as an example. Anesthesia (single-lumen endotracheal intubation) was completed, the patient was in a horizontal position, and the legs were separated. The subxiphoid process 1 cm incision was taken as the observation hole, and the thoracoscopic lens was placed. The left and right subcostal arch clavicle midlines were used for 1 cm and 0.5 cm incisions, respectively. The ultrasonic scalpel was used to open the retrosternal space and open the mediastinal pleura on both sides. It was freed upwards from the retrosternum to the lower pole of the thyroid. According to the exposure of the retrosternal space, a sternal suspension hook was placed next to the second intercostal sternum. The mediastinal pleura was opened from the medial side of the phrenic nerves on both sides, and the lower poles of the bilateral thymus were freed to the isthmus of the thymus in front of the pericar-

TABLE 1: Statistical table of primary diseases of 74 patients with mediastinal tumors.

Diagnosis	Case
Thymoma	41
Thymocyst	9
Bronchogenic cyst	6
Hyperplasia of thymus gland	5
Thymic squamous cell carcinoma	4
Thymolipoma	1
Tumor-like hyperplasia of thymus adipose tissue	1
Ectopic parathyroid	1
Cavernous hemangioma	1
Lymphangioma	1
Diffuse large B cell lymphoma	1
Mediastinal cyst	1
Breast cancer metastasis	1
Neuroblastoma	1
Total	74

dium. Hem-o-lock was applied to disconnect the thymic vein and move upstream to the inferior pole of the thyroid on the surface of the left anonymous vein. After dissociating the superior pole of the two sides of the thymus, all the thymus tissues including tumors were completely resected. One Jackson-Pratt drainage tube was placed in the anterior mediastinum. Patients were discharged after removal of drainage tube according to postoperative drainage.

2.3. Statistical Method. SPSS 26.0 (IBM Inc., Chicago, IL, USA) software was used for statistical analysis, and the counting data were expressed in terms of frequency and percentage, χ^2 test, mean \pm standard deviation, t test, and Mann-Whitney U test, respectively. The statistical significance was $P < 0.05$.

3. Result

The general conditions of the two groups were compared in Table 2. There were significant differences in age and disease types between the subxiphoid process operation group and the lateral chest operation group ($P < 0.05$). There was no significant difference in gender composition between the two groups ($P > 0.05$).

The comparison of surgical data between the two groups is shown in Table 3. There was a significant difference in the tumor length diameter between the two groups ($P < 0.05$), and there was no significant difference in the operation time between the two groups ($P > 0.05$). The intraoperative blood loss between the two groups showed that the lateral chest group was more than the subxiphoid group; there was a significant difference ($P < 0.05$). Three days after the operation, the visual pain scores of the two groups were compared, and the subxiphoid group was lower than the lateral chest group on the first day and the third day, and there was a significant difference between the two groups ($P < 0.05$). There was no

TABLE 2: Comparison of clinical data of 74 patients with mediastinal tumor resection.

Characteristic	Total number	Lateral chest group	Subxiphoid group	<i>P</i> value
Age (years)	57.2 ± 12.2	60.9 ± 9.8	54.1 ± 13.2	0.005
Sexuality (<i>n</i> , %)				
Male	38 (51.4)	18 (58.1)	20 (46.5)	0.330
Female	36 (48.6)	13 (41.9)	23 (53.5)	
Disease (<i>n</i> , %)				
Thymic diseases	60 (81.1)	30 (96.8)	30 (69.8)	0.003
Nonthymus diseases	14 (18.9)	1 (3.2)	13 (30.2)	

TABLE 3: Comparison of surgical data of 74 patients with mediastinal tumor.

Characteristic	Lateral chest group	Subxiphoid	<i>P</i> value
Tumor length diameter (mm)	55.8 ± 25.3	42.5 ± 28.0	0.039
Operation time (min)	108.5 ± 32.7	116.5 ± 41.9	0.379
Intraoperative bleeding (ml)	60.0 ± 52.3	34.2 ± 32.7	0.011
Postoperative pain score			
First day	2.8 ± 1.0	2.9 ± 0.3	0.046
Second day	3.1 ± 1.4	2.4 ± 0.5	0.107
Third day	2.2 ± 0.4	2.0 ± 0.3	0.003
Postoperative complications (<i>n</i> , %)	2 (6.5)	3 (7.0)	0.653
Postoperative extubation time (days)	2.5 ± 0.9	4.5 ± 3.0	<0.001
Hospitalization days (days)	9.5 ± 3.1	14.7 ± 9.3	0.004

significant difference between the two groups on the second day after the operation ($P > 0.05$). There was no significant difference in the incidence of postoperative complications between the two groups ($P > 0.05$). The postoperative drainage tube indwelling time and hospital stay in the two groups were longer in the subxiphoid group than in the lateral thoracic group, and there was a significant difference between the two groups ($P < 0.05$).

The curve fitting of the length of operation and the tumor length diameter in the two groups is shown in Figures 1 and 2.

4. Discussion

The anterior mediastinum is also known as the prevascular space, the anterior boundary is the sternum, the posterior boundary is the hypothetical interface formed by the pericardium and large vessels, the upper boundary is the innominate artery, and the lower boundary is the septal muscle [14–16]. Traditional treatment of anterior mediastinal tumors or total thymectomy usually splits the sternum [17, 18]. If the tumor is inclined to one side of the chest, it can also be operated through the lateral thoracic intercostal incision. With the emergence of endoscopic technology, video-assisted thoracoscopy is gradually used in anterior mediastinal tumor resection [19, 20], but most of them are operated by lateral thoracic intercostal approach [21, 22]. This lateral thoracic approach to thoracoscopic surgery avoids splitting the sternum, reduces chest trauma, and is conducive to post-

operative recovery. It is more suitable for resectioning anterior mediastinal tumors that protrude to one side of the thoracic cavity. For patients with tumors or who need total thymectomy, the lateral thoracic approach is not ideal for exposing the retrosternal space after the mediastinal pleura is opened. It is difficult to expose the structures above the innominate vein of the superior anterior mediastinum and the contralateral phrenic nerve, which is not ideal. The surgical approach is not a substitute for a midline incision that splits the sternum. Hsu first proposed a thoracoscopic subxiphoid approach for anterior mediastinal tumor resection in 2002 to avoid sternal splitting [4]. The advantage of this surgical method lies in its good surgical field, which can well expose the lesions and important structures of the anterior mediastinum. After the thoracoscopic subxiphoid approach opens the retrosternal space, the carbon dioxide artificial pneumothorax can be used to observe the bilateral thoracic cavity and fully expose the lesions of the anterior mediastinum. Lesions between lateral phrenic nerves, all pericardial fat pads and mediastinal adipose tissue. Its exposure is close to the median incision of the split sternum, which is significantly better than the lateral thoracic approach [23]. In addition, this operation only requires single-lumen intubation anesthesia and does not require single-lung ventilation, which has less damage to lung function and is conducive to postoperative recovery.

When thoracoscopic anterior mediastinal tumor resection or thymectomy was performed via lateral thoracic approach, the posterior sternal space revealed after opening

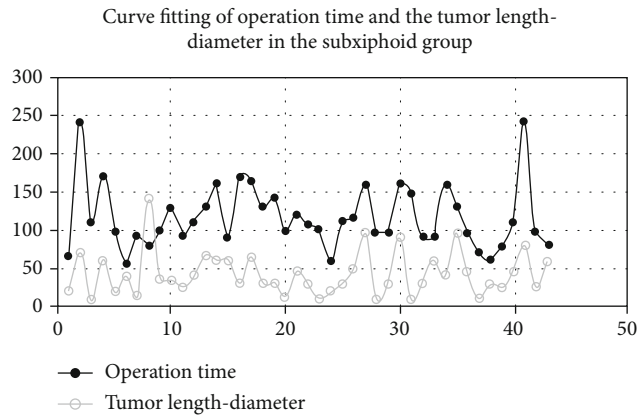


FIGURE 1: Curve fitting of operation time and the tumor length diameter in the subxiphoid group.

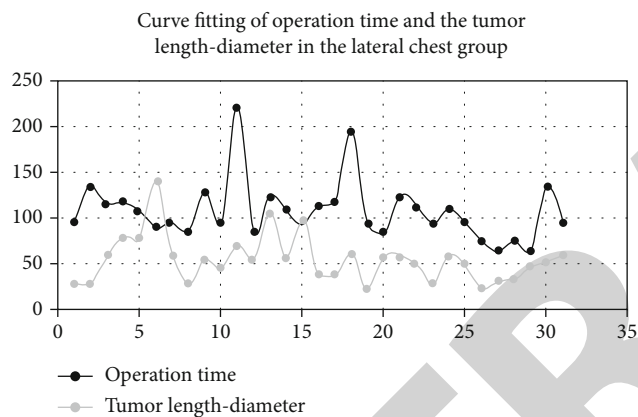


FIGURE 2: Curve fitting of operation time and the tumor length diameter in the lateral chest group.

one mediastinal pleura was small, and it was difficult to expose the contralateral phrenic nerve even after opening the contralateral pleura [24]. Moreover, due to the occlusion of blood vessels in the chest, it is difficult to reveal the lesions and important structures above the level of the anonymous vein. Therefore, when removing the free suprathymoid on both sides of the whole thymus, it is necessary to pull down the thymus and remove the suprathymoid. This requires high skill for surgeons, and due to unsatisfactory exposure, there is a certain risk of bleeding. The above two problems can be avoided through the subxiphoid approach of thoracoscope.

The first difficulty that thoracic surgeons encounter when performing a thoroscopic subxiphoid approach is placing the puncture sheath and opening the retrosternal space. This procedure may be relatively easy in patients with a large substernal angle and a large retrosternal space, but in patients with a small substernal angle and a small retrosternal space, suboptimal placement of the puncture sheath and manipulation of the retrosternal space may be difficult. The surgery cannot be continued. Due to the need to travel a long distance in the soft tissue at the thoracic-abdominal junction, the puncture sheaths of the operation holes at the lower edge of the costal arch on both sides of the subxiphoid

approach are limited in their mobility. This results in a reduction in the range of motion of operating instruments. Therefore, choosing the appropriate location when punching under the xiphoid process is critical. After punching and placing the puncture sheath, blunt dissection should be avoided to open the retrosternal space at the thoracoabdominal junction to avoid wound bleeding and affect the operative field of vision. It is precisely because the perforation and endoscopic operation of the subxiphoid approach is quite different from that of ordinary thoracoscopy, few doctors tried the subxiphoid surgical approach at first. At the beginning of the subxiphoid approach, we selected those patients whose tumors were not too large and whose general condition was good, which resulted in a certain difference in the comparison of age, disease type, and the tumor length diameter between the two groups.

After 2014, more and more doctors began to try the thoroscopic subxiphoid approach. They found that this method has the characteristics of good exposure to the operative field, less trauma, less complications, and less pain in patients [25–28]. And some doctors use video-assisted thoroscopic subxiphoid approach for lobectomy [29]. The subxiphoid approach provides a minimally invasive surgical approach for anterior mediastinal tumors and expands the indications of minimally invasive thoracoscopic treatment for invasive anterior mediastinal tumors [30]. The thoracoscopic subxiphoid approach does not need to split the sternum or enter the chest on both sides. After lifting the anterior chest wall with carbon dioxide (CO₂) artificial pneumothorax and sternal retractor, the subxiphoid approach has a very good field of vision and sufficient operating space, so it is effective for patients with myasthenia gravis who need anterior mediastinal tumor resection or thymectomy [31].

The anterior mediastinum behind the sternum is the location where the subxiphoid approach provides better exposure and is more convenient to operate. However, surgery cannot be performed if the patient's sternum angle and posterior sternum space are small. At this time, it is necessary to lift the anterior chest wall with the help of the sternal retractor to expand the retrosternal space to facilitate the operation. Sternal retractors are also suitable for surgical patients with larger tumors. Some studies have shown that the difficulty of thoracoscopic anterior mediastinal tumor resection lies in the invasion of the tumor to the surrounding important structures and blood vessels, rather than the size of the tumor [32]. However, in the operation of this group of cases, we experienced that larger tumors will increase the difficulty of operation. Thoracoscopic resection of anterior mediastinal tumors under the xiphoid process is a one-way operation from the bottom up. Suppose the size of the tumor is large. In that case, it will sometimes lead to difficulties in the operation of the upper part of the tumor, and this effect is greater than that of thoracoscopic surgery via lateral thoracic approach. After fitting the curve between the length of operation and the tumor length diameter, we can also see that there is a significant correlation between the size of the tumor and the length of operation, while the lateral thoracic approach is not so obvious.

Another advantage of the thoracoscopic subxiphoid approach compared with the lateral thoracic approach is the operation above the level of innominate vein, especially in extended thymectomy, which can completely remove the upper pole of thymus and its surrounding adipose tissue. For patients with myasthenia gravis who need extended thymectomy, extended thymectomy reported by Masaoka in 1981 has become the standard surgical treatment for patients with myasthenia gravis [33]. Most thoracic surgeons use the anterior median incision approach with sternotomy, and some thoracic surgeons use the bilateral thoracoscopic lateral thoracic approach to perform total thymectomy and extended thymectomy. The thoracoscopic subxiphoid approach can also be a good way to complete the extended thymectomy [30, 34]. Anatomical operation above the level of anonymous vein is difficult in thoracoscopic lateral thoracic approach. However, when thoracoscopic surgery via subxiphoid approach is performed, this region can have a better surgical vision and more convenient operation. Therefore, subxiphoid approach surgery is more safe and feasible than the lateral thoracic approach [35]. A meta-analysis showed that the subxiphoid approach can achieve better and safer surgical and perioperative outcomes than the thoracoscopic lateral thoracic approach [24]. We compared the video of total thymectomy with two surgical approaches, and it can be seen intuitively that subxiphoid surgery can more easily and thoroughly dissect the upper thymic pole and surrounding adipose tissue below the lower thyroid pole. Due to the good surgical field and convenient operation, the 43 patients undergoing subxiphoid approach in this group did not experience bleeding leading to conversion to split sternum surgery, and the amount of blood loss was less than that in lateral thoracic approach. And there was no significant difference in the average operation time between the subxiphoid surgery group and the lateral thoracic surgery group.

Another advantage of subxiphoid approach is that the postoperative pain is mild. Thoracoscopic lateral thoracotomy avoids the huge trauma of sternotomy, and the wound is less than the thoracotomy incision. However, the intercostal approach will inevitably damage the intercostal nerve and lead to postoperative pain. The incision of subxiphoid approach did not damage the intercostal nerve, and the postoperative pain was significantly lighter than that of the intercostal approach. In this group, 74 patients were treated with intravenous analgesia pump, nerve block anesthesia, postoperative oral analgesic drugs, external analgesic drugs, and a variety of analgesic drugs for injection due to the need for rapid rehabilitation after operation. Before the patients had unbearable pain, they were given adequate analgesic treatment. Even so, the pain scores on the first day and the third day after operation in the two groups were compared, and the scores in the subxiphoid group were lower than those in the lateral chest group, and there was significant difference between the two groups.

There was no significant difference in the incidence of postoperative complications between the two groups, but the complications were different. We routinely used the Jackson-Pratt drainage tube instead of chest tube after subxi-

phoid approach, and the patient's tolerance was significantly better than that of silicone chest tube placed between ribs in lateral thoracic surgery. However, since the subxiphoid process approach completely opens the mediastinal pleura on both sides, it is not easy to limit the infection of patients after operation. In order to fully drain, we prolonged the time of indwelling drainage tube, so the postoperative extubation time and hospitalization days were longer than those in the lateral chest group. In this group, three patients with secondary pulmonary infection after subxiphoid surgery resulted in pleural cavity and mediastinal infection and were cured and discharged after anti-infective treatment. There was no postoperative pulmonary infection in the lateral thoracic approach group of patients. However, the method of removing chest tube for 2–3 days was generally adopted due to chest tube pain. After extubation, two patients showed pneumothorax again. Therefore, we believe that the two surgical procedures have advantages and disadvantages in postoperative complications.

5. Conclusion

Thoracoscopic subxiphoid approach for anterior mediastinal tumor resection is more effective than thoracoscopic lateral thoracic approach for anterior mediastinal tumor resection.

Data Availability

The datasets used and analyzed during the current study are available from the corresponding author upon reasonable request.

Conflicts of Interest

The authors declare that they have no conflicts of interest.

References

- [1] G. J. Geng, X. Y. Yu, J. Jiang, and W. Guo, "Treatment of mediastinal lesions in thoracoscopic 3D mode," *Chinese Journal of Minimally Invasive Surgery*, vol. 16, no. 5, pp. 408–410, 2016.
- [2] H. J. Tong, Y. Q. Zang, and P. Li, "Comparison of the clinical value of televised thoracoscopic surgery and open surgery in the treatment of mediastinal tumors," *Practical Cancer Journal*, vol. 33, no. 6, 2018.
- [3] P. L. Xu, G. Chen, J. Y. Zhu, Y. Songh, L. W. Pang, and Z. M. Chen, "Case-control study of thoracoscopic hypoxic approach versus lateral thoracic approach for thoracic thymectomy," *Chinese Journal of Clinical Thoracic and Cardiovascular Surgery*, vol. 25, no. 9, pp. 799–803, 2018.
- [4] C. P. Hsu, C. Y. Chuang, N. Y. Hsu, and S. E. Shia, "Subxiphoid approach for video-assisted thoracoscopic extended thymectomy in treating myasthenia gravis," *Interactive Cardiovascular and Thoracic Surgery*, vol. 1, no. 1, pp. 4–8, 2002.
- [5] J. C. Rückert, M. Ismail, M. Swierzy et al., "Minimal-invasive chirurgie des thymus," *Der Chirurg*, vol. 79, no. 1, pp. 18–25, 2008.
- [6] C. M. Yeh, H. C. Chen, C. M. Chou, and C. P. Hsu, "Hybrid combination of small subxiphoid incision and thoracoscopic

- thymectomy for juvenile myasthenia gravis," *Journal of Pediatric Surgery*, vol. 46, no. 4, pp. 780–783, 2011.
- [7] N. Ishikawa, Y. S. Sun, L. W. Nifong, M. Oda, G. Watanabe, and W. R. Chitwood Jr., "Thoracoscopic robot-assisted extended thymectomy in the human cadaver," *Surgical Endoscopy*, vol. 24, no. 4, pp. 965–967, 2010.
 - [8] N. Ishikawa, Y. S. Sun, L. W. Nifong et al., "A new retractor system for thoracoscopic thymectomy using the anterior chest wall-lifting method," *Surgical Endoscopy*, vol. 21, no. 1, pp. 140–141, 2007.
 - [9] S. Zhang, Z. Chen, B. Li et al., "Efficiency of ectopic thymectomy by three surgical approaches in non-thymomatous myasthenia gravis," *Updates in Surgery*, vol. 74, no. 4, pp. 1435–1443, 2022.
 - [10] I. Gordo, M. Hubers, F. G. Bird et al., "Feasibility of the single-incision subxiphoid approach for video-assisted thoracoscopic surgery in dogs," *The Journal of Small Animal Practice*, vol. 61, no. 8, pp. 480–486, 2020.
 - [11] A. A. Grin, A. Y. Kordonskiy, I. S. Lvov, S. L. Arakelyan, and A. V. Sytnik, "Lateral retropleural and retrodiaphragmatic approach in patients with spine trauma and diseases: a systematic review and meta-analysis," *Voprosy neirokhirurgii imeni N.N. Burdenko*, vol. 85, no. 3, pp. 94–103, 2021.
 - [12] M. Hartert, J. Tripsky, and M. Huertgen, "Technique for ectopic intrathymic parathyroid adenoma: the uniportal subxiphoid approach," *Journal of Surgical Case Reports*, vol. 2021, no. 12, 2021.
 - [13] H. Zhang, L. Chen, Y. Zheng et al., "Robot-assisted thymectomy via subxiphoid approach: technical details and early outcomes," *Journal of Thoracic Disease*, vol. 10, no. 3, pp. 1677–1682, 2018.
 - [14] Y. H. Tsai, K. H. Ko, H. Yen, and T. W. Huang, "Intrapericardial thymoma presented as pericardial tamponade with post-operative myasthenia gravis," *Medicina (Kaunas)*, vol. 58, no. 5, 2022.
 - [15] X. Hou, S. Lin, Y. Liu et al., "Analysis of the tumor microenvironment and mutation burden identifies prognostic features in thymic epithelial tumors," *American Journal Cancer Research*, vol. 12, no. 5, pp. 2387–2396, 2022.
 - [16] A. H. AlSaffar, A. M. AlEssa, T. AlSharkawy, N. B. Alamoudi, and F. A. Makhdom, "Anterior mediastinal myelolipoma: a case report and review of the literature," *American Journal of Case Reports*, vol. 23, 2022.
 - [17] D. J. Gross, B. Zangbar, N. Muthu et al., "Saving the split: the benefits of VATS thymectomy," *Journal of Thoracic Disease*, vol. 11, no. 4, pp. 1428–1432, 2019.
 - [18] M. Zieliński, "Definitions and standard indications of minimally-invasive techniques in thymic surgery," *Journal of Visualized Surgery*, vol. 3, 2017.
 - [19] V. Mamone, S. Condino, F. Cutolo et al., "Low-computational cost stitching method in a three-eyed endoscope," *Journal of Healthcare Engineering*, vol. 2019, 2019.
 - [20] S. Nisivaco, M. Henry, R. P. Ward, and H. H. Balkhy, "Totally endoscopic robotic-assisted excision of right ventricular papillary fibroelastoma," *Journal of Robotic Surgery*, vol. 13, no. 6, pp. 779–782, 2019.
 - [21] T. Agasthian and S. J. Lin, "Clinical outcome of video-assisted thymectomy for myasthenia gravis and thymoma," *Asian Cardiovascular & Thoracic Annals*, vol. 18, no. 3, pp. 234–239, 2010.
 - [22] A. Pennathur, I. Qureshi, M. J. Schuchert et al., "Comparison of surgical techniques for early-stage thymoma: feasibility of minimally invasive thymectomy and comparison with open resection," *The Journal of Thoracic and Cardiovascular Surgery*, vol. 141, no. 3, pp. 694–701, 2011.
 - [23] C. P. Hsu, "Subxiphoid approach for thoracoscopic thymectomy," *Surgical Endoscopy*, vol. 16, no. 7, p. 1105, 2002.
 - [24] J. Li, G. Qi, Y. Liu, X. Zheng, and X. Zhang, "Meta-analysis of subxiphoid approach versus lateral approach for thoracoscopic thymectomy," *Journal of Cardiothoracic Surgery*, vol. 15, no. 1, 2020.
 - [25] T. Suda, S. Ashikari, D. Tochii, S. Tochii, and Y. Takagi, "Dual-port thymectomy using subxiphoid approach," *General Thoracic and Cardiovascular Surgery*, vol. 62, no. 9, pp. 570–572, 2014.
 - [26] M. Yano, S. Moriyama, H. Haneda, and R. Nakanishi, "Thymectomy using the subxiphoid approach," *The Journal of Thoracic and Cardiovascular Surgery*, vol. 152, no. 1, pp. 278–279, 2016.
 - [27] J. Zhao, J. Wang, and Y. Han, "Subxiphoid and subcostal arch thoracoscopic extended thymectomy: a safe and feasible minimally invasive procedure for selective stage III thymomas," *Journal of Thoracic Disease*, vol. 8, Suppl 3, pp. S258–S264, 2016.
 - [28] H. Numanami, M. Yano, and M. Yamaj, "Thoracoscopic thymectomy using a subxiphoid approach for anterior mediastinal tumors," *Annals of Thoracic and Cardiovascular Surgery*, vol. 24, no. 2, pp. 65–72, 2018.
 - [29] G. Aresu, L. Wu, L. Lin, G. Jiang, and L. Jiang, "The Shanghai Pulmonary Hospital subxiphoid approach for lobectomies," *Journal of Visualized Surgery*, vol. 2, 2016.
 - [30] M. Yano, S. Moriyama, H. Haneda et al., "The subxiphoid approach leads to less invasive thoracoscopic thymectomy than the lateral approach," *World Journal of Surgery*, vol. 41, no. 3, pp. 763–770, 2017.
 - [31] J.-H. Jiang, J. Gao, Y. Zhang, H. Wang, L. J. Tan, and J. Y. Ding, "Modified subxiphoid thoracoscopic thymectomy for locally invasive thymoma," *The Annals of Thoracic Surgery*, vol. 112, no. 4, pp. 1095–1100, 2021.
 - [32] E. Sevil, S. Bercin, T. Muderris, F. Gul, and M. Kiris, "Comparison of two different steroid treatments with hyperbaric oxygen for idiopathic sudden sensorineural hearing loss," *European Archives of Oto-Rhino-Laryngology*, vol. 273, no. 9, pp. 2419–2426, 2016.
 - [33] A. Masaoka and Y. Monden, "Comparison of the results of transsternal simple, transcervical simple, and extended thymectomy," *Annals of the New York Academy of Sciences*, vol. 377, no. 1 Myasthenia Gr, pp. 755–765, 1981.
 - [34] Y. Liu, J. Zhang, W. Wu, H. Zhang, C. Zhao, and M. Zhang, "Subxiphoid thoracoscopic thymectomy for myasthenia gravis," *Interactive Cardiovascular and Thoracic Surgery*, vol. 9, 2021.
 - [35] X. Chen, Q. Ma, X. Wang, A. Wang, and D. Huang, "Subxiphoid and subcostal thoracoscopic surgical approach for thymectomy," *Surgical Endoscopy*, vol. 35, no. 9, pp. 5239–5246, 2021.