

Segmental dilatation of the colon: Support for a muscle wall etiology

DAVID J. WALDRON, MCh, KENNETH L. BOWES, MD, LAURENCE D. JEWELL, MD

ABSTRACT: A patient with segmental dilatation of the colon who presented with chronic constipation is reported. A review of previous cases of this rarely reported condition and the typical features of the disorder is presented. A possible contributing factor to its etiology is proposed on the basis of a pathological appearance of the colonic muscle wall not previously described. *Can J Gastroenterol* 1989;3(2):47-49

Key Words: Colon, Muscle, Segmental dilatation

La dilatation segmentaire du côlon

RESUME: On rapporte le cas d'un patient atteint d'une dilatation segmentaire du côlon accompagnée de constipation chronique. D'autres cas de cette condition rarement rapportée sont passés en revue. Un facteur possible de cette étiologie est proposé d'après l'apparence pathologique de la couche musculuse de la paroi du côlon qui n'avait pas encore été décrite.

SEGMENTAL DILATATION OF THE COLON, in which an isolated dilated segment of colon is found with normal proximal and distal colon, was first described by Swenson and Rathauer in 1959 (1). Since that time, four further cases have been reported (2-5). The basic clinicopathological features of this disorder are: lack of radiological motility in the sacular segment; normal functioning colon proximal and distal to the dilatation;

obliteration of the taenia coli; marked hypertrophy of the circular and longitudinal muscle layers; and the presence of ganglion cells through the distended and undistended colon (3). Such features serve to distinguish it from other segmental disorders of the gastrointestinal tract (6,7). A further case of this unusual condition in an adult is reported and a pathological finding not previously documented is described.

CASE PRESENTATION

A 19-year-old caucasian female complaining of urinary frequency was found to have a palpable mass in the left abdomen. On functional enquiry the patient admitted to recent symptoms of anorexia and lower abdominal cramps. The patient also had intermittent diarrhea alternating with constipation and upper abdominal bloating from childhood, in spite of regular use of high fibre diets. She had several congenital anomalies suggestive of incontinentia pigmenta including a small left breast, a pulmonary systolic murmur, posterior subcapsular cataracts, eccentric pupils and a history of previous surgery for syndactyly. Radiographs revealed a moderate thoracolumbar scoliosis with a minor vertebral anomaly at L1-L2 level and disorganization of the upper denture to the right of the midline.

Routine blood tests were normal as were serum thyroid hormone levels, folic acid and urinary porphyrins. Anorectal manometry revealed a normal rectoanal inhibitory response and ganglion cells were present and normal on rectal biopsy. The upper gastrointestinal tract was normal on barium meal and follow-through examination. Barium enema and plain abdominal x-ray demonstrated marked distension of the colon proxi-

Department of Surgery and Pathology, University of Alberta, Edmonton, Alberta
Correspondence and reprints: Mr D.J. Waldron, Surgical Unit, The London Hospital, Whitechapel, London E1 1BB, United Kingdom

Received for publication September, 1988. Accepted November 23, 1988

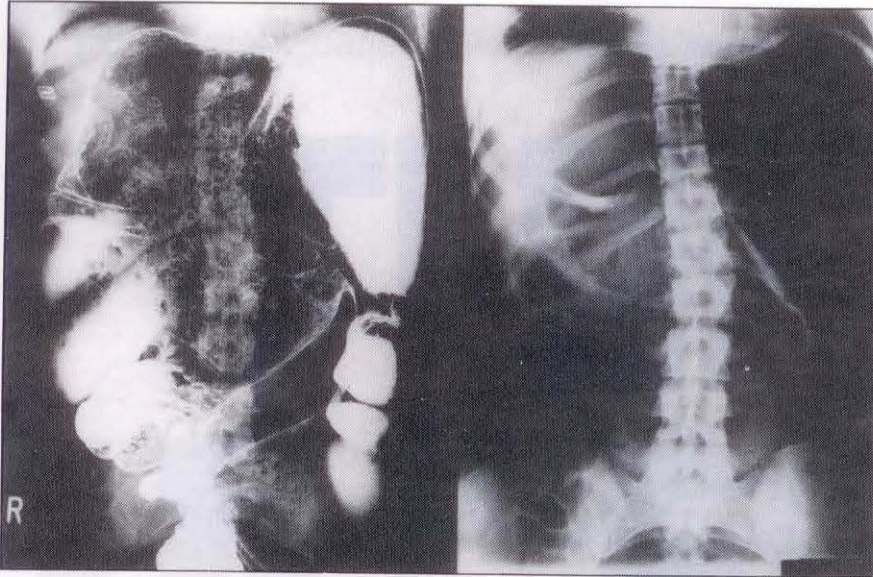


Figure 1) Barium enema and plain abdominal x-ray showing gross colonic distension proximal to the sigmoid colon

mal to the sigmoid colon (Figure 1). Colonoscopy showed a normal rectum and sigmoid colon but adequate visualization of the proximal distended segment was impossible owing to large amounts of retained stool. Transit studies using orally ingested barium impregnated pellets showed no progression beyond the dilated segment by 120 h.

Despite symptomatic treatment for a period of four years after initial presentation, abdominal pain progressively increased. Laparotomy was carried out after multiple biopsies distal to the dilated segment again demonstrated normal ganglion cells and nerve fibres. At operation, marked enlargement of the colon was seen from the mid-ascending colon to the lower descending colon (Figure 2) with a large, full thickness diverticulum of the wall of the colon just distal to the junctional zone. Marked asymmetrical thickening of the muscular wall of the dilated segment was noted, the mesenteric wall was markedly thickened and the antimesenteric wall was quite thin. A subtotal colectomy with ileosigmoid anastomosis was performed.

Histology demonstrated the presence of ganglion cells and a normal myenteric plexus throughout the resected specimen. Disorganization of the muscle layers of both muscularis propria and muscularis mucosa was present in the dilated segment. The muscle coat was thickened

and was irregularly and haphazardly distributed without its normal layering into circular and longitudinal elements. This appearance was present throughout the dilated segment but the normal anatomical arrangement was seen both proximally and distally. The diverticulum was seen to be of full thickness with normal muscle layers and nerve elements. The patient's postoperative recovery was uneventful and she remains asymptomatic five years later with a normal clinical and radiological follow-up.

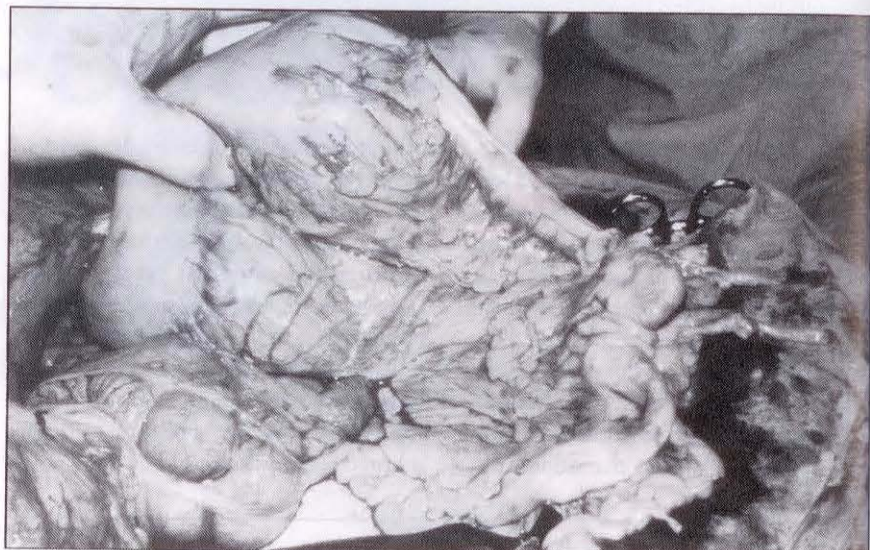

Figure 2) Exposed colon at laparotomy showing the junction between the distal normal colon and the dilated segment which shows absence of taenia coli. The cecum is seen in the lower left of the picture and shows normal muscle wall with taenia coli visible

DISCUSSION

In their initial description of segmental dilatation of the colon, Swenson and Rathauser (1) documented the clinicopathological features of three patients. Including the present report, five cases have since been added. Of this total, there are an equal number of males and females ranging in age from a newborn to 22 years. In all cases, symptoms date from early infancy and appropriate investigations rule out Hirschsprung's disease and idiopathic megacolon, these being the predominant conditions mimicking the symptom complex of segmental dilatation. The extent of the dilatation varies from localized (1,3-5) to extensive (2), a common feature being that the distal extent is usually in the region of the sigmoid colon.

The present patient had the clinical and pathological features characteristic of this disorder. Other possible diagnoses were ruled out by appropriate tests. As the response to resection of the pathological segment is universally good with no return of symptoms, it is likely that the cause of the problem lies in the dilated aspect of the colon. Early reports suggested an underlying neurological disorder in the affected segment (1,2) and a vascular etiology was considered by Helikson and colleagues (5) due to the presence of an abundant tortuous serosal vascular pattern supplied by an

enlarged marginal colonic artery in the dilated area, but these findings have not been consistent.

A common feature in all reports is that of a colonic muscle wall abnormality, both macroscopic and microscopic, confined to the dilated segment. Muscle thickening is common to all cases except that of a newborn (5) and the absence of taenia coli was seen in two other reports (2,5) as well as the present one. However, the gross and histological appearance in this report show even

greater degrees of muscle wall disorganization in which there was no identifiable layering of the muscle coat into circular or longitudinal elements in either the muscularis propria or the muscularis mucosa of the dilated segment. An etiological rather than an adaptive role for this muscular abnormality is suggested by the absence of a distal obstructive lesion in all cases described, muscle disorganization has been noted at birth (5) and one author states that muscle wall thickening was due to hyperplasia rather

than hypertrophy of cells (2).

This report adds further evidence to the concept of an abnormality of the colonic muscle wall as being the underlying cause of segmental dilatation of the colon. The present patient had a number of other congenital problems but there is no evidence for this condition being part of a congenital syndrome at this time. The importance of recognition of this disorder is in its excellent response to surgical therapy in all age groups in which it has been encountered.

ACKNOWLEDGEMENTS: David J. Waldron was supported by an Alberta Heritage grant at the time of this work.

REFERENCES

1. Swenson O, Rathauser F. Segmental dilatation of the colon: A new entity. *Am J Surg* 1959;97:734-8.
2. de Lorimier AA, Benzian SR, Gooding CA. Segmental dilatation of the colon.

- Am J Roentgenol Rad Ther Nucl Med 1971;112:100-4.
3. Brawner J, Shafer AD. Segmental dilatation of the colon. *J Pediatr Surg* 1973;8:757-8.
4. Etzioni A, Benderly A, Bar-Maor JA. Segmental dilatation of the colon, another cause of chronic constipation. *Dis Colon Rectum* 1980;23:580-2.
5. Helikson MA, Schapiro MB, Garfinkel

- DJ, Shermeta DW. Congenital segmental dilatation of the colon. *J Pediatr Surg* 1982;17:201-2.
6. Ueda T, Okamoto E. Segmental dilatation of the ileum. *J Pediatr Surg* 1972;7:292-3.
7. Al-Sulaimani SH, Alam MK, Soliman AAA, Sabah DM. Segmental duodenal aganglionosis in an adult. *Br J Surg* 1986;73:43-4.



Hindawi
Submit your manuscripts at
<http://www.hindawi.com>

