Treatment of severe odynophagia with long-acting topical nitroglycerin ointment in a patient with acquired immune deficiency syndrome

YOUNG-IN KIM, MD, FRCPC, FRED SAIBIL, MD, FRCPC, ANITA RACHLIS, MD, FRCPC

Y-I KIM, F SAIBIL, A RACHLIS. Treatment of severe odynophagia with long-acting topical nitorglycerin ointment in a patient with acquired immune deficiency syndrome. Can J Gastroenterol 1993;7(4):349-352. Odynophagia and dysphagia are common gastrointestinal symptoms experienced by patients with the acquired immune deficiency syndrome (AIDS). These symptoms can significantly decrease food intake and thus worsen nutritional status, leading to significant morbidity in AIDS patients. Esophageal candidiasis is the most common etiological factor associated with odynophagia and dysphagia in AIDS patients, but there are other infectious and malignant causes for these symptoms. Often the standard treatments for these causes are not satisfactory. The authors report a patient with AIDS who had oral candidiasis refractory to oral ketoconazole and severe odynophagia which severely restricted his oral intake. This patient responded dramatically to long-acting nitroglycerin ointment (Nitro-Bid [Hoescht-Roussel Canada, Inc]) while intravenous amphotericin B was being initiated. The authors propose that esophageal spasm may be a significant factor in the genesis of odynophagia and dysphagia in certain patients with AIDS and that smooth muscle relaxants, such as nitroglycerin or calcium channel blockers, may be important adjunctive therapies.

Key Words: *Acquired immune deficiency syndrome, Dysphagia, Esophagitis, Nitroglycerin, Odynophagia, Spasm*

Traitement de l'odynophagie sévère à l'aide d'onguent de nitroglycérine topique à longue action chez un patient atteint de SIDA

RÉSUMÉ: L'odynophagie et la dysphagie sont des symptômes gastro-intestinaux fréquents chez les patients atteints de SIDA. Ces symptômes peuvent diminuer nettement l'apport alimentaire et ainsi aggraver l'état nutritionnel, ce qui prédis-

Divisions of Gastroenterology and Infectious Disease, Sunnybrook Health Science Centre, University of Toronto, Toronto, Ontario

Correspondence and reprints: Dr Fred Saibil, Sunnybrook Health Science Centre, 2075 Bayview Avenue, Room H-52, Toronto, Ontario M4N 3M5. Telephone (416) 480-4727, Fax (416) 480-5977

Received for publication October 21, 1992. Accepted October 29, 1992

ODYNOPHAGIA AND DYSPHAGIA are common gastrointestinal symptoms experienced by patients with the acquired immune deficiency syndrome (AIDS) (1); these symptoms are the manifestations of a host of infections and malignancies commonly associated with human immunodeficiency virus (HIV) infection (2-10). These esophageal symptoms can significantly restrict oral intake, thereby worsening the nutritional status of AIDS patients in whom weight loss and tissue wasting may be the most prominent clinical features, especially at end-stage. Treatments are available for specific etiological factors (11-14) but often symptoms persist or recur after treatments have been discontinued. The exact pathogenetic pathway for these symptoms is not well established but certainly both structural and motility disturbances are likely involved. We report a patient with AIDS who had oral candidiasis and severe odynophagia refractory to oral ketoconazole and in whom esophageal spasm may have played a significant role in the symptoms. This patient promptly responded to long-acting topical nitroglycerin ointment (Nitro-Bid [Hoescht-Roussel Canada, Inc]), a smooth muscle relaxant.

pose à une morbidité considérable chez les patients sidéens. La candidose œsophagienne est le facteur étiologique le plus fréquent associé à l'odynophagie et la dysphagie chez les patients sidéens, mais il y a d'autres causes infectieuses et malignes à ces symptômes. Souvent, les thérapeutiques standard de lutte contre ces causes ne sont pas satisfaisantes. Les auteurs rapportent le cas d'un patient sidéen qui présentait une candidose orale réfractaire au kétoconazole oral et une odynophagie grave qui restreignaient sérieusement son apport alimentaire. Ce patient a répondu d'une façon phénoménale à un onguent de nitroglycérine à longue action (Nitropaste) avec un traitement concomitant d'amphotéricine B intraveineuse. Les auteurs suggèrent qu'un spasme oesophagien pourrait être en partie responsable de l'odynophagie et de la dysphagie chez certains patients sidéens et que les relaxants des muscles lisses, comme la nitroglycérine ou les inhibiteurs calciques, pourraient constituer des traitements d'appoint importants.

CASE PRESENTATION

A 42-year-old homosexual male was diagnosed in 1987 with HIV infection when he presented with oral candidiasis. Subsequently he had three bouts of *Pneumocystis carinii* pneumonia, Kaposi's sarcoma involving lungs and oral cavity, and herpes-like lesions in the rectal mucosa which were treated with oral acyclovir. The patient had been recently diagnosed with cytomegalovirus retinitis and this was treated with intravenous foscarnet (Astra Pharma Inc) initially, and then 9-(1,3-dihydroxy-2-propoxymethyl) guanine (ganciclovir). The patient had received zidovudine and 2′,3′-dideoxyinosine in the past but these had been discontinued because of bone marrow suppression and neurotoxicity, respectively. He had recurrent oral candidiasis treated with nystatin mouth wash with no significant improvement.

The patient had been complaining of sharp pain in upper pharynx, and upper and middle chest with each swallow with both liquids and solids (worse with solids), and this had been progressively worsening over the two weeks prior to admission. At admission, he was unable to take anything by mouth and had significant weight loss. He had no pyrosis, regurgitation, nausea, vomiting, abdominal pain, fever or signs of gastrointestinal hemorrhage. His oral candidiasis had been noted to be worse over the week prior to admission and had been treated with oral ketoconazole 200 mg daily for two weeks with no significant improvement. The patient had never had dysphagia or odynophagia in the past and had had no radiological or endoscopic examination of the upper gastrointestinal tract.

On examination, the patient was a cachectic appearing male with Kaposi's sarcoma involving his nose, left neck area and oral cavity. There was severe oral candidiasis but no aphthous ulcers were noted. Other systems were unremarkable. He had severe neutropenia (white blood cell count was 0.9×10^9/L) and absolute neutrophil counts were less than 500×10^6/L; this was thought to be due to ganciclovir which was discontinued.

Because of severe neutropenia, it was felt that risks of aspiration and other infectious complications outweighed potential benefits of diagnostic endoscopy. Intravenous amphotericin B was initiated via a Port-a-cath (Pharmacia) within 12 h of presentation. Long-acting nitroglycerin ointment 1" tid was started for possible esophageal spasm contributing to his odynophagia. The patient had an immediate and dramatic response to the nitroglycerine ointment and his odynophagia subsided so completely within 24 h that he was able to resume his oral intake. The nitroglycerine ointment was continued and amphotericin B was discontinued after five days (oral ketoconazole 200 mg daily was then given).

The patient was discharged on day 9 without odynophagia or dysphagia on ketoconazole 200 mg daily and Nitro-Bid 1" tid.

DISCUSSION

Odynophagia and dysphagia are very common in patients with AIDS (1). Although the exact frequencies have not been established since not all patients with esophagitis are symptomatic (15), odynophagia and dysphagia may be the most common symptoms experienced by patients with AIDS (1). These symptoms can significantly decrease food intake, thereby worsening the nutritional status of AIDS patients (1) and are responsible for significant morbidity in these patients.

The most common cause of odynophagia/dysphagia in patients with AIDS is esophageal candidiasis (1). It has been estimated that at King's County Hospital in Brooklyn, New York, more than 75% of patients with AIDS had symptoms of oroesophageal candidiasis during their hospital course (2). Opportunistic infections of the esophagus with cytomegalovirus (3,4) and herpes simplex virus, both types 1 and 2 (6), are other well known causes for odynophagia/dysphagia in AIDS patients. A recent report from Canadian investigators described oral and esophageal ulcerations in association with electron microscopic evidence of viral particles occurring coincident with HIV seroconversion (7). Other conditions which may cause odynophagia/dysphagia are cryptosporidiosis (8), esophageal lymphoma (9) and oropharyngeal Kaposi's sarcoma (10). It appears that acid-peptic reflux esophagitis may not make a significant contribution to odynophagia/dysphagia in AIDS patients. Interestingly, a recent study (16) has shown that achlorhydria or hypochlorhydria and decreased pepsin in gastric juice may be common in patients with AIDS.

The relationship between oral and esophageal candidiasis is somewhat unsettled. In prospective studies (17-21) of patients with AIDS or AIDS-related complex and oral candidiasis, almost 100% had endoscopic evidence of candidal involvement of the esophagus, regardless of the presence of odynophagia/dysphagia. Therefore, these investigators advocated that a patient with AIDS, odynophagia/dysphagia and oral candidiasis could be presumed to have esophageal candidiasis without radiological or endoscopic confirmation, and the patient could be treated with appropriate antifungal therapy. It was

suggested that further diagnostic evaluation could be reserved for nonresponders or for patients with clinical and laboratory evidence of an esophageal disorder other than esophageal candidiasis. While oral thrush often predicts concurrent esophagitis, it is clearly established that the absence of thrush does not exclude the possibility of esophageal candidiasis (22,23).

The treatment of odynophagia/dysphagia in AIDS patients depends on the specific etiology. In esophageal candidiasis, nystatin suspension and clotrimazole lozenges are generally considered to be inadequate therapy, even though they may be beneficial for treating oral candidiasis. Ketoconazole has been the mainstay of therapy for esophageal candidiasis (1). This imidazole compound increases fungal membrane permeability by interfering with sterol synthesis (1). Even though oral ketoconazole 200 mg daily is an effective therapy for esophageal candidiasis in patients with immunodeficiency states other than AIDS (11), this dose often is ineffective for eradicating esophageal candidiasis in some patients with AIDS (12). Therefore, a dose of ketoconazole up to 600 mg a day has been suggested (1) to eradicate esophageal candidiasis without causing hepatocellular toxicity. Patients who fail to respond to high dose ketoconazole may respond to the newly developed fluconazole or low dose intravenous amphotericin B.

Herpes esophagitis will respond to acyclovir, although resolution often is followed by relapses. Cytomegalovirus esophagitis has been successfully treated with ganciclovir (13,14), although large, randomized controlled studies with confirmatory endoscopic examinations are lacking.

Reduction of esophageal symptoms is an important goal since it leads to greater comfort, increased oral intake, better nutritional status and ability to take medications. Eradication of these opportunistic infections does not necessarily prolong survival and suppression only may be achieved. The odynophagia, in particular, may have multifactorial causes, such as invasion beyond the mucosa by the organism, inflammatory reactions, and tearing of candidal plaque and associated underlying mucosa by combined mechanical shearing forces of food and peristalsis, as suggested by Gould et al (24). Although it is not proven, we suggest that esophageal spasm may contribute to odynophagia/ dysphagia in these AIDS patients.

In uncontrolled trials (25-29), short- and long-acting nitrates reduced symptoms and improved manometric and radiographic patterns in some patients with spastic disorders of smooth muscle segments of the esophagus. These agents are thought to be beneficial because of their relaxant effect on smooth muscle, although the effect on manometric parameters may actually be minimal. Calcium channel blockers, in some anecdotal cases (30-33), have shown potential benefit in the management of spastic disorders of the esophagus. Calcium channel blockers relax the smooth muscle of the esophagus by interfering with calcium uptake by smooth muscle cells which are dependent on intracellular calcium for contraction. However, evidence supporting the uniform efficacy of calcium channel blockers is lacking in controlled studies (34). Successful management of symptoms of esophageal spasm has also been anecdotally reported using psychoactive drugs, including the antidepressant trazodone hydrochloride (35).

The presented patient had severe odynophagia associated with oral candidiasis refractory to oral ketoconazole. The patient also had severe neutropenia which precluded definitive diagnostic endoscopy because of concern for aspiration and infectious complications. Most likely, however, this patient did have severe esophageal candidiasis as suggested by the above discussion. Although opportunistic infections of the esophagus by cytomegalovirus or herpes virus were possibilities, he had been on ganciclovir and acyclovir for some time prior to his presentation. Intravenous amphotericin B was initiated soon after admission but the time interval between the start of amphotericin B and his dramatic response make amphotericin very unlikely as the beneficial agent. Topical nitroglycerin was selected rather than the sublingual or oral forms because of the patient's extreme odynophagia, even on swallowing his saliva. His response to nitroglycerine ointment was immediate and dramatic, suggesting esophageal spasm might have been the most significant factor in his odynophagia.

The patient immediately was able to resume his oral intake for both pleasure and nutritional support, with clear-cut improvement of his quality of life.

CONCLUSIONS

Esophageal spasm may be a significant factor in the odynophagia/dysphagia commonly experienced by AIDS patients. Nitroglycerin – topically, sublingually or orally – may provide rapid amelioration of these symptoms while specific anti-infective treatments are instituted. The symptomatic relief may allow improved nutrient intake in these patients and enhance their general nutritional status and quality of life. Other smooth muscle relaxants, such as calcium channel blockers or psychotropic medications, may have an adjunctive role in the treatment of these esohageal symptoms.

REFERENCES

1. Raufman J-P. Odynophagia/dysphagia in AIDS. Gastroenterol Clin North Am 1988;17:599.
2. Farman J, Tavitian A, Rosenthal LE. Focal esophageal candidiasis in acquired immunodeficiency syndrome (AIDS). Gastrointest Radiol 1986;11:213.
3. Balthazar EJ, Megibow AJ, Hulonick DH. Cytomegalovirus esophagitis and gastritis in AIDS. Am J Radiol 1985;144:1201.
4. St Ongi G, Bezahler GH. Giant esophageal ulcer associated with cytomegalovirus. Gastroenterology 1982;83:127.
5. Frager DH, Frager JD, Brandt LJ, et al. Gastrointestinal complications of AIDS: Radiologic features. Radiology 1986;158:597.
6. Aghar FP, Horchang HL, Nostrant TT. Herpetic esophagitis: A diagnostic challenge in immunocompromized patient. Am J Gastroenterol 1986;81:246.
7. Rabeneck L, Boyko WJ, McLean DM,

et al. Unusual esophageal ulcers containing enveloped virus-like particles in homosexual men. Gastroenterology 1986;90:1882.
8. Kazlow PG, Shah K, Benkov KJ, et al. Esophageal cryptosporidiosis in a child with acquired immunodeficiency syndrome. Gastroenterology 1986;91:1301.
9. Bernal A, del Juneo GW. Endoscopic and pathologic features of esophageal lymphoma: A report of four cases in patients with acquired immunodeficiency syndrome. Gastrointest Endosc 1986;32:96.
10. Hadderingh RJ, Tange RA, Danner SA, et al. Otorhinolaryngological findings in AIDS patients: A study of 63 cases. Arch Otorhinolaryngol 1987;244:11.
11. Fazio RA, Wicknemesinghe PC, Arsun EL, et al. Ketoconazole treatment of candida esophagitis – a prospective study of 12 cases. Am J Gastroenterol 1983;78:261.
12. Tavitian A, Raufman J-P, Rosenthal LE. Ketoconazole-resistant candida esophagitis in patients with acquired immunodeficiency syndrome. Gastroenterology 1986;90:443.
13. Masur H, Lam HC, Palestine A, et al. Effect of 9-(1,3-dihydroxy-2-propoxymethyl) guanine on severe cytomegalovirus disease in eight immunosuppresssed homosexual men. Ann Intern Med 1986;104:41.
14. Chachoua A, Dieterich D, et al. 9-(1,3-dihydroxy-2-propoxymethyl) guanine (ganciclovir) in the treatment of cytomegalovirus gastrointestinal disease with the acquired immunodeficiency syndrome. Ann Intern Med 1987;107:133.
15. Welch K, Finkberm W, Alper CF, et al. Autopsy findings in the acquired immunodeficiency syndrome. JAMA 1984;252:1152.
16. Lake-Bakaar G, Beidads S, El-Sakr, et al. Impaired gastric acid secretion in AIDS. Gastroenterology 1987;92:1488.
17. Raufman J-P, Tavitian A, Straus EW, et al. Diagnostic, therapeutic and prognostic implications of oral candidiasis in patients with AIDS or AIDS-related complex. Dig Dis Sic 1986;31:476S.
18. Tavitian A, Raufman J-P, Rosenthal LF. Oral candidiasis as a marker for esophageal candidiasis in the acquired immunodeficiency syndrome. Ann Intern Med 1986;104:54.
19. Connolly GM, Forbes A, Gluson JA, et al. Investigation of upper gastrointestinal symptoms in patients with AIDS. AIDS 1989;3:453.
20. Bianchi PG, Parente F, Cernuschi M. The diagnosis of esophageal candidiasis in patients with acquired immunodeficiency syndrome: Is endoscopy always necessary? Am J Gastroenterol 1989;84:143.
21. Roman AL, Buzou L, Hernadez-Ranz F, et al. Dysphagia and the human immunodeficiency virus: Endoscopy is not a first step. Am J Gastroenterol 1989;84:1461.
22. Scerl E, Siegel F, Geller S, et al. Gastrointestinal manifestations of acquired immunodeficiency syndrome. Gastroenterology 1984;86:1235.
23. Bonfirm D, Monteiro VLS, Jarado F, et al. Endoscopic diagnosis of opportunistic infection in acquired immunodeficiency syndrome. Dig Dis Sci 1986;31:328S.
24. Gould E, Kory UP, Raskin JP, et al. Esophageal biopsy findings in the acquired immunodeficiency syndrome (AIDS). Clinicopathologic correlation in 20 patients. South Med J 1988;81:1392.
25. Orlando RC, Bozymski EM. Clinical and manometric effects of nitroglycerin in diffuse esophageal spasm. N Engl J Med 1973;289:23.
26. Swam N. Esophageal spasm: Clinical and manometric response to nitroglycerin and long acting nitrates. Gastroenterology 1977;72:23.
27. Parker WA, Mackinnon GL. Nitrates in the treatment of diffuse esophageal spasm. Drug Intell Clin Pharm 1981;15:806.
28. Mellow MH. Effect of isosorbide and hydralazine in painful primary esophageal motility disorder. Gastroenterology 1982;83:364.
29. Kikendall JW, Mrellow MH. Effect of sublingual nitroglycerin and long-acting nitrate preparations on esophageal motility. Gastroenterology 1980;79:703.
30. Nasrallah SM, Tommaso CL, Singleton RT, et al. Primary esophageal motor disorder: Clinical response to Nifedipine. South Med J 1985;78:312.
31. Cargill G, Theodore C, Paolaggi JA. Nifedipine for relief of esophageal chest pain. N Engl J Med 1982;327:187.
32. Nasrallah SM. Nifedipine in the treatment of diffuse esophageal spasm. Lancet 1982;ii:1285.
33. Richter JE, Spurring TJ, Cordova CM, et al. Effect of oral calcium blocker, Diltiazem, on esophageal contractions. Dig Dis Sci 1984;29:649.
34. Richter JE, Dalton CB, Bradley LA, et al. Oral nifedipine in the treatment of noncardiac chest pain in patients with the nut cracker esophagus. Gastroenterology 1987;93:21.
35. Clause RE, Lustman PJ, Eckert TC, et al. Low dose Trazodone for symptomatic patients with esophageal contraction abnormalities: A double blind, placebo-controlled trial. Gastroenterology 1987;92:1027.



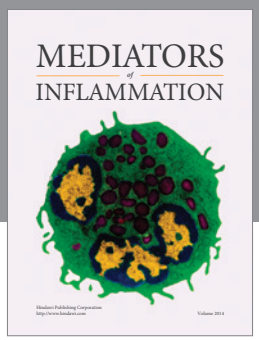

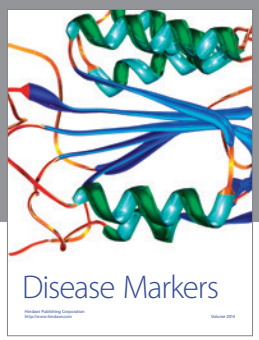



Hindawi
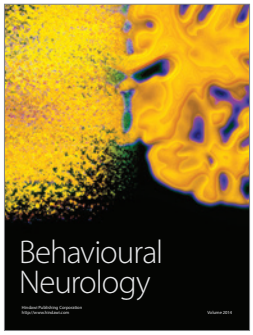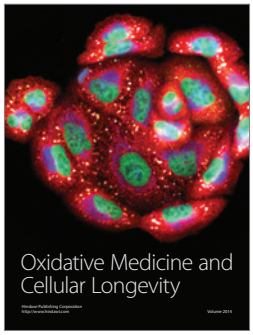
Submit your manuscripts at
http://www.hindawi.com