Gastritis induced by the helicobacter 'Gastrospirillum hominis'

SANDER JO VELDHUYZEN VAN ZANTEN MD PhD FRCPC, DICKRAN A MALATJALIAN MD FACP, LEON M DESORMEAU MD FRCPC, LEO V PEREIRA MD MSc FRCPC

SJO VELDHUYZEN VAN ZANTEN, DA MALATJALIAN, LM DESORMEAU, LV PEREIRA. Gastritis induced by the helicobacter 'Gastrospirillum hominis'. Can J Gastroenterol 1994;8(4):257-259. A patient with a 'Gastrospirillum hominis' infection in the stomach is described. 'Gastrospirillum hominis' belongs to the genus *Helicobacter* and is a rare cause of gastritis in the human stomach. It can be recognized by its distinctive morphological appearance on histology.

Key Words: *Gastritis, Gastrospirillum, Helicobacter*

Gastrite provoquée par *Helicobacter Gastrospirillum hominis*

RÉSUMÉ : Un patient atteint d'une infection à *Gastrospirillum hominis* au niveau de l'estomac est décrit ici. Le *Gastrospirillum hominis* appartient au genre *Helicobacter* et est une rare cause de gastrite chez l'homme. On peut la reconnaître par son apparence morphologique distinctive à l'histologie.

HELICOBACTER PYLORI IS NOW accepted as the most common cause for histological evidence of gastritis (1). Using routine hematoxylin and eosin staining *H pylori* organisms often can be easily recognized histologically by their characteristic curved-spiral morphology. However, sometimes special histological stains are required for identification of the organism. We describe a patient with 'Gastrospirillum hominis' infection to promote awareness that infections by spiral organisms other than *H pylori* can occur in the stomach. These organisms have a distinctive morphological appearance on gastric biopsies and can be distinguished from *H pylori* on routine hematoxylin and eosin staining.

Division of Gastroenterology and Department of Pathology, Dalhousie University, Victoria General Hospital, Halifax, Nova Scotia; and Department of Pathology and Internal Medicine, St Martha's Hospital, Antigonish, Nova Scotia

Correspondence: Dr SJO Veldhuyzen van Zanten, Division of Gastroenterology, Victoria General Hospital, RC Dickson Centre, Room 4087, 1278 Tower Road, Halifax, Nova Scotia B3H 2Y9

Received for publication March 30, 1994. Accepted April 21, 1994

CASE PRESENTATION

A 36-year-old male underwent upper gastrointestinal endoscopy because of chronic dyspepsia. There was no prior history of peptic ulcer disease. He smoked a pack of cigarettes a day for 15 years.

The only travel history outside Canada was a trip to Florida in the previous year. The patient had two healthy cats, and previously had a dog. He regularly hunted deer, rabbits and raccoons.

Upper gastrointestinal endoscopy revealed mild antral gastritis. Biopsies of the antrum demonstrated a mild chronic gastritis with an increased number of lymphocytes and a few polymorphonuclear cells. A rapid urease test to assess the urease activity of biopsies was not performed. Spiral microorganisms consistent with 'Gastrospirillum hominis' were identified at higher magnification on hematoxylin and eosin staining (Figure 1). Subsequently electron microscopy was performed using the available biopsy material (Figure 2). No *H pylori* organisms

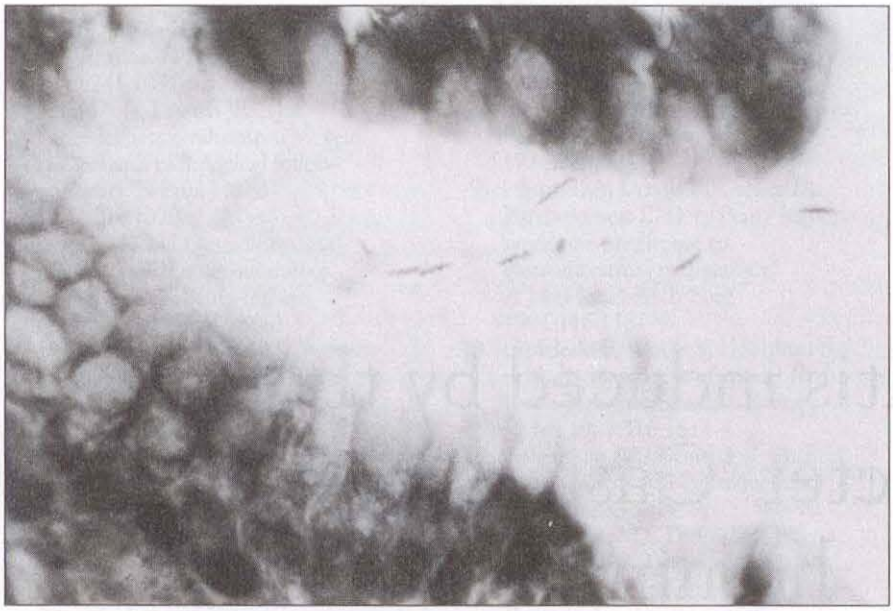

Figure 1) *Gastric biopsy (hematoxylin and eosin, x1250) demonstrating several long corkscrew-like organisms typical for 'Gastrospirillum hominis' overlying the mucosa*

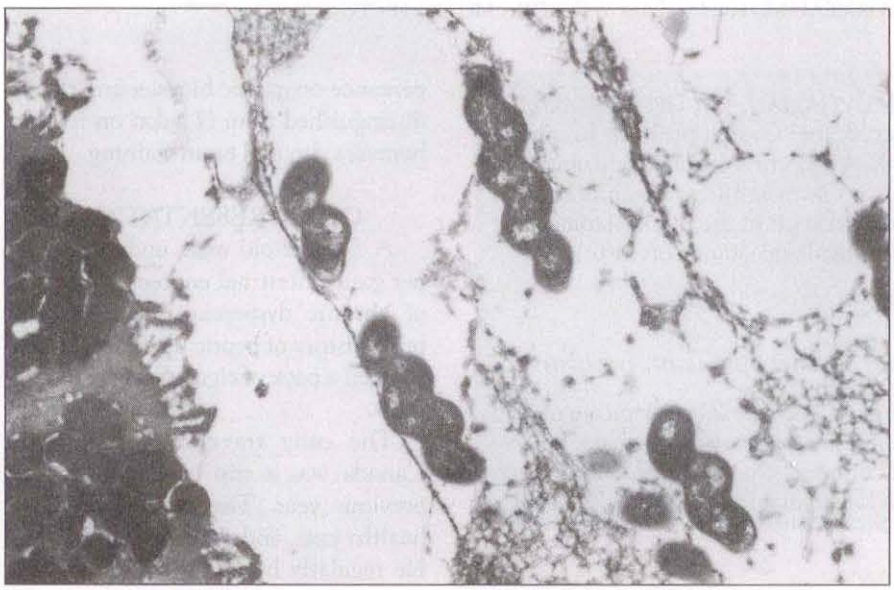

Figure 2) *Electron micrograph (x20,000) showing tightly coiled 'Gastrospirillum hominis' organisms with corkscrew appearance. Dark stained gastric mucus droplets are seen on the left*

were seen. No biopsies were taken from the body of the stomach.

The patient was treated with bismuth subsalicylate but because of side effects he subsequently received amoxicillin 500 mg tid and metronidazole 500 mg tid for 10 days. The dyspepsia symptoms resolved. A repeat endoscopy three months later was normal and biopsies from the gastric antrum and body were histologically normal. No 'Gastrospirillum hominis' organisms were seen. Cultures of gastric biopsies were negative. Serology for immunoglobulin (Ig) G antibodies against *H pylori* was negative (2).

DISCUSSION

H pylori is the cause of antral gastritis and is linked to duodenal ulcers and gastric cancer (1). Although it is by far the most common cause of antral gastritis other spiral organisms may colonize the human stomach. Approximately 60 cases of 'Gastrospirillum hominis' infection have been reported in the medical literature worldwide (3,4). The incidence of cases is low, varying from 0.25 to 0.4% (4,5). In most patients chronic dyspepsia was the reason for endoscopy.

The morphology of 'Gastrospirillum hominis' is distinctive and can be identified on routine hematoxylin and eosin staining (Figure 1). Compared with *H pylori*, 'Gastrospirillum hominis' organisms are longer (7 to 10 μM) and are more tightly coiled, with six to eight coils per bacterium, giving it a corkscrew appearance (Figure 2) (4-6).

In most cases of 'Gastrospirillum hominis' infection a chronic active gastritis is present, although this is often less severe than the inflammation caused by *H pylori*. The number of organisms is also lower and they often tend to be seen in small groups (4,7). Unlike *H pylori*, 'Gastrospirillum hominis' is usually not in close contact with the mucosal epithelial cells but is often found above the foveolar epithelial cells (4). Occasional invasion of parietal cells by 'Gastrospirillum hominis' has been seen (8,9).

To date in vitro culture of 'Gastrospirillum hominis' has been unsuccessful, rendering the taxonomic identification of the organisms tentative (for this reason the name of the organism appears between single quotation marks). In vivo culture of 'Gastrospirillum hominis' is possible by inoculating mice with scrapings from gastric biopsies obtained from infected patients. With this technique, colonization of 'Gastrospirillum hominis' can be established, maintained and transferred in the mouse (10). Sequencing the 16S ribosomal RNA gene of 'Gastrospirillum hominis' showed 96% homology with *Helicobacter felis*, indicating that 'Gastrospirillum hominis' belongs to the genus *Helicobacter* (11). Our serological assay for measuring IgG-antibodies against *H pylori* was negative in this patient. This suggests that there is no cross-reactivity of this assay with 'Gastrospirillum hominis'. We can not exclude the possibility that cross-reactivity with *H pylori* may occur and that the lack of seropositivity in this case was

due to the low number of 'Gastrospirillum hominis' organisms resulting in a low systemic antibody response.

Colonization of the gastric mucosa by 'Gastrospirillum hominis' is commonly seen in cats, dogs and other animals such as monkeys and pigs. Several human cases have been associated with pets (3,12-14). The case described here also had a history of exposure to animals.

Activity of the urease enzyme in 'Gastrospirillum hominis' infection has been demonstrated using a rapid urease test on gastric biopsies (3,4,13,15,16). However, not all infected patients have a positive urease test; their urease enzyme activity may be less than in *H pylori*. Treatment of 'Gastrospirillum hominis' is easier than *H pylori*. Although combination therapy has been used (13) most patients are eradicated when bismuth subsalicylate was used as monotherapy for four weeks (4). The chronic gastritis seen in infected patients disappears after the organism is eradicated (4). If not treated the organism can persist in the human stomach for a long time, analogous to infection by *H pylori* (4). The organism has also been found in the duodenal mucosa with evidence of duodenitis (17). In a few cases presence of 'Gastrospirillum hominis' was associated with a duodenal ulcer (18). Interestingly, in monkeys, basic acid output and peak acid output were increased in animals infected with 'Gastrospirillum hominis' compared with controls (9). Coinfection of 'Gastrospirillum hominis' and *H pylori* has also been described (4,19). Finally, 'Gastrospirillum hominis' has also been reported in children; the youngest case was three years old (20).

In summary, infection with 'Gastrospirillum hominis' is a rare cause of chronic gastritis in man and can be recognized by the distinct morphology of the organism.

ACKNOWLEDGEMENTS: Dr Veldhuyzen van Zanten holds a Career Award from the Pharmaceutical Manufacturers Association of Canada/Medical Research Council.

REFERENCES

1. Veldhuyzen van Zanten SJO, Sherman PM. *Helicobacter pylori* infection as a cause of gastritis, duodenal ulcer, gastric cancer, and non-ulcer dyspepsia: a systematic overview. Can Med Assoc J 1994;150:177-85.
2. Best LM, Veldhuyzen van Zanten SJO, Bezanson GS, et al. Serological detection of *Helicobacter pylori* by Flow Microsphere Immunofluorescent Assay (FMIA). J Clin Microbiol 1992;30:2311-7.
3. McNulty CAM, Dent JC, Curry A, et al. New spiral organism in gastric mucosa. J Clin Pathol 1989;42:585-91.
4. Heilmann KL, Borchard F. Gastritis due to spiral shaped bacteria other than *Helicobacter pylori*: clinical, histological, and ultrastructural findings. Gut 1991;32:137-40.
5. 'Gastrospirillum hominis'. Lancet 1989;ii:252-3. (Edit)
6. The *Helicobacter* genus: now we are nine. Lancet 1992;339:840-1. (Edit)
7. Lee A, O'Rourke J. Gastric bacteria other than *Helicobacter pylori*. Gastroenterol Clin North Am 1993;22:21-42.
8. Lee A, Eckstein RP, Fevre DI, Dick E, Kellow E. Non-*Campylobacter pylori* spiral organisms in the gastric antrum. Aust N Z J Med 1989;19:156-8.
9. Dubois A, Tarnawski A, Newell DG, et al. Gastric injury and invasion of parietal cells by spiral bacteria in rhesus monkeys. Gastroenterology 1991;100:884-91.
10. Dick E, Lee A, Watson G, et al. Use of the mouse for the isolation and investigation of stomach-associated, spiral-helical shaped bacteria from man and other animals. Med Microbiol 1989;29:55-62.
11. Solnick JV, O'Rourke J, Lee A, et al. 'Gastrospirillum' is a new species of Helicobacter in humans. Gastroenterology 1992;102:A699. (Abst)
12. Lee A, Dent J, Hazell S, et al. Origin of spiral organisms in the human gastric antrum. Lancet 1988;i:300-1.
13. Dye R, Marshall BJ, Frierson HF, et al. Ultrastructure of another spiral organism associated with human gastritis. Dig Dis Sci 1989;34:1787-91.
14. Dye KR, Marshall BJ, Frierson JR, Guerrant RL, McCallum RW. Ultrastructure of another spiral organism associated with human gastritis. Dig Dis Sci 1989;34:1787-91.
15. Morris A, Ali MR, Homsen L, Vanderwee M. Tightly spiral shaped bacteria in gastric antrum: are they urease positive? J Clin Pathol 1989;42:216.
16. Figura N, Guglielmetti P, Quaranta S. Spiral shaped bacteria in gastric mucosa. J Clin Pathol 1990;43:173.
17. Nakshabendi IM, Peebles SE, Lee FD, Russell RI. Spiral shaped microorganisms in the human duodenal mucosa. Postgrad Med J 1991;67:846-7.
18. Borody T, George L, Brandl S, et al. *Helicobacter pylori* negative duodenal ulcer. Am J Gastroenterol 1991;89:1154-7.
19. Queiroz DM, Carbral MM, Nogueira AM, Barbosa AJ, Rocha GA, Mendes EN. Mixed gastric infection by 'Gastrospirillum hominis' and *Helicobacter pylori*. Lancet 1990;336:507-8.
20. Oliva MM, Lazenby AJ, Perman JA. Gastritis associated with 'Gastrospirillum hominis' in children. Mod Pathol 1993;6:513-5.