Management of radiation-induced proctitis

FRANK H ANDERSON MD FRCPC, LECHENG ZENG MD

FH ANDERSON, L ZENG. Management of radiation-induced proctitis. Can J Gastroenterol 1995;9(5):277-280. The acute form of radiation intestinal injury is usually transient and self-limited, while chronic injury is permanent and progressive, and its management is unsatisfactory. As reported recently, however, several treatment options are available to control symptoms reasonably in most cases. Some approaches are of particular interest due to their efficacy, availability and simplicity. More clinical evaluations are required to confirm this initial enthusiasm.

Key Words: *Radiation enteritis, Radiation-induced proctitis, Treatment*

Traitement de la proctite provoquée par la radiothérapie

RÉSUMÉ : La forme aiguë des lésions intestinales causées par la radiothérapie est habituellement transitoire et se résorbe spontanément, alors que les lésions chroniques sont permanentes et progressives et leur traitement est insatisfaisant. Comme il a récemment été rapporté toutefois, plusieurs choix thérapeutiques s'offrent maintenant pour maîtriser les symptômes de façon raisonnable dans la plupart des cas. Certaines approches sont d'un intérêt particulier à cause de leur efficacité et de leur simplicité. Il faudra procéder à plus d'études cliniques pour confirmer ces impressions favorables.

ACUTE RADIATION BOWEL INJURY may occur during or shortly after radiotherapy to malignancies of pelvic and abdominal organs (1,2). This injury is usually self-limited (3-5). Clinical features of chronic injury may appear, however, from a few months to many years after radiotherapy (6,7). This chronic injury is not reversible, and rectal bleeding, tenesmus and diarrhea are the main symptoms.

The incidence of serious injury rises sharply following a total radiation dose exceeding 50 Gy (8). The dose per fraction, however, is considered to be a more important factor of injury than total dose (9). Careful monitoring of the dose rate and its delivery in small fractions at specified intervals remains the most reliable way to reduce intestinal complications (8).

Treatment of radiation proctitis is difficult, and nonsurgical therapy is the treatment of choice whenever possible because of high postoperative morbidity and mortality (10-12). In general, surgical intervention is necessary when it is complicated with perforation, obstruction, rectovaginal fistulas, or in intractable proctitis (7). This brief review will focus only on the conservative therapies.

STEROID ENEMAS AND SUCRALFATE ENEMAS

Steroid enemas plus oral sulfasalazine have been recommended for radiation proctitis (13,14). The efficacy of the therapy, however, has been quite variable (15-17). On the other hand, some studies have also shown that sucralfate enemas are effective (18, 19), even for patients who failed to respond to steroid enemas plus oral sulfasalazine (2,19). As a locally acting anti-ulcer agent with a generalized gastric cytoprotective effect, sucralfate binds to the defective mucosa and forms a protective barrier at the ulcer site. Its cytoprotective activity is through enhancing natural mucosal defence mechanisms by stimulation of gastric mucus secretion, epithelial cell

Division of Gastroenterology, Department of Medicine, Vancouver Hospital and Health Sciences Centre and University of British Columbia, Vancouver, British Columbia

Correspondence and reprints: Dr Frank H Anderson, Vancouver Hospital, Room 206, 700 West 10th Avenue, Vancouver, British Columbia V5Z 1L5. Telephone 604-876-5122, Fax 604-875-4429

Received for publication November 1, 1994. Accepted March 9, 1995

renewal, endogenous prostaglandins production and mucosal bloodflow (20-22).

In the only available controlled trial, the efficacy of rectal sucralfate (2 g sucralfate in 10% suspension in water twice a day) plus tablet placebo (group 1) and steroid enemas (prednisolone retention enema 20 mg every 12 h) plus oral sulfasalazine (group 2) was compared (15). After four weeks of treatment, 16 of 17 patients (94.1%) in group 1, and eight of 15 patients (53.3%) in group 2 had clinically improved ($P<0.001$ and $P<0.01$, respectively). Endoscopically, 12 patients (70.6%) in group 1 and seven patients (46.7%) in group 2 had improved ($P<0.001$ and $P<0.01$, respectively). Both treatments have been reported to be effective, but better results were obtained from group 1. In addition, side effects (myalgia, nausea and headache) occurred in two patients in group 2 versus none in group 1.

In this prospective, randomized, double-blind controlled trial, however, the comparison was only between these two therapies. No placebo-controlled trials are available yet for further evaluation. Long term follow-up studies are required and different dosages of sucralfate need to be studied.

Hydrocortisone acetate is a rectal steroid delivering 80 mg hydrocortisone per dose. It exerts its action via a local anti-inflammatory effect of hydrocortisone on the mucosa. Eleven patients in our study with hemorrhagic radiation proctitis were treated either with hydrocortisone acetate alone or in combination with rectal 5-aminosalicylic acid (5-ASA) preparations. All patients had rectal bleeding and diarrhea, and three had mild tenesmus before treatment. After one month of treatment, three of six patients (50%) treated with hydrocortisone acetate alone and three of five patients (60%) treated with the combination had clinically improved with either cessation or reduction of rectal bleeding, diarrhea and endoscopic improvement. No complications were noted. This limited observation may indicate that hydrocortisone acetate, either as a single agent or in combination with rectal 5-ASA preparations, can be beneficial for radiation proctitis. The value of hydrocortisone acetate and 5-ASA enemas needs to be evaluated in controlled studies. 5-ASA enemas alone or with oral sulfasalazine were previously reported to be ineffective for chronic radiation proctitis in a small study (3).

Absorption of hydrocortisone acetate may be related to the degree of inflammation present. The foam preparation has advantages over liquid preparations: it is easier to retain, particularly in patients with urgency and tenesmus. It might also allow better coating of the inflamed mucosa. Because the affected area in radiation proctitis is usually a very short segment, the foam preparation probably delivers a higher steroid concentration to the affected mucosa because it does not disperse as widely as the liquid retention enemas.

5-ASA ENEMAS

5-ASA enemas have been reported to be ineffective for chronic radiation proctitis in a small study. The failure to respond to 5-ASA enemas is generally attributed to the late histological changes where a vascular-ischemic pathogenesis of radiation proctitis is present, rather than an inflammatory response (3).

Advanced proctitis was noted in all four patients in this study. The response to 5-ASA enemas in an earlier stage of the disease or as a protective agent during x-ray therapy during free radical injury, however, needs to be determined (8). 5-ASA probably acts via anti-inflammation by interference with metabolism of either leukotriene A_4 or prostaglandins, altered immunoregulation, oxygen radical scavengers and bacteriostatic function.

LASER THERAPY

Laser therapy applied in bleeding radiation proctosigmoiditis dates back to 1982 (23). Promising results have been continually reported thereafter. Most patients had been unsuccessfully treated with steroid enemas, sucralfate enemas and sulfasalazine in these studies (5,16,24,25). A long term study from an analysis of 14 patients for an average of 35 follow-up months (range two to 100) demonstrated that argon laser therapy is safe and effective for chronic radiation proctitis (26). In this study, a median of two laser treatments were required to control the initial bleeding; all patients improved or stopped bleeding within five days of treatment. Ten of 14 patients (71%) required maintenance therapy for recurrent bleeding. The intervals between maintenance treatments averaged seven months (range one to 36) and increased with time. Except for some bloating and minor cramping during treatment and for 1 to 2 h afterward, no other complications occurred in the follow-up period.

Argon laser therapy is theoretically advantageous over ND:YAG laser therapy. Its energy penetrates only 1 mm and is selectively absorbed by hemoglobin. In contrast, ND:YAG laser energy penetrates 3 to 5 mm and is nonspecifically absorbed by tissue proteins. This may result in transmural necrosis and fibrosis with perforation or stricture formation (26). A long term follow-up of eight patients (up to 60 months, average 21.7 months) has shown, however, that ND:YAG laser therapy is also effective and safe, although prolonged ileus and abdominal pain as complications (four episodes in 26 laser treatments) were observed (24).

Laser therapy may cause bowel perforation. In addition, the endoscope may be prevented from reaching proximal bleeding sites if a radiation-induced stricture is present. Also, factors such as cost, facilities and special training staff should be taken into consideration. Repeated treatment may be required if bleeding recurs because of progressive formation of neovascular lesions (26).

FORMALIN TREATMENT

Formalin treatment of severe rectal bleeding from radiation proctitis was first reported in 1986 (27). Formalin treatment has recently been applied to a group of eight patients with hemorrhagic radiation proctitis, seven of whom stopped bleeding immediately after formalin application (28). No

patient had recurrent bleeding for an average of four months of follow-up (range one to six months) and none required further blood transfusion after the treatment. These patients had previously failed on various therapies such as steroid enemas, sucralfate enemas, salazosulfapyridine and colostomy. Another two patients have been reported to have excellent responses (29). This therapy was accomplished by introduction of a rigid sigmoidoscope; bleeding surface was touched with a gauze soaked in 4% formalin until bleeding ceased (usually 2 to 3 mins). Formalin treatment can be repeated until bleeding is controlled (27).

Formalin treatment is reported to be simple, inexpensive and effective, but long term follow-up studies are needed. The proximal reflux of formalin and full-thickness damage of the bowel resulting from undue prolonged contact with formalin may occur as complications. If the concentration is less than 10% and the time of contact within 2 to 4 mins these complications can be greatly reduced (28).

HYPERBARIC OXYGEN

Severe bleeding from radiation proctitis was controlled with hyperbaric oxygen (HBO) in a patient who failed on laser therapy (12). The rectal bleeding decreased progressively after 15 days of HBO therapy. No rectal bleeding recurred four months after the treatment. The authors have proposed the therapy as an alternative to surgical treatment for this condition. Many treatments are necessary, however, for this therapy to be effective. HBO was delivered by a multiple chamber. The patient was treated at 2.533×10^5 Pa for 90 mins twice daily for a total of 123 h over 41 days.

HBO has been known for its treatment of severe radiation cystitis. The mechanism by which HBO affects radiation-induced proctitis is believed to be through promoting neovascularization and fibroblast proliferation, affecting red blood cells for oxygen transport and tissue exchanges, ameliorating hypoxia and enhancing white cell killing ability (12,30).

BIPOLAR ELECTROCOAGULATION TREATMENT

The idea of using bipolar electrocoagulation (BICAP) for radiation enteritis came from BICAP treatment of gastrointestinal bleeding angiomata. In a recent trial, four patients with radiation bowel injury were treated with BICAP (31). A 2.3 mm BICAP hemostatic probe with a sigmoidoscope and a 3.2 mm probe with a rigid anoscope were connected to a 50 W bipolar generator. Electrocoagulation was applied to bleeding sites at a power setting of 5 with pulse durations of 2 s. Treatment sessions were repeated two days later until hemostasis was achieved. All bleeding stopped after 3.8 sessions on average (range three to five). No complications were noted. No bleeding recurred after an average of 12 months of follow-up. The authors considered BICAP to be an easier, likely safer, much cheaper and equally effective therapy compared with laser.

CONCLUSIONS

In more than half of radiation proctitis cases, symptoms can be reasonably controlled with rectal steroid alone or in combination with oral sulfasalazine or sucralfate enemas. Laser treatment can be an effective therapy; however, specific requirements should be met. Formalin appears to be a simple, effective and inexpensive treatment, but more studies are required. Other therapies such as 5-ASA enemas, hydrocortisone acetate, HBO therapy and BICAP likewise require more studies. Controlled studies using a placebo only, however, would be difficult due to the usual severity of the patient's symptoms (bleeding), and thus controlled studies are best done comparing different modalities of therapy.

REFERENCES

1. Novak JM, Collins JT, Donowitz M, Farman J, Sheahan DG, Spiro HM. Effects of radiation on the human gastrointestinal tract. J Clin Gastroenterol 1979;1:9-39.
2. Ladas SD, Raptis SA. Sucralfate enemas in the treatment of chronic postradiation proctitis. Am J Gastroenterol 1989;84:1587-9. (Lett)
3. Baum CA, Biddle WL, Miner PB. Failure of 5-aminosalicylic acid enemas to improve chronic radiation proctitis. Dig Dis Sci 1989;34:758-60.
4. Trier JS, Browning TH. Morphologic response of human small intestine to x-ray exposure. J Clin Invest 1966;45:194-9.
5. Buchi KN, Dixon JA. Argon laser treatment of hemorrhagic proctitis. Gastrointest Endosc 1987;33:27-30.
6. Gilinsky NH, Burns DG, Barbezat GO, Levin W, Myers HS, Marks IN. The natural history of radiation-induced proctosigmoiditis: An analysis of 88 patients. Q J Med 1983;52:40-53.
7. Jao SN, Beart RW, Gunderson LL. Surgical treatment of radiation injuries of the colon and rectum. Am J Surg 1986;51:272-7.
8. Earnest DL, Trier JS. Radiation enteritis and colitis. In: Sleisenger MH, Fordtran JS, eds. Gastrointestinal Disease, 5th edn. Philadelphia: WB Saunders Co, 1993:1257-68.
9. Lee KH, Kagan AR, Nussbaum H, Wollin MS, Winkley JH, Norman A. Analysis of dose, dose-rate and treatment time in the production of injuries by radium treatment for cancer of the uterine cervix. Br J Radiol 1976;49:430-40.
10. Galland RB, Spencer J. Surgical aspects of radiation injury to the intestine. Br J Surg 1979;66:135-8.
11. Allen-Mersh TG, Wilson EJ, Hope-Stone HF, Mann CV. The management of late radiation-induced rectal injury after treatment of carcinoma of the uterus. Surg Gynecol Obstet 1987;164:521-4.
12. Charneau J, Bouachour G, Person B, Burtin P, Ronceray J, Boyer J. Severe hemorrhagic radiation proctitis advancing to gradual cessation with hyperbaric oxygen. Dig Dis Sci 1991;36:373-5.
13. Goldstein F, Khoury J, Thorton JJ. Treatment of chronic radiation enteritis and colitis with salicylazosulfapyridine and system corticosteroids. Am J Gastroenterol 1976;65:201-8.
14. Cunningham IGE. The management of radiation proctitis. Aust NZ J Surg 1980;50:172-8.
15. Kochhar R, Patel F, Dhar A, et al. Radiation-induced procto-sigmoiditis: prospective, randomized, double-blind controlled trial of oral sulfasalazine plus rectal steroids versus rectal sucralfate. Dig Dis Sci 1991;36:103-7.
16. Stuart M, Failes DG, Killingback MJ, De Luca C. Irradiation injuries of the

large intestine. Dis Colon Rectum 1980;23:94-7.
17. O'Connor JJ. Argon laser treatment of radiation proctitis. Arch Surg 1989;124:749.
18. Henriksson R, Franzen L, Littbrand B. Does sucralfate reduce radiation-induced diarrhea? Acta Oncol 1987;26:76-7.
19. Kochhar R, Sharma SC, Gupta BB, Mehta SK. Rectal sucralfate in radiation proctitis. Lancet 1988;ii:400. (Lett)
20. Kochhar R, Mehta SK, Aggarwal R, Dhar A, Patel F. Sucralfate enema in ulcerative rectosigmoid lesions. Dis Colon Rectum 1990;33:49-51.
21. Nagashima R. Development and characteristics of sucralfate. J Clin Gastroenterol 1981;3(Suppl 2):103-10.
22. Shea-Donohue T, Steel L, Montcalm E, Dubois A. Gastric protection by sucralfate: role of mucus and prostaglandins. Gastroenterology 1986;91:660-6.
23. Leuchter RS, Petrilli ES, Dwyer RM, Hacker NF, Castalso TW, La Gasse LD. Nd:YAG laser therapy of rectosigmoid bleeding due to radiation therapy. Obstet Gynecol 1982;59:65S-7S.
24. Alexander TJ, Dwyer RM. Endoscopic Nd:YAG laser treatment of severe radiation injury of the lower gastrointestinal tract: long-term follow-up. Gastrointest Endosc 1988;34:407-11.
25. Ahlquist DA, Gostout CJ, Viggiano TR, Pemberton JH. Laser therapy for severe radiation induced rectal bleeding. Mayo Clin Proc 1986;61:927-31.
26. Taylor JG, DiSario JA, Buchi KN. Argon laser therapy for hemorrhagic radiation proctitis: long-term results. Gastrointest Endosc 1993;39:641-4.
27. Rubinstein E, Iben T, Rasmunssen RB, et al. Formalin treatment of radiation-induced hemorrhagic proctitis. Am J Gastroenterol 1986;81:44-5.
28. Seow-Choen F, Goh HS, Eu KW, Ho YH, Tay SK. A simple and effective treatment for hemorrhagic radiation proctitis using formalin. Dis Colon Rectum 1993;36:135-8.
29. Isenberg GA, Goldstein SD, Resnik AM. Formalin therapy for radiation proctitis. JAMA 1994;272:1822. (Lett)
30. Schoenrock GJ, Cianci P. Treatment of radiation cystitis with hyperbaric oxygen. Urology 1986;27:271-2.
31. Maunoury V, Brunetaud JM, Cortot A. Bipolar electrocoagulation treatment for hemorrhagic radiation injury of the lower digestive tract. Gastrointest Endosc 1991;37:492-3. (Lett)



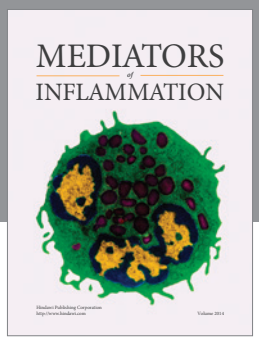

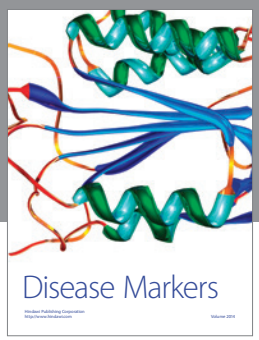



Hindawi

Submit your manuscripts at
http://www.hindawi.com