Lipoma of the colon with overlying hyperplastic epithelium

Jasim M Radhi MB ChB FRC(Path) FRCPC, TH Brian Haig MD FRCSC FACS

JM Radhi, THB Haig. Lipoma of the colon with overlying hyperplastic epithelium. Can J Gastroenterol 1997;11(8):694-695. Lipomas of the colon are submucosal nonepithelial tumours covered by intact or eroded mucosa. A large colonic lipoma present in close proximity to an area of diverticulitis is presented. The lining mucosa in this case exhibited hyperplastic changes, reminiscent of those seen in hyperplastic polyps. The significance of such mucosal changes are highlighted because adenomatous or even carcinomatous transformation, though rare, remains possible.

Key Words: *Diverticular disease, Epithelial hyperplasia, Lipoma*

Lipome du côlon avec chevauchement de l'épithélium hyperplasique

RÉSUMÉ : Les lipomes du côlon sont des tumeurs non épithéliales sous-muqueuses couvertes par une muqueuse intacte ou érodée. On décrit ici le cas d'un volumineux lipome du côlon à proximité d'une zone de diverticulite. La muqueuse dans ce cas manifestait des anomalies hyperplasiques rappelant les anomalies typiques des polypes hyperplasiques. La portée de ces anomalies de la muqueuse sont soulignées parce que, quoique rare, la possibilité de transformation adénomateuse, voire carcinomateuse, est toujours possible.

Hyperplastic polyp-type epithelium can be seen in juvenile polyps, Peutz-Jeghers polyps, inflammatory polyps and especially inflammatory cloacogenic polyps of the anal region (1). To our knowledge this is the first report of such a complex colonic lesion exhibiting an unusual juxtaposition of diverticular disease and submucosal lipoma with hyperplasia of the overlying mucosa.

Although colonic lipoma may have no clinical significance, the overlying mucosa, like the rest of colonic mucosa, is subject to any pathological process.

CASE PRESENTATION

A 45-year-old man presented with acute abdomenal pain and, at operation, was found to have a large lipoma of the sigmoid colon adjacent to diverticulitis with perforation and abscess formation. He had been passing blood per rectum for about one year. The resected specimen consisted of 10 cm of sigmoid colon with an inflammatory mass. On opening the colon there was a 5 cm yellowish mass overlying the area of inflammation (Figure 1). The colonic wall was thickened and a few diverticula were present. Microscopic examination confirmed diverticulitis with perforation and abscess formation. Within the mass was a tumour composed of mature adipose tissue covered by hyperplastic, and serrated epithelium consisting of columnar and goblet cells (Figure 2a). Features were similar to those seen in hyperplastic polyps of the colon (Figure 2b).

DISCUSSION

Intestinal lipomas are uncommon; they are more often seen in the large than the small intestine and are more frequent in the right than the left colon. These lesions tend to be solitary but may be multiple in 20% or more of the cases (2). They usually arise from the submucosa and may protrude into the lumen, causing symptoms depending on the lesion size. They may cause colonic obstruction, intussusception or a palpable mass. Biopsy may be needed when visual identification and distinction from adenomas cannot be ascertained. Pathologically, they are composed of well-circumscribed, mature adipose tissue with varying amounts of fibrous stroma covered with intact colonic mucosa. However, ulceration, necrosis, cystic degeneration and calcification are known

Departments of Pathology and Surgery, Royal University Hospital, University of Saskatchewan, Saskatoon, Saskatchewan
Correspondence and reprints: Dr JM Radhi, Department of Pathology, Royal University Hospital, University of Saskatchewan, 103 Hospital Drive, Saskatoon, Saskatchewan S7N 0W8. Telephone 306-655-2221, fax 306-655-2223, e-mail radhij@sdh.sk.ca
Received for publication July 16, 1997. Accepted October 20, 1997



Figure 1) *Resected sigmoid colon with inflammatory mass and submucosal lipoma*

complications. Inflammatory changes may be extensive, leading to abnormalities in fat cells suggestive of sarcomatous changes; such lesions have been termed atypical lipomas (3).

Rectal bleeding from diverticular disease of the colon is common; in addition, lipomas may ulcerate and lead to rectal bleeding. The lipoma in this case was large and at the site of diverticular disease. It may have played a role in the obstruction of a diverticulum and the subsequent development of diverticulitis. Moreover, the covering epithelium of the lipoma showed hyperplasia with features reminiscent of a hyperplastic polyp. The epithelium was serrated and comprised both columnar and goblet cells, lacking atypia or mitotic activity, which could represent a hyperplastic response to mucosal injury or an erosion, be due to the fusion of several hyperplastic polyps or represent a large hyperplastic polyp.

CONCLUSIONS

As indicated, hyperplastic polyp type epithelium can be seen in juvenile polyps, Peutz-Jeghers polyps, inflammatory polyps and especially inflammatory cloacogenic polyps of the anal region (1). Regenerative changes due to ischemia may also lead to mucosal hyperplasia. However, we believe the findings in this case are more likely a true hyperplastic polyp. There was no ulceration of the mucosa, and the bleeding in this case was attributed to diverticular disease. The majority of hyperplastic polyps are small, rarely larger than 1 cm in diameter. In 10% of cases hyperplastic polyps are multiple, and it is not uncommon to find up to five or 10 polyps, particularly in the distal colorectum. Hyperplastic polyps are not considered to be premalignant but do sometimes exhibit areas of adenomatous change, and hyperplastic-like epithelium is occasionally found to coexist with adenomatous areas within the same polyps. There are also isolated reports of carcinoma arising within mixed hyperplastic adenomatous polyps (4-6), and rarely carcinoma originating within pure hyperplastic polyp has been described (7). Removal of asymptomatic colonic lipoma is not necessary because it has no clinical significance (8). However attention should be paid to the overlying mucosal changes.

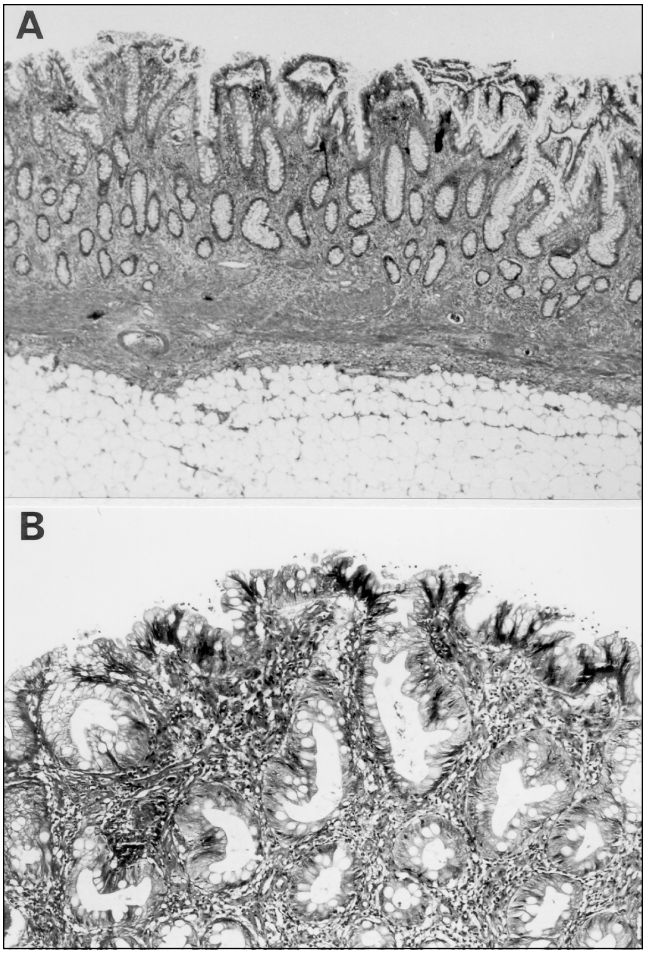

Figure 2) A *Low power view of colonic lipoma with hyperplasia of the mucosa;* **B** *Closer view highlighting the close resemblance to a hyperplastic polyp*

REFERENCES

1. Cooper H. Intestinal neoplasia. In: Stenberg SS, ed. Diagnostic Surgical Pathology, vol 2, 2nd edn. New York: Raven Press, 1994;1371-7.
2. Gordon RT, Beal JM. Lipoma of the colon. Arch Surg 1978;113:897-9.
3. Shover DC. Atypical lipomas of the colon. Report of two cases with pseudo malignant features. Dis Colon Rectum 1984;27:485-7.
4. Cooper HS, Patchefsky AS, Marks G. Adenomatous and carcinomatous changes within hyperplastic colonic epithelium. Dis Colon Rectum 1979;22:152-6.
5. William CT, Arthur JF, Bussey HJR, Morson BC. Metaplastic polyps and polyposis of the colorectum. Histopathology 1980;4:155-70.
6. Urbonski ST, Kossakowska AE, Marcon N, et al. Mixed hyperplastic adenomatous polyps – an under diagnosed entity. Report of a case of adenocarcinoma arising within a mixed hyperplastic adenomatous polyp. Am J Surg Pathol 1984;8:551-6.
7. Franzin G, Novelli P. Adenocarcinoma occurring in a hyperplastic B (metaplastic) polyp of colon. Endoscopy 1982;14:28-30.
8. Luck GD. Colonic polyps: Benign and premalignant neoplasm of the colon. In: Yamada T, Alpes DH, Onyang C, et al, eds. Textbook of Gastroenterology, vol 2, 2nd edn. Philadelphia: JB Lippincott Company, 1995:1928-9.



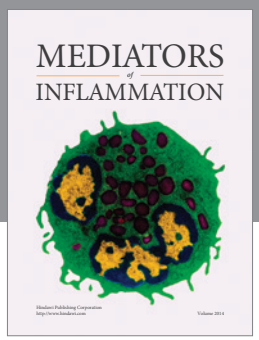

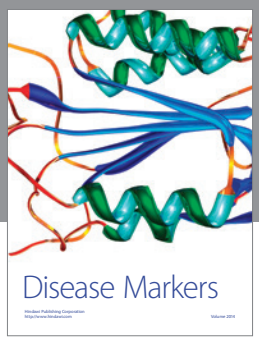



Hindawi
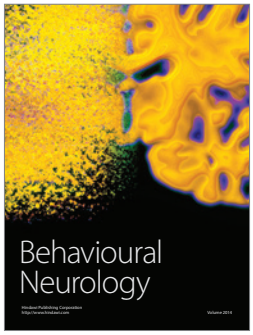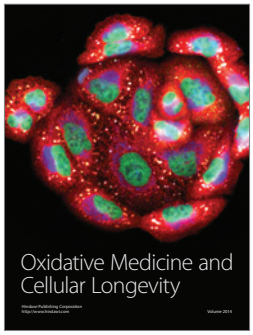
Submit your manuscripts at
http://www.hindawi.com