COPYRIGHT PULSUS GROUP INC. - DO NOT COPY

Epigastric fullness

Georg Stacher MD

G Stacher. Epigastric fullness. Can J Gastroenterol 2000;14 (Suppl D):141D-144D. Epigastric fullness may be caused by a disordered gastric motor function, resulting in delayed gastric emptying, but may also be caused by rapid emptying, leading to a distention of the proximal small intestine. A rational diagnostic approach to a patient complaining of epigastric fullness is needed to reveal the underlying disorder or disease and to enable an adequate, targeted therapy. The clinical impression based on symptoms is unreliable and cannot distinguish function disorders and benign disease from severe conditions.

Key Words: *Epigastric fullness*

Lourdeur épigastrique

RÉSUMÉ : La lourdeur épigastrique peut être causée par une dysfonction gastrique d'origine motrice, entraînant un retard de la vidange gastrique, mais peut aussi être attribuable à une vidange rapide, responsable d'une distension de la portion proximale du grêle. En présence d'un patient qui se plaint de lourdeur épigastrique, une approche diagnostique rationnelle s'impose pour mettre au jour le problème ou la maladie sous-jacents et déterminer l'approche thérapeutique la plus adéquate et la mieux ciblée. L'impression clinique fondée sur les seuls symptômes est peu fiable et ne permet pas de faire la distinction entre dysfonction bénigne et problème de santé grave.

Epigastric fullness or pain, in particular after the ingestion of a meal, as well as bloating, belching, early satiety and nausea with or without vomiting may be due to a disordered gastric motor function resulting in delayed gastric emptying, but may have its origin in rapid emptying, leading to a distention of the proximal small intestine (1). Symptoms are not reliable indicators of underlying disorders (2). In a study of 101 patients with symptoms of dyspepsia, an extended workup, including assessments of esophageal motility and transit, gastroesophageal reflux, gastric emptying, hepatobiliary function and lactose absorption, revealed abnormalities, potentially accounting for symptoms in 47 cases; no more than 11 had gastric stasis, whereas 21 had endoscopy-negative gastroesophageal reflux, six had biliary dyskinesia and five had lactase deficiency (3).

How should patients complaining of epigastric fullness be approached? The indispensable first step, taking a thorough history, may yield important clues. Patients must be asked about the occurrence and course of their symptoms; the relation between their symptoms and the composition, volume, frequency and timing of meals; self-imposed dietary restrictions or peculiarities; appetite; regurgitation; vomiting; patterns of alcohol intake; smoking habits; frequency and consistency of stools; operations and traumata; and antecedent and ongoing illnesses and their treatment. In some patients, the occurrence of symptoms may be related to the more or less recumbent position they choose to take after the evening meal in front of their television set. Advising the patient to alter her or his eating habits and postprandial activities may yield symptom relief. In patients taking medications known to affect gastrointestinal motor activity, a change in the therapeutic regimen may be beneficial.

The physical examination is often unremarkable but may suggest gastric dilation, eg, by a succussion splash. Biochemical, hematological and urine analyses may reveal hitherto unnoticed metabolic diseases, eg, diabetes mellitus or electrolyte imbalances such as hypokalemia or hypomagnesemia. Their treatment may be associated with alleviation or cessation of symptoms.

If the above-mentioned measures fail to improve a patient's condition, the patient is young and presents with no alarm symptoms (ie, weight loss, dysphagia, recurrent vomiting, anemia or evidence of bleeding), an empirical therapeutic approach may be chosen. If delayed gastric emptying is

This mini-review was prepared from a presentation made at the World Congress of Gastroenterology, Vienna, Austria, September 6 to 11, 1998
Psychophysiology Unit at the Department of Surgery, University of Vienna, Vienna, Austria
Correspondence and reprints: Professor Georg Stacher, Psychophysiology Unit at the Department of Surgery, University of Vienna, Waehringer Guertel 18-20, A-1090 Wien, Austria. Telephone +0043-1-40400-3596, fax +0043-1-40400-3478, e-mail georg.stacher@akh-wien.ac.at
Received for publication April 14, 1999. Accepted May 3, 1999

COPYRIGHT PULSUS GROUP INC. - DO NOT COPY

suspected, treatment may consist of a prokinetic agent for four weeks and, if gastroesophageal reflux disease is suspected, a four-week course of an antisecretory drug, preferably a proton-pump inhibitor. The latter can be taken with or without an additional prokinetic agent. In this case, further investigations should be undertaken only if the treatment fails (4,5). It must be taken into account that there is no clear cut relationship between the type and severity of symptoms, and the rate of gastric emptying (6,7).

In older patients as well as in patients with alarm symptoms, an esophagogastroduodenoscopy is indicated to rule out structural abnormalities and mucosal disorders. If a lesion or structural abnormality is found, the underlying disorder must be treated. For the evaluation of patients with symptoms of dyspepsia, the American College of Physicians recommended, in 1985, that endoscopy should be reserved for patients older than 45 years and for those who do not respond to an empirical antisecretory therapy lasting seven to 10 days or whose symptoms had not resolved after six to eight weeks without treatment (8). However, no controlled trials have compared the efficiency and costs of an approach comprising primary empirical therapy with an approach comprising immediate diagnostic evaluation and subsequent therapy based on the findings. Radiographic investigations were shown to be inferior to endoscopy in the detection of structural abnormalities (9,10). The above-mentioned guidelines of the American College of Physicians maintain that endoscopy rather than radiography should be the primary investigative tool (8).

When endoscopy or barium contrast studies are unrevealing in patients with symptoms likely to be caused by delayed gastric emptying, gastric emptying should be studied. When emptying is normal, further investigations should be aimed at elucidating the cause of the symptoms, ie, primarily tests for gastroesophageal reflux activity, hepatobiliary and pancreatic function, carbohydrate absorption, as well as perhaps duodenogastric reflux, and small intestinal motor and transport function.

If no explanation for the symptoms is found, it should not be assumed that one does not exist but only that the more serious and treatable causes have been excluded. To reassure the patient and to camouflage our own ignorance, we may stick to a diagnosis of 'functional' or 'idiopathic' dyspepsia.

What means are available to assess gastric motor function and its net effect – gastric emptying? A fluoroscopic barium contrast examination can, apart from providing hints at anatomical abnormalities and structural lesions, provide information about residual gastric secretions, food retained despite a prolonged fast, and the shape and size of the stomach. If the resting tension of the gastric musculature is high, the stomach is short and holds the ingested barium in the fundus and corpus; the latter parts appear globular and the antrum tubular. By contrast, if the stomach is hypotonic, it will lengthen with barium ingestion, the greater curve sags into the pelvis and the antrum appears funnel shaped.

Examinations employing a double-contrast barium meal have a better diagnostic yield than the conventional contrast technique. The stomach and duodenum are distended by carbon dioxide, and the mucosal surface is repeatedly coated with a fine layer of barium.

Although the emptying of luminal contents and gastric contractions can be detected fluoroscopically, it is not possible to obtain quantitative information. Furthermore, the imaging time is limited by the high radiation burden.

There have been attempts to use radio-opaque markers for the assessment of gastric emptying. Spheres with a diameter of 1.4±0.3 mm and a specific gravity of about 1 have been shown to be emptied from the stomach at a rate similar to that of radiolabelled liver and consistently faster than 2.4 mm spheres (11), which tend to remain in the stomach until the occurrence of an activity front of the interdigestive migrating motor complex (12). However, even small spheres are not suited for the assessment of gastric emptying because the physiological feedback control mechanisms important for the emptying of a meal, which depend on receptors responding to the composition of the chyme delivered to the small intestine, do not come into play (13-15).

Scintigraphic techniques to quantify gastric emptying are the methods best suited and documented for clinical use. The ensuing radiation burden is less than half of the radiation burden resulting from a plain radiography of the abdomen, so that recordings in children and repeat studies to evaluate treatment effects are feasible; pregnancy, however, should be ruled out. A limiting factor is the availability of a gamma scintillation camera and the necessary camera time. The radiolabelled test meal employed should be palatable, and include nutrient solid and liquid components with a total caloric load of more than 1260 kJ (5), ie, be sufficient to challenge feedback regulation of emptying by receptors located in the small intestine (13-15). Ideally, the emptying of liquid and solid meal components, which may be quite different (16), should be measured simultaneously. However, because symptoms originate mainly from a disordered emptying of solids, the assessment of liquid emptying may not be crucial (17). When gamma camera time is scarce, the use of a semisolid meal is advisable. Such a meal is emptied after a very short lag phase – the phase during which the first part of the ingesta is ground down by the antrum and thus becomes ready for delivery to the duodenum at a rate similar to that of solid meals after the lag phase (18-20). As a consequence, the time needed to assess the emptying of a semisolid meal is considerably shorter than the time needed to assess the emptying of a solid meal.

In gastric emptying studies, standardization is of utmost importance. The results are reported as the percentage of meal remaining in the stomach at specific time points after ingestion, eg, 50 min after the ingestion of a semisolid and 100 to 120 min after ingestion of a solid meal. Alternatively, the time taken for 50% of the respective meal to empty is reported. An approach that accounts for changes in emptying rate over the recording period is to express the results as the area under the curve (21). The shape of the curve may also be reported (22), although its clinical significance has not been defined. The result of an emptying study must be

COPYRIGHT PULSUS GROUP INC. - DO NOT COPY

compared with results obtained in a large group of healthy, symptom-free subjects of all age classes and both sexes. In patients with diabetes, the blood-glucose levels prevailing immediately before and during the recording have to be noted when interpreting the results because they may influence the rate of emptying (23).

Scintigraphy permits the quantification not only of emptying, but also of the distribution of the meal between the fundus, corpus and antrum at various time points after ingestion (24). Techniques have been developed for assessing the amplitude and propagation velocity of antral contractions (18-20,25-28). Their clinical utility has not yet been established.

Tracer techniques record, at given time points after the ingestion of a labelled meal, the concentrations of a marker substance in the breath or blood under the assumption that the tracer is rapidly absorbed from the small intestine but not the stomach. It is further assumed that the disappearance of the tracer from the blood is constant, and that there is little or no recirculation of tracer from other pools within the body.

The only tracer test available that enables the quantification of the emptying of a solid meal uses ^{14}carbon- or ^{13}carbon-labelled octanoic acid as a marker (29). Octanoic acid dissolves easily in, and is firmly bound to, egg yolk; the mixture is prepared as a scrambled egg. The binding is broken down in the duodenum as a result of the hydrolytic activity of pancreatic enzymes, and carbon-octanoic acid is rapidly absorbed, oxidized to carbon dioxide in the liver and excreted via the lungs. Because no apparatus is needed except for a simple device to sample the breath, the test can be carried out at the bedside. The analysis, however, is expensive because it requires a mass spectrophotometer but may become more affordable with infrared spectroscopy. The radiation burden arising from ^{14}carbon is no more than about 1% of that arising from scintigraphic emptying studies. Radiation can be avoided, with no loss of diagnostic value, by substituting the radioactive ^{14}carbon label with the stable isotope ^{13}carbon (29). However, the relation between results obtained by the breath test and results obtained scintigraphically is not always clear (30).

Two different sonographic techniques have been developed to quantify gastric emptying. With one (31), the volume of the entire stomach is determined at regular intervals after a liquid meal, by sampling cross-sections at multiple sites. However, volume determination is difficult because of the complex configuration of the stomach, and the unavoidable presence of gas in the fundus and superimposed viscera. The technique may also be difficult to perform in obese subjects. In addition, it is very time consuming and requires a skilled, experienced operator. Solid meals can be visualized sonographically, but inhomogeneities and gas may make reliable quantification impossible.

With the use of the second sonographic technique (32), changes in volume contained in the antrum, as indicated by the cross-sectional area, are measured before and after the ingestion of a nutrient liquid. The emptying time is defined as the time point at which the antral volume has returned to its preprandial value.

A new technique for acquiring three-dimensional ultrasonograms, which makes use of a magnetic position sensor system interfaced to an ultrasound scanner, may be valuable for the assessment of the intragastric distribution and emptying of a liquid meal (33). The contractile activity of the antropyloroduodenal segment and the movement of liquid gastric contents can be visualized simultaneously and three-dimensionally using duplex sonography (34).

At the time being, however, the sonographic techniques as well as more sophisticated techniques such as electrical impedance epigastrography (35), electrical impedance tomography (36,37), high speed impedance tomography (38), magnetic resonance imaging (39) and echoplanar magnetic resonance imaging (40) may be useful in the research setting but cannot be recommended as tools to record gastric emptying in clinical practice.

Manometric studies to assess gastric motor activity are, in most cases, of little help in the workup of patients with epigastric fullness. Only lumen-obliterating contractions are recorded, ie, the contractions occurring in the distal antrum and the pylorus. Moreover, antral motility shows a wide variation of patterns, even in healthy individuals.

The Barostat can be useful for assessing the tonic activity of the fundus, which, when high, may interfere with the adaptive relaxation that occurs physiologically in response to a meal, and, when low, may contribute to delayed emptying (41,42). The Barostat can also be valuable for the detection of an increased visceral sensitivity to gastric distention, which may underlie symptoms of dyspepsia in patients with normal adaptive relaxation of the fundus and normal antral motor activity (43). Therapeutic consequences to be drawn from the recognition of such disorders have not yet been established.

CONCLUSIONS

A rational diagnostic approach to a patient complaining of epigastric fullness is needed to reveal the underlying disorder or disease in due time and thus to enable an adequate, targeted therapy. The clinical impression based on symptoms is unreliable and cannot distinguish function disorders and benign disease from severe conditions.

REFERENCES

1. Wittebol P, Haarman HJTM, Hoekstra A, Smout AJPM, Akkermans LMA. Gastric emptying after gastric surgery. Dig Surg 1988;5:160-6.
2. Talley NJ, McNeil D, Piper DW. Discriminant value of dyspeptic symptoms: a study of the clinical presentation of 221 patients with dyspepsia of unknown cause, peptic ulceration, and cholelithiasis. Gut 1987;28:40-6.
3. Klauser AG, Voderholzer WA, Knesewitsch PA, Schindlbeck NE, Mller-Lissner SA. What is behind dyspepsia? Dig Dis Sci 1993;38:147-54.
4. Dubois A. Gastric dysrhythmias: pathophysiologic and etiologic factors. Mayo Clin Proc 1989;64:246-50.
5. Smout A, Horowitz M, Armstrong D. Methods to study gastric emptying. Dig Dis Sci 1994;39(Suppl):130S-2S.
6. Horowitz M, Dent J. Disordered gastric emptying: mechanical basis, assessment and treatment. Baillieres Clin Gastroenterol 1991;5:371-407.

COPYRIGHT PULSUS GROUP INC. - DO NOT COPY

7. Stanghellini V, Tosetti C, Paternic A, et al. Risk indicators of delayed gastric emptying of solids in patients with functional dyspepsia. Gastroenterology 1996;110:1036-42.
8. Endoscopy in the evaluation of dyspepsia. Health and Public Policy Committee, American College of Physicians. Ann Intern Med 1985;102:266-9.
9. Martin TR, Vennes JA, Silvis SE, Ansel HJ. A comparison of upper gastrointestinal endoscopy and radiography. J Clin Gastroenterol 1980;2:21-5.
10. Dooley CP, Larson AW, Stace NH, et al. Double-contrast barium meal and upper gastrointestinal endoscopy. A comparative study. Ann Intern Med 1984;101:538-45.
11. Meyer JH, Elashoff J, Porter-Fink V, Dressman J, Amidon GL. Human postprandial gastric emptying of 1–3-millimeter spheres. Gastroenterology 1988;94:1315-25.
12. Feldman M, Smith HJ, Simon TR. Gastric emptying of solid radiopaque markers: studies in healthy subjects and diabetic patients. Gastroenterology 1984;87:895-902.
13. Cooke AR. Control of gastric emptying and motility. Gastroenterology 1975;68:804-16.
14. Hunt JN, Smith JL, Jiang CL. Effect of meal volume and energy density on the gastric emptying of carbohydrates. Gastroenterology 1985;89:1326-30.
15. Lin HC, Doty JE, Reedy TJ, Meyer JH. Inhibition of gastric emptying by glucose depends on length of intestine exposed to nutrient. Am J Physiol 1989;256:G404-11.
16. Horowitz M, Maddox AF, Wishart JM, Harding PE, Chatterton BE, Shearman DJC. Relationships between oesophageal transit and solid and liquid gastric emptying in diabetes mellitus. Eur J Nucl Med 1991;18:229-34.
17. Chaudhury TK, Fink S. Gastric emptying in human disease states. Am J Gastroenterol 1991;86:533-8.
18. Akkermans LMA, Jacobs F, Oei HY, Roelofs JMM, Wittebol P. A non-invasive method to quantify antral contractily activity in man and dog (a preliminary report). In: Christensen J, ed. Gastrointestinal Motility. New York: Raven, 1980:195-202.
19. Stacher G, Bergmann H, Havlik E, Schmierer G, Schneider C. Effects of oral cyclotropium bromide, hyoscine N-butyl-bromide and placebo on gastric emptying and antral motor activity in healthy man. Gut 1984;25:485-90.
20. Stacher G, Bergmann H, Wiesnagrotzki S, et al. Intravenous cisapride accelerates delayed gastric emptying and increases antral contraction amplitude in patients with primary anorexia nervosa. Gastroenterology 1987;92:1000-6.
21. Stacher G, Schernthaner G, Francesconi M, et al. Cisapride vs placebo for 8 weeks on glycemic control and gastric emptying in insulin-dependent diabetes: a double-blind crossover trial. J Clin Endocrinol Metab 1999;84:2357-62.
22. Elashoff JD, Reedy TJ, Meyer JH. Analysis of gastric emptying data. Gastroenterology 1982;83:1306-12.
23. Fraser RJ, Horowitz M, Maddox AF, Harding PE, Chatterton BE, Dent J. Hyperglycemia slows gastric emptying in type I (insulin-dependent) diabetes mellitus. Diabetologia 1990;33:675-80.
24. Urbain JLC, Vekemans MC, Bouillon R, et al. Characterization of gastric antral motility disturbances in diabetes using a scintigraphic technique. J Nucl Med 1993;34:576-81.
25. Van den Maegdenbergh V, Vandecruys A, Siegel JA, De Roo MC, Urbain J-L. Visualization of the gastric mechanical systole using a new scintigraphic technique. J Nucl Med Technol 1990;18:248-51.
26. Jones K, Edelbroek M, Sun WM, et al. Evaluation of antral motility in humans using manometry and scintigraphy. Gut 1995;37:643-8.
27. Ham HR, Muls V, Cadiere GB, Froideville JL, Urbain D. A radionuclide study of regional gastric motility. Nucl Med Commun 1995;16:827-33.
28. Bergmann H, Minear G, Kugi A, Stacher G. Evaluation of gastric antral motility in four dimensions. SPIE Proc 1994;2359:724-9.
29. Ghoos YV, Maes BD, Geypens BJ, et al. Measurement of gastric emptying rate of solids by means of a carbon-labeled octanoic acid breath test. Gastroenterology 1993;104:1640-7.
30. Choi MG, Camilleri M, Burton DD, Zinsmeister AR, Forstrom LA, Nair KS. [13C]octanoic acid breath test for gastric emptying of solids: accuracy, reproducibility, and comparison with scintigraphy. Gastroenterology 1997;112:1155-62.
31. Holt S, Cervantes J, Wilkinson AA, Wallace JHK. Measurement of gastric emptying rate in humans by real-time ultrasound. Gastroenterology 1986;90:918-23.
32. Bolondi L, Bortolotti M, Santi V, Calletti T, Gaiani S, Labò G. Measurement of gastric emptying time by real-time ultrasonography. Gastroenterology 1985;89:752-9.
33. Gilja OH, Detmer PR, Jong JM, et al. Intragastric distribution and gastric emptying assessed by three-dimensional ultrasonography. Gastroenterology 1997;113:38-49.
34. Hausken T, Odegaard S, Matre K, Berstad A. Antroduodenal motility and movements of luminal contents studied by duplex sonography. Gastroenterology 1992;102:1583-90.
35. Sutton JA, Thompson S. Measurement of gastric emptying rates by radioactive isotope scanning and epigastric impedance. Lancet 1985;21:898-900.
36. Avill R, Mangnall YF, Bird NC, et al. Applied potential tomography. A new noninvasive technique for measuring gastric emptying. Gastroenterology 1987;92:1019-26.
37. Mangnall YF, Kerrigan DD, Johnson AG, Read NW. Applied potential tomography: noninvasive method for measuring gastric emptying of a solid test meal. Dig Dis Sci 1991;36:1-5.
38. Smout AJPM, Jebbink HJA, Akkermans LMA, Bruijs PPM. Role of electrogastrography and gastric impedance measurements in evaluation of gastric emptying and motility. Dig Dis Sci 1994;39(Suppl):110S-3S.
39. Schwizer W, Maecke H, Fried M. Measurement of gastric emptying by magnetic resonance imaging in humans. Gastroenterology 1992;103:369-76.
40. Evans DF, Lamont G, Stehling MK, et al. Prolonged monitoring of the upper gastrointestinal tract using echo planar magnetic resonance imaging. Gut 1993;34:848-52.
41. Azpiroz F, Malagelada J-R. Gastric tone measured by an electronic barostat in health and postsurgical gastroparesis. Gastroenterology 1987;92:934-43.
42. Ropert A, Bruley des Varannes S, Bizais Y, Roz C, Galmiche J-P. Simultaneous assessment of liquid emptying and proximal gastric tone in humans. Gastroenterology 1993;105:667-74.
43. Mearin F, Cucala M, Azpiroz F, Malagelada J-R. The origin of symptoms on the brain-gut axis in functional dyspepsia. Gastroenterology 1991;101:999-1006.



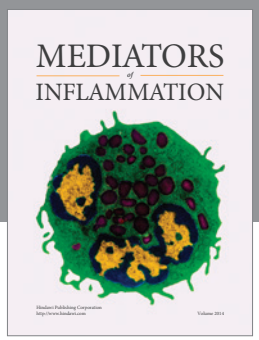

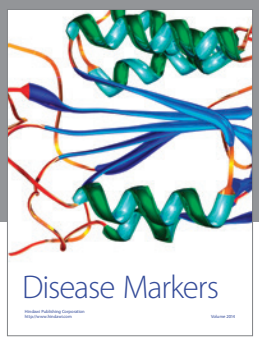



Hindawi

Submit your manuscripts at
http://www.hindawi.com