

# Autoimmune hepatitis: Clinical manifestations and diagnostic criteria

Ian G McFarlane PhD DSc(Med) FRCPath

**IG McFarlane. Autoimmune hepatitis: Clinical manifestations and diagnostic criteria.** *Can J Gastroenterol* 2001;15(2):107-113. In 1998, the International Autoimmune Hepatitis Group – a panel of 40 hepatologists and hepatopathologists from 17 countries who have a particular interest in autoimmune hepatitis (AIH) – undertook a review, in light of subsequent experience, of the descriptive criteria and diagnostic scoring system that it had proposed in 1993 for the diagnosis of AIH. This review (published in 1999) noted that the original descriptive criteria appeared to be quite robust and required only relatively minor modifications to bring them up to date with developments and experience in diagnostic modalities for liver disease in general. Analysis of published data on the application of the original criteria in nearly 1000 patients revealed that the diagnostic scoring system had an overall diagnostic accuracy of 89.8%, with a sensitivity of 98.0%. Specificity for excluding definite AIH in patients with chronic viral hepatitis and circulating autoantibodies or patients with overlapping cholestatic syndromes was 98% to 100%, but specificity for excluding probable AIH in these disorders ranged from only 60% to 80%. Modifications, including adjustments to the weightings against biochemical and histological cholestatic features, have been made to the scoring system to improve its specificity.

**Key Words:** *Chronic liver disease; Diagnostic criteria; Scoring systems*

## Hépatite chronique active : signes cliniques et critères diagnostiques

**RÉSUMÉ :** En 1998, l'International Autoimmune Hepatitis Group, réunissant 40 hépatologues et hépatopathologistes de 17 pays particulièrement intéressés à l'hépatite chronique active (HCA), a entrepris, à la lumière de l'expérience acquise, une révision des critères descriptifs et de l'échelle de cotation des symptômes qu'il avait élaborés en 1993 pour le diagnostic de l'HCA. Selon le rapport publié en 1999, les critères descriptifs initiaux semblaient toujours solides et leur mise à jour, en raison des progrès réalisés et de l'expérience acquise dans le diagnostic des maladies du foie en général, ne nécessitait que des modifications mineures. Une analyse des données publiées sur l'application des critères initiaux chez près de 1 000 patients a révélé que l'échelle de cotation diagnostique affichait une précision globale de 89,8 % et une sensibilité de 98,0 %. La spécificité permettant d'exclure une HCA certaine chez les patients présentant une hépatite virale chronique accompagnée d'autoanticorps circulants ou chez les patients présentant des syndromes cholestatiques de chevauchement était de 98 à 100 %; toutefois la spécificité permettant d'exclure une HCA probable chez les patients présentant ces troubles variait entre 60 et 80 %. Des modifications touchant, entre autres, la pondération des signes cholestatiques sur les plans biochimique et histologique ont été apportées à l'échelle de cotation afin d'améliorer la spécificité.

The syndrome that today is known as autoimmune hepatitis (AIH) (1) has been recognized in some form for more than 50 years (2-4). Early reports described AIH as a disease affecting adolescent females characterized by fluctuating jaundice, hypergammaglobulinemia and endocrine abnormalities (5,6). It was considered to be a particularly aggressive form of chronic active hepatitis (CAH) that rapidly progressed to cirrhosis, with early studies reporting mortality rates of up to 80% within five years of diagnosis in untreated patients (7-10).

Initially, the disease was thought to be caused by a viral infection, and for a time, it was known as 'active chronic viral hepatitis' (11). It was suggested that the hypergammaglobulinemia might be due to the production of antibodies against virus-altered proteins, which could induce further injury by reacting with unmodified (native) liver proteins (12,13). The impression that autoimmune mechanisms may be involved was reinforced by its similarities with systemic lupus erythematosus (SLE), including positive lupus erythematosus (LE) cell tests in many patients (11). This led

*This mini-review was prepared from a presentation made at the World Congress of Gastroenterology, Vienna, Austria, September 6 to 11, 1998  
Institute of Liver Studies, King's College Hospital, Denmark Hill, London, United Kingdom*

*Correspondence: Dr IG McFarlane, Institute of Liver Studies, King's College Hospital, Denmark Hill, London SE5 9RS, United Kingdom.*

*Telephone +171-346-3253, fax +171-346-3167, e-mail ian.mcfarlane@kcl.ac.uk*

*Received for publication July 15, 1999. Accepted July 19, 1999*

Mackay and colleagues (14) to coin the term 'lupoid' hepatitis – although these investigators were careful to distinguish it from SLE (15). Further support for an autoimmune pathogenesis came from other studies in the 1950s and early 1960s, which revealed that patients had circulating antinuclear antibodies (ANA), anti-smooth muscle antibodies (SMA) and other autoantibodies against a variety of tissue antigens (16-20). Additionally, it was found that some patients seemed to respond to immunosuppressive therapy with corticosteroids or azathioprine (21,22) – an observation that was confirmed later in several controlled trials (23-26).

In 1965, Mackay and colleagues (27) suggested that there was probably an underlying genetic predisposition to the disorder and that it should be designated 'autoimmune hepatitis'. They postulated that in predisposed individuals, following an initial episode of liver injury caused by viruses or other agents, liver antigens released from damaged hepatocytes may provoke a self-perpetuating autoimmune response leading to further hepatocellular necrosis. Later, Eddleston and Williams (28) proposed that predisposition to the disease is related to one or more inherited defects in the suppression of production of autoantibodies against native liver antigens and that following a hepatotropic virus infection, liver damage would be likely to persist in individuals lacking this control mechanism, despite elimination of the virus. Support for genetic susceptibility to AIH came from subsequent observations that, in common with some other autoimmune diseases, it is associated with inheritance of the human leukocyte antigen A1-B8-DR3 haplotype, and particularly with the DR3 and DR4 allotypes (29-34); there is an increased prevalence of other immunological disorders (particularly thyroiditis and rheumatoid arthritis) in the patients and their families (35,36); and the disease is associated with a number of apparent defects in immunoregulation, some of which are inherited together with the HLA A1-B8-DR3 haplotype and others that are not (37-44).

The discovery of the hepatitis A and B viruses in the 1960s made it possible to distinguish between some forms of viral hepatitis and 'lupoid' or 'autoimmune' hepatitis. However, as the latter condition became more widely recognized, it was clear that there was considerable heterogeneity with respect to its clinical and serological manifestations, and possibly pathogenesis (45-47). Thus, there was a general reluctance to consider AIH a distinct syndrome, and for many years, it was included within the spectrum of CAH. In retrospect, such caution was justified because, following the identification of the hepatitis C virus (HCV) in 1989 (48,49) and the finding that 'autoimmune' features (mild to moderate hypergammaglobulinemia and circulating autoantibodies) occur quite frequently in patients with HCV infection, it became apparent that a significant proportion of cases of presumed AIH in some studies were chronic hepatitis C (50-55). Additionally, it had long been recognized that these 'autoimmune' features, as well as histological changes of CAH, can often be seen at various stages in other liver disorders including primary biliary cirrhosis (PBC), primary sclerosing cholangitis (PSC),

Wilson's disease and some forms of drug-induced (including alcohol-induced) liver disease.

In the 20 years after the early clinical trials of immunosuppressive therapy in AIH, it became very clear that most patients show a striking response to corticosteroids with or without azathioprine. Although this does not provide a cure for the disease, long term remission can be sustained with low doses of these drugs. Indeed, recent studies suggest that, for carefully managed patients, life expectancy (even in those with cirrhosis) is not significantly different from that in normal age- and sex-matched populations (56,57). However, corticosteroids enhance viral replication in chronic viral hepatitis (58,59) and may increase the risk of osteodystrophy in biliary diseases. The advent of interferon therapy for chronic viral hepatitis during the 1980s also presented a problem for clinical management because it became apparent that interferon can perhaps provoke (or unmask pre-existing) AIH and other autoimmune conditions (60,61). Thus, by the early 1990s, there was considerable concern about the need for accuracy in the differential diagnosis of AIH from other chronic liver disorders in which 'autoimmune' features are sometimes evident (62).

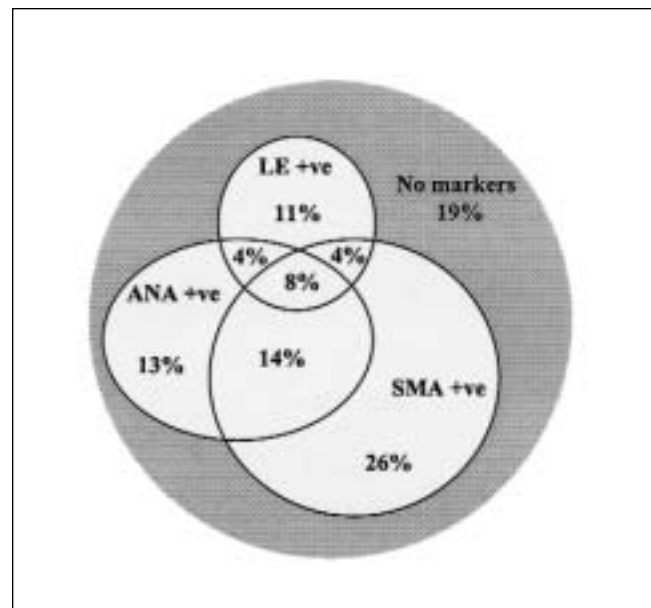
#### MOVING TOWARD CONSENSUS ON DIAGNOSTIC CRITERIA

Against the above background, in 1992, an international panel met in Brighton, United Kingdom, to review diagnostic criteria for AIH. The panel, which became the International Autoimmune Hepatitis Group, noted that there are no features that are pathognomonic of AIH and that diagnosis requires the finding of a combination of suggestive abnormalities together with careful exclusion of other possible causes of chronic liver disease. In particular, it was noted that the archetypal young female patients described above comprised a relatively small proportion of the cases seen in clinical practices; most patients were older, and although females predominated (4:1), the condition also affected males. It was also noted that only about 20% of patients had positive LE cell tests; some patients presented with ANA, others with SMA and some with both, while a small proportion (about 3% to 4% overall) had liver-kidney microsomal autoantibodies (anti-LKM1) without ANA or SMA (63); and, importantly, 10% to 20% of patients in some series (45,47,64,65) had none of these markers at presentation (Figure 1). The report of that meeting (66), termed the 'Brighton report' (67), recommended that a diagnosis of AIH should be considered in any patient presenting with an unexplained acute or chronic hepatic illness or biochemical liver test abnormalities in the absence of signs or symptoms of liver disease. It included a set of descriptive criteria and a diagnostic scoring system, which the panel suggested could be used to classify patients as having either definite or probable AIH according to how closely their presenting features conformed to classic 'lupoid' hepatitis. This approach took account of the wider spectrum of the disease that was being recognized.

**Typical presentation:** The panel noted that AIH can present at almost any age, and approximately 70% to 80% of patients are female. Onset is usually insidious, with various signs or symptoms fluctuating with a periodicity of a few months to one or two years. Lethargy (often profound fatigue) is a prominent feature and may be the dominant symptom. Other common complaints include general malaise, nausea, anorexia (with consequent weight loss), upper abdominal discomfort or pain, oligomenorrhea in women, mild pruritus, skin rashes (various, but often maculo-papular), arthralgia (with or without myalgia) and occasionally persistent low grade pyrexia. There is often a background of other autoimmune or allergic conditions in the patient or first-degree relatives. About 75% of patients are jaundiced or report prior icteric episodes, but importantly, 25% have no history of jaundice. Up to 30% already have cirrhosis at presentation, and cutaneous stigmata of chronic liver disease may be evident. Ascites and/or peripheral edema may be present even in those without cirrhosis.

Liver biochemical tests show a hepatitic profile with moderately elevated serum aminotransferase levels and bilirubin concentrations, but normal or only mildly elevated serum alkaline phosphatase. Gamma-glutamyl transferase activities may be raised but are of uncertain significance. Hyperglobulinemia is marked and is due mainly to elevation of serum immunoglobulin G. These abnormalities tend to fluctuate and may even spontaneously normalize despite ongoing liver damage (68). Thus, they do not reliably reflect the histological severity of the disease. Serum concentrations of alpha-1-antitrypsin, ceruloplasmin and copper are normal. Patients are seropositive for ANA and/or SMA or occasionally anti-LKM1 at titres of 1:40 or more (lower titres may be significant in children), and are seronegative for anti-mitochondrial antibodies and for markers of current infection with hepatotropic viruses. Liver biopsy shows features of interface hepatitis (formerly 'CAH'), including a dense, predominantly lymphoplasmacytic portal and periportal inflammatory infiltrate and piecemeal necrosis of periportal hepatocytes, without evidence of bile duct damage or other changes suggestive of other causes. In severe cases, there may be a lobular hepatitis, rosetting of liver cells, and portal-portal or porto-septal bridging necrosis.

**'Atypical' presentations:** The Brighton report acknowledged that recognition of atypical presentations of AIH and prompt institution of therapy are crucial to avoid potentially life-threatening sequelae. Up to 30% of patients, particularly in the younger age groups, present with an acute hepatitis that mimics acute viral hepatitis. Serum aminotransferase activities are often more than 20 times the upper normal limits, and patients may be deeply jaundiced, with serum bilirubin concentrations higher than 100 µmol/L. At the other end of the spectrum, 10% to 20% of patients are either apparently healthy, or have signs or symptoms that do not immediately suggest liver disease. Such 'asymptomatic' cases usually come to light through the incidental finding of mild to moderate elevations of serum aminotransferases on routine health screening or during investigation of



**Figure 1** Frequency of lupus erythematosus (LE) cells, antinuclear antibodies (ANA) and smooth muscle autoantibodies (SMA) in patients with presumed autoimmune hepatitis. Note that patients were not tested for type 1 liver-kidney microsomal antibodies or other autoantibodies. +ve Positive. Data from reference 45

some other condition (most commonly an endocrinological, rheumatological or dermatological disorder) (47,69). Cirrhosis is as common in these 'atypical' cases as in those who present as typical chronic hepatitis (47,69,70), and up to one-third of 'asymptomatic' patients with cirrhosis may present with hematemesis and/or melena as the first evidence of their liver disease (47). Precisely why there is such variability in the clinical presentation of AIH is unclear, but it reinforces the impression that the disease has a protracted subclinical prodrome that may go undetected for long periods in many cases or flare up acutely in others.

Additionally, the report noted that many of the 10% to 20% of cases who present without ANA, SMA or anti-LKM1 may become seropositive for these autoantibodies later in the course of the disease, especially during relapses. It was also noted that most such patients have other autoantibodies against various liver-derived antigens (66), although tests for these were not widely available. Nonetheless, the diagnosis could still be made on the basis of the other suggestive features of AIH (Table 1). Otherwise, with respect to demographics, liver histology and response to treatment, 'atypical' cases were indistinguishable from those with a more typical presentation.

### SUBTYPES OF AIH AND OVERLAPPING SYNDROMES

The Brighton report (66) noted a trend toward classification of AIH on the basis of serum autoantibody profiles, with ANA- and/or SMA-positive patients being defined as type 1, and those patients with anti-LKM1 being defined as type 2; also, there were proposals for several other subdivisions along these lines. It was acknowledged that such a

**TABLE 1**  
**Typical features of autoimmune hepatitis**

- Elevated serum aminotransferase levels and bilirubin concentrations with normal or only mildly elevated serum alkaline phosphatase activities
- Hyperglobulinemia with selective elevation of serum immunoglobulin G
- Seropositivity for antinuclear and/or smooth muscle antibodies or type 1 liver-kidney microsomal antibodies at titres of 1:40 or more (lower titres may be significant in children)
- Seronegativity for antimitochondrial antibodies and for markers of current infection with hepatotropic viruses
- No recent history of hepatotoxic drug use or excessive alcohol consumption
- Normal serum copper, ceruloplasmin and alpha<sub>1</sub>-antitrypsin concentrations
- History of other autoimmune diseases in the patient or the patient's family
- Liver histology showing interface hepatitis with predominantly lymphoplasmacytic portal and periportal inflammatory infiltrate, and piecemeal necrosis of periportal hepatocytes, without bile duct damage or other prominent features that usually are more suggestive of other liver disorders

classification may be useful for research purposes, but because the various subdivisions did not appear to define distinct clinical or pathogenetic groups, it could not be recommended for general application. The report noted that overlap between AIH and other diseases (particularly PBC and PSC) was well recognized but that there were insufficient data on these relatively rare cases to make recommendations about criteria for their differential diagnosis from AIH. It also noted that due to the uncertainties that existed at that time about false-positivity in testing for HCV infection, there was insufficient evidence to draw conclusions about a possible relationship between HCV and AIH. Accordingly, the panel recommended that anti-HCV-seropositive patients could be included within the category of probable AIH pending clarification of their HCV status.

### REVIEW OF THE BRIGHTON CRITERIA

In the years following the publication of the Brighton report (66), the descriptive criteria and diagnostic scoring system proposed by the International AIH Group have been widely used by many investigators. By 1998, it was thought that there were sufficient published data to undertake a comprehensive review of these recommendations, in light of this information, other developments and experience in diagnostic modalities for liver disease in general. This review (71) indicated that, overall, the Brighton criteria appeared to be quite robust and required only relatively minor adjustments to bring them up to date.

The review confirmed that AIH predominantly affects females (but is being increasingly recognized in males) and that it can present at almost any age. However, it was noted that previous impressions of a bimodal distribution in age at presentation (with peaks around puberty and between the fifth and sixth decades of life) (72) probably

reflect patterns of patient referrals to specialist centres, and that the majority of patients with AIH seen in gastroenterology practices today are above 50 years of age (66,73,74), although the condition may be underdiagnosed in elderly people (75). The presenting clinical, biochemical, serological and histological features (both typical and 'atypical') described above are also confirmed, but it is noted that histological features such as lymphoid aggregates, steatosis, deposits of copper or iron, and bile ductule proliferation lack the required specificity to exclude AIH, except when such features are sufficiently prominent to raise doubts about the diagnosis. Morphological changes that should exclude AIH are bile duct damage typical of PBC or PSC (ie, granulomatous cholangitis, or severe concentric periductal fibrosis and/or a substantial periportal ductular reaction with copper or copper-associated protein accumulation) and well defined granulomas.

Progress in defining subspecificities of ANA, SMA and anti-LKM1 has been noted, but some subspecificities (eg, those of ANA) have limited clinical implications, while reliance on others (eg, anti-actin SMA) can lead to missed diagnoses (76-78); also, testing for such subspecificities is not yet provided by most routine clinical immunology laboratories. Some of the more specialized autoantibodies that react with liver-derived antigens continue to be of interest, but tests for these are not yet widely available. Diagnosis of AIH, therefore, continues to rely on the detection of ANA, SMA and anti-LKM1 by conventional techniques. However, recent studies have indicated that high titres of perinuclear antineutrophil cytoplasmic antibodies, detected by immunofluorescence on ethanol-fixed neutrophils, can be found in the majority of patients with AIH (79-83). Thus, perinuclear antineutrophil cytoplasmic antibodies may prove to be a useful addition to the diagnostic repertoire, particularly for patients who are seronegative for ANA, SMA and anti-LKM1.

The review noted that classification of AIH as type 1 and type 2 is likely to remain in common usage but that this classification is of uncertain clinical use because it is not exclusive (72), and long term outcome is similar in both types (84). Experience has shown that the validity of other subdivisions of AIH based on autoantibody profiles has not been substantiated (72,85), and these still cannot be recommended.

The very marked improvements that have been made in recent years in the reliability, specificity and availability of tests for HCV infection, and the significant advances that have been made in knowledge about this and other hepatotropic viruses, have allowed for a reduction in some of the requirements specified in the Brighton report for excluding hepatitis viral infections in diagnosing AIH. In particular, it is noted that the hepatitis G virus does not appear to be a major etiological factor in AIH (86-88), and other viruses (such as cytomegalovirus and Epstein-Barr virus) only rarely cause hepatitis. Thus, the obligatory exclusion of markers of infection with agents other than the hepatitis A, B and C viruses, and weighting against AIH in patients who



are seronegative for these markers but who have risk factors for viral hepatitis, is now considered unnecessary in most cases. The possibility that some patients with chronic viral hepatitis may have concomitant AIH must, however, be kept in mind. Thus, whereas recent evidence indicates that interferon therapy is generally safe in most patients with chronic viral hepatitis who have serum autoantibodies (89-93), it is recommended that patients should be screened for autoantibodies before, and monitored carefully during, interferon therapy.

Cholestatic syndromes overlapping with AIH continue to lead to difficult, but interesting, diagnostic problems. The review of the Brighton criteria undertaken in 1998 (71) noted that these syndromes have been variously described as 'autoimmune cholangitis' or 'autoimmune cholangiopathy', but that there is still no universal definition of these terms or classification of the conditions. This review highlighted a need for an international working party to clarify this. Overlapping with PBC is most commonly reported, but there now appears to be a consensus that such cases should be considered variants of PBC and not part of the spectrum of AIH (94-98). Features of AIH, notably elevations in serum immunoglobulin G, the presence of ANA and/or SMA, and histological evidence of interface hepatitis of varying severity, occur quite frequently in PSC (especially in children) (99-102). However, at least in adults, very few patients have combinations of these features with sufficient severity to qualify for a diagnosis of definite AIH (103). The possibility that such patients may have both AIH and PSC cannot be excluded.

Analysis of published data on the application of the Brighton report criteria in nearly 1000 patients revealed that the diagnostic scoring system had an overall diagnostic

accuracy of 89.8%, with a sensitivity of 98.0% (71). Specificity for excluding definite AIH in patients with chronic viral hepatitis and circulating autoantibodies or overlapping cholestatic syndromes was also high at 98% to 100%, but specificity for excluding probable AIH in these disorders ranged from only 60% to 80%. This was due partly to inappropriate weighting against moderate elevations in alkaline phosphatase levels and histological evidence of bile duct damage. Modifications made to the scoring system have increased specificity for excluding definite or probable AIH in PSC to 89.5% (71). However, it is stressed that this system is designed mainly for research purposes, to facilitate the selection of relatively homogeneous groups of patients for clinical trials and other studies, and that aggregate scores do not reflect severity of disease.

Finally, the review has reaffirmed that patient response to immunosuppressive therapy is characteristic of AIH, and that it is appropriate to take this into account. However, it is noted that response is dependent on patient compliance with treatment (which can be difficult to monitor) and that some patients (especially those who present acutely) may not respond very well to standard therapy (corticosteroids with or without azathioprine). Thus, a poor response should not necessarily exclude AIH. Nonetheless, it is recommended that cholangiography be performed in all patients with suspected AIH who do not show a satisfactory response to corticosteroids (71). The review stressed that the recommended criteria apply only to features at presentation, before institution of therapy, and that assessment of treatment response is used only to reinforce the diagnosis. Time will tell whether the amended 'Brighton criteria' arising from this review will provide the much needed 'gold standard' for the diagnosis of AIH.

## REFERENCES

- Ludwig J, McFarlane IG, Rakela J. International Working Party: Terminology of chronic hepatitis. *Am J Gastroenterol* 1995;90:181-9.
- Cullinan ER. Idiopathic jaundice (often recurrent) associated with subacute necrosis of the liver. *St Barthol Hosp Rep* 1936;69:55-142.
- Amberg S. Hyperproteinemia associated with severe liver damage. *Proc Staff Meet Mayo Clin* 1942;17:360-2.
- Wood IJ, King WE, Parsons PJ, et al. Non-suppurative hepatitis: a study of acute and chronic forms with special reference to biochemical and histological changes. *Med J Aust* 1948;11:249-61.
- Waldenstrom J. Leber, blutproteine und Nahrungsweiss. *Deutsch Gesellschaft Z Verdau Stoffwechselkr* 1950;15:113-9.
- Bongiovanni AM, Eisenmenger WJ. Adrenal cortical metabolism in chronic liver disease. *J Clin Endocrinol* 1951;11:152-72.
- Saint EG, King WE, Joske RA, et al. The course of infectious hepatitis with special reference to prognosis and chronic stage. *Aust Ann Med* 1953;2:113-27.
- Wilcox RG, Isselbacher KJ. Chronic liver disease in young people. Clinical features and course of thirty-three patients. *Am J Med* 1961;30:185-95.
- Mistilis SP, Skyring AP, Blackburn CRB. Natural history of active chronic hepatitis. *Aust Ann Med* 1968;17:214-23.
- Soloway RD, Summerskill WHJ, Baggenstoss AH, et al. Clinical, biochemical and histological remission of severe chronic active liver disease: a controlled study of treatments and early prognosis. *Gastroenterology* 1972;63:820-33.
- Joske RA, King WE. The LE cell phenomenon in active chronic viral hepatitis. *Lancet* 1955;iii:477-80.
- Eaton MD, Murphy WD, Hanford VL. Heterogeneous antibodies in acute hepatitis. *J Exp Med* 1944;79:539-57.
- Zimmerman HJ, Heller P, Hill RP. Extreme hyperglobulinemia in subacute hepatic necrosis. *N Engl J Med* 1951;244:245-9.
- Mackay IR, Taft LI, Cowling DC. Lupoid hepatitis. *Lancet* 1956;ii:1323-6.
- Mackay IR, Taft LI, Cowling DC. Lupoid hepatitis and the hepatic lesions of systemic lupus erythematosus. *Lancet* 1959;i:65-9.
- Gadjusek DC. An "autoimmune" reaction against human tissue antigens in certain acute and chronic diseases: I. Serological investigations. *Arch Intern Med* 1958;101:9-29.
- Mackay IR, Gadjusek DC. An "autoimmune" reaction against human tissue antigens in certain acute and chronic diseases: II. Clinical correlations. *Arch Intern Med* 1958;101:30-46.
- Holborow EJ, Asherson GL, Johnson GD, Barnes RDS, Carmichael PS. Antinuclear factor and other antibodies in blood and liver diseases. *Br Med J* 1963;i:656-8.
- Johnson GD, Holborow EJ, Glynn LE. Antibody to smooth muscle in patients with liver disease. *Lancet* 1965;ii:878-9.
- Whittingham S, Irwin J, Mackay IR, Smalley M. Smooth muscle autoantibody in 'autoimmune' hepatitis. *Gastroenterology* 1966;51:499-505.
- Last PM. The treatment of active chronic infectious hepatitis with ACTH (corticotrophin) and cortisone. *Med J Aust* 1957;i:672-6.
- Mackay IR, Weiden S, Ungar B. The treatment of active chronic hepatitis and lupoid hepatitis with 6-mercaptopurine and azathioprine. *Lancet* 1964;i:889-902.
- Copenhagen study group for liver diseases. Effect of prednisolone on the survival of patients with cirrhosis of the liver. *Lancet* 1969;ii:119-21.

24. Cook GC, Mulligan R, Sherlock S. Controlled prospective trial of corticosteroid therapy in active chronic hepatitis. *Q J Med* 1971;40:159-85.
25. Soloway RD, Summerskill WHJ, Baggenstoss AH, et al. Clinical, biochemical and histological remission of severe chronic active liver disease: a controlled trial of treatments and early prognosis. *Gastroenterology* 1972;63:820-33.
26. Murray-Lyon IM, Stern RB, Williams R. Controlled trial of prednisone and azathioprine in active chronic hepatitis. *Lancet* 1973;i:735-7.
27. Mackay IR, Weiden S, Hasker J. Autoimmune hepatitis. *Ann NY Acad Sci* 1965;124:767-80.
28. Eddleston ALWF, Williams R. Inadequate antibody response to HBAg or suppressor T-cell defect in development of active chronic hepatitis. *Lancet* 1974;ii:1543-5.
29. Mackay IR, Morris PJ. Association of autoimmune active hepatitis with HLA-A1.8. *Lancet* 1972;ii:793-5.
30. Opelz G, Vogten AGM, Summerskill WHJ, Schalm SW, Terasaki PI. HLA determinant in chronic active liver disease: A possible relation of HLA-Dw3 to prognosis. *Tissue Antigens* 1977;9:36-40.
31. Seki T, Kiyosawa K, Inoko H, Ota M. Association of autoimmune hepatitis with HLA Bw54 and DR4 in Japanese patients. *Hepatology* 1990;12:1300-4.
32. Donaldson PT, Doherty DG, Hayllar KM, McFarlane I, Johnson PJ, Williams R. Susceptibility to autoimmune chronic active hepatitis: Human leukocyte antigens DR4 and A1-B8-DR3 are independent risk factors. *Hepatology* 1991;13:701-6.
33. Toda G. Immunogenetics of autoimmune hepatitis in Japanese. In: McFarlane IG, Williams R, eds. *Molecular Basis of Autoimmune Hepatitis*. Austin: RG Landes, 1996:129-41.
34. Donaldson PT, Albertini RJ, Krawitt EL. Immunogenetic studies of autoimmune hepatitis and primary sclerosing cholangitis. In: Krawitt EL, Wiesner RH, Nishioka M, eds. *Autoimmune Liver Diseases*, 2nd edn. Amsterdam: Elsevier, 1998:141-65.
35. Czaja AJ. Clinical aspects of autoimmune hepatitis in North America. In: Nishioka M, Toda G, Zeniya M, eds. *Autoimmune Hepatitis*. Amsterdam: Elsevier, 1994:27-43.
36. Ohta Y, Onji M. Clinical characteristics of autoimmune hepatitis in Japan. In: Nishioka M, Toda G, Zeniya M, eds. *Autoimmune Hepatitis*. Amsterdam: Elsevier, 1994:45-53.
37. Galbraith RM, Eddleston ALWF, Williams R, et al. Enhanced antibody responses in active chronic hepatitis: Relation to HLA-B8 and HLA-B12 and porto-systemic shunting. *Lancet* 1976;i:930-4.
38. Nouri-Aria KT, Hegarty JE, Alexander GJM, Eddleston ALWF, Williams R. Effect of corticosteroids on suppressor-cell activity in "autoimmune" and viral chronic active hepatitis. *N Engl J Med* 1982;307:1301-4.
39. Nouri-Aria KT, Hegarty JE, Alexander GJM, Eddleston ALWF, Williams R. IgG production in "autoimmune" chronic active hepatitis. Effect of prednisolone on T and B lymphocyte function. *Clin Exp Immunol* 1985;61:290-6.
40. Nouri-Aria KT, Donaldson PT, Hegarty JE, Eddleston ALWF, Williams R. HLA A1-B8-DR3 and suppressor cell function in first-degree relatives of patients with autoimmune chronic active hepatitis. *J Hepatol* 1985;1:235-41.
41. Vergani D, Wells L, Larcher VF, et al. Genetically determined low C4: a predisposing factor to autoimmune chronic active hepatitis. *Lancet* 1985;ii:294-8.
42. O'Brien CJ, Vento S, Donaldson PT, et al. Cell-mediated immunity and discrete suppressor T-cell defects to liver-derived antigens in families of patients with autoimmune chronic active hepatitis. *Lancet* 1986;i:350-3.
43. Scully LJ, Toze C, Sengar DPS, Goldstein R. Early-onset autoimmune hepatitis is associated with a C4 gene deletion. *Gastroenterology* 1993;104:1478-84.
44. Doherty DG, Underhill JA, Donaldson PT, et al. Polymorphisms in the human complement C4 genes and genetic susceptibility to autoimmune hepatitis. *Autoimmunity* 1994;18:243-9.
45. Czaja AJ. Autoimmune chronic active hepatitis. In: Czaja AJ, Dickson ER, eds. *Chronic Active Hepatitis, The Mayo Clinic Experience*. New York: Marcel Dekker, 1986:105-26.
46. Johnson PJ, McFarlane IG, Eddleston ALWF. The natural course and heterogeneity of autoimmune-type chronic active hepatitis. *Semin Liver Dis* 1991;11:187-96.
47. McFarlane IG. Clinical spectrum and heterogeneity of autoimmune hepatitis: an overview. In: Meyer zum Buschenfelde K-H, Hoofnagle JH, Manns M, eds. *Immunology and Liver*. London: Kluwer, 1992:179-92.
48. Choo QL, Kuo G, Weiner AJ, et al. Isolation of a cDNA clone derived from a blood-borne non-A, non-B viral hepatitis genome. *Science* 1989;244:359-62.
49. Kuo G, Choo QL, Alter HJ, et al. An assay for circulating antibodies to a major etiologic virus of human non-A, non-B hepatitis. *Science* 1989;244:362-4.
50. McFarlane IG. Autoimmunity and hepatotropic viruses. *Semin Liver Dis* 1991;11:223-33.
51. Magrin S, Craxi A, Fiorentino G, et al. Is autoimmune hepatitis a HCV-related disease? *J Hepatol* 1991;13:56-60.
52. Lenzi M, Johnson PJ, McFarlane IG, et al. Antibodies to hepatitis C virus in autoimmune liver disease: evidence for geographical heterogeneity. *Lancet* 1991;338:277-80.
53. Abuaf N, Lunel F, Giral P, et al. Non-organ specific autoantibodies associated with chronic C virus hepatitis. *J Hepatol* 1993;18:359-64.
54. Kawamoto H, Skaguchi K, Takaki A, Ogawa S, Tsuji T. Autoimmune responses as assessed by hypergammaglobulinaemia and the presence of autoantibodies in patients with chronic hepatitis C. *Acta Med Okayama* 1993;47:305-10.
55. Fried MW, Draguescu JO, Shindo M, et al. Clinical and serological differentiation of autoimmune hepatitis and hepatitis C virus-related chronic hepatitis. *Dig Dis Sci* 1993;38:631-6.
56. Schvarz R, Glaumann H, Weiland O. Survival and histological resolution of fibrosis in patients with autoimmune chronic active hepatitis. *J Hepatol* 1993;18:15-23.
57. Roberts SK, Thorneau TM, Czaja AJ. Prognosis of histological cirrhosis in type 1 autoimmune hepatitis. *Gastroenterology* 1996;110:848-57.
58. Krogsgaard K. Does corticosteroid pretreatment enhance the effect of alpha interferon treatment in chronic hepatitis B? *J Hepatol* 1994;20:159-62.
59. Magrin S, Craxi A, Fabiano C, et al. Hepatitis C viremia in chronic liver disease: relationship to interferon-alpha or corticosteroid treatment. *Hepatology* 1994;19:273-9.
60. Schapiro GD, Friedman LS. Autoimmune hepatitis and/or hepatitis C: How to decide. *Hepatology* 1996;23:647-9.
61. Deutsch M, Dourakis S, Manesis EK, et al. Thyroid abnormalities in chronic viral hepatitis and their relationship to interferon alpha therapy. *Hepatology* 1997;26:206-10.
62. Black M, Peters M. Alpha-interferon treatment of chronic hepatitis C: Need for accurate diagnosis in selecting patients. *Ann Intern Med* 1992;116:86-8.
63. Homborg J-C, Abuaf N, Bernard O, et al. Chronic active hepatitis associated with anti-liver/kidney microsome antibody type 1: A second type of "autoimmune" hepatitis. *Hepatology* 1987;7:1333-9.
64. Johnson PJ, McFarlane IG, McFarlane BM, Williams R. Autoimmune features in patients with idiopathic chronic active hepatitis who are seronegative for conventional auto-antibodies. *J Gastroenterol Hepatol* 1990;5:244-51.
65. Czaja AJ, Carpenter HA, Santrach PJ, Moore SB, Homburger HA. The nature and prognosis of severe cryptogenic chronic active hepatitis. *Gastroenterology* 1993;104:1755-61.
66. Johnson PJ, McFarlane IG. Meeting report: International autoimmune hepatitis group. *Hepatology* 1993;18:998-1005.
67. Mackay IR. Towards diagnostic criteria for autoimmune hepatitis. *Hepatology* 1993;18:1006-8.
68. Gordon SC. Diagnostic criteria, clinical manifestations and natural history of autoimmune hepatitis. In: Krawitt EL, Wiesner RH, Nishioka M, eds. *Autoimmune Liver Diseases*, 2nd edn. Amsterdam: Elsevier, 1998:343-60.
69. Hay JE, Czaja AJ, Rakela J, Ludwig J. The nature of unexplained chronic aminotransferase elevations of a mild to moderate degree in asymptomatic patients. *Hepatology* 1989;9:193-7.
70. Nikias GA, Batta KP, Czaja AJ. The nature and prognostic implications of autoimmune hepatitis with an acute presentation. *J Hepatol* 1994;22:866-71.
71. International autoimmune hepatitis group report: review of criteria for diagnosis of autoimmune hepatitis. *J Hepatol* 1999;31:929-38.
72. McFarlane IG. The relationship between autoimmune markers and different clinical syndromes in autoimmune hepatitis. *Gut* 1998;42:599-602.
73. Parker DR, Kingham JGC. Type 1 autoimmune hepatitis is primarily a disease of later life. *Q J Med* 1997;90:289-96.

74. Toda G, Zeniya M, Watanabe F, et al. Present status of autoimmune hepatitis in Japan – correlating the characteristics with international criteria in an area with a high rate of HCV infection. *J Hepatol* 1997;26:1207-12.
75. Newton JL, Burt AD, Park JB, Mathew J, Bassendine MF, James OF. Autoimmune hepatitis in older patients. *Age Ageing* 1997;26:441-4.
76. Czaja AJ, Cassani F, Cataleta M, Valentini P, Bianchi FB. Frequency and significance of antibodies to actin in type 1 autoimmune hepatitis. *Hepatology* 1996;24:1068-73.
77. Chen M, Shirai M, Czaja AJ, et al. Characterisation of anti-histone antibodies in patients with type 1 autoimmune hepatitis. *J Gastroenterol Hepatol* 1998;19:483-9.
78. Czaja AJ, Cassani F, Cataleta M, Valentini P, Bianchi FB. Antinuclear antibodies and patterns of nuclear immunofluorescence in type 1 autoimmune hepatitis. *Dig Dis Sci* 1997;42:1688-96.
79. Hardarson S, La Brecque DR, Mitros FA, Neil GA, Goeken JA. Antineutrophil cytoplasmic antibody in inflammatory bowel and hepatobiliary diseases: High prevalence in ulcerative colitis, primary sclerosing cholangitis, and autoimmune hepatitis. *Clin Microbiol Immunol* 1993;99:277-81.
80. Mulder AHL, Horst G, Haagsma EB, Limburg PC, Kleibeuker JH, Kallenberg CGM. Prevalence and characterization of neutrophil cytoplasmic antibodies in autoimmune liver disease. *Hepatology* 1993;17:411-7.
81. Vidrich A, Lee J, James E, Cobb L, Targan S. Segregation of pANCA antigenic recognition by DNase treatment of neutrophils: Ulcerative colitis, type 1 autoimmune hepatitis and primary sclerosing cholangitis. *J Clin Immunol* 1995;15:293-9.
82. Targan SR, Landers C, Vidrich A, Czaja AJ. High-titer antineutrophil cytoplasmic antibodies in type-1 autoimmune hepatitis. *Gastroenterology* 1995;108:1159-66.
83. Zauli D, Ghetti S, Grassi A, et al. Anti-neutrophil cytoplasmic antibodies in type 1 and 2 autoimmune hepatitis. *Hepatology* 1997;25:1105-7.
84. Gregorio GV, Portmann B, Reid F, et al. Autoimmune hepatitis in childhood: a 20-year experience. *Hepatology* 1997;25:541-7.
85. Czaja AJ, Carpenter HA, Manns MP. Antibodies to soluble liver antigen, P450IID6, and mitochondrial complexes in chronic hepatitis. *Gastroenterology* 1993;105:1522-8.
86. Heringlake S, Tillman HL, Cordes-Temme P, Trautwein C, Hunsmann G, Manns MP. GBV-C/HGV is not the major cause of autoimmune hepatitis. *J Hepatol* 1996;25:980-4.
87. Gerken G. Distinction between autoimmune and viral liver diseases. In: Berg P, Löhse AW, Tiegs G, Wendel A, eds. *Autoimmune Liver Disease*. London: Kluwer, 1997:86-92.
88. Ichijo T, Nakatsuji Y, Tanaka E, et al. Autoimmune hepatitis type 1 without evidence of hepatitis G virus infection. *Int Hepatol Commun* 1997;6:219-24.
89. Calleja JL, Albillos A, Cacho G, Abreu L, Esartin P. Interferon and prednisone therapy in chronic hepatitis C with non-organ-specific antibodies. *J Hepatol* 1996;24:308-12.
90. Gregorio GV, Jones H, Choudhuri K, et al. Autoantibody prevalence in chronic hepatitis B virus infection: effect of interferon alpha. *Hepatology* 1996;24:520-3.
91. Cassani F, Cataleta M, Valentini P, et al. Serum autoantibodies in chronic hepatitis C: Comparison with autoimmune hepatitis and impact on disease profile. *Hepatology* 1997;26:561-6.
92. Gregorio GV, Pensati P, Iorio R, Vegnente A, Mieli-Vergani G, Vergani D. Autoantibody prevalence in children with liver disease due to chronic hepatitis C virus (HCV) infection. *Clin Exp Immunol* 1998;112:471-6.
93. Dalekos GN, Wedemeyer H, Obermayer-Straub P, et al. Epitope mapping of cytochrome P450D6 autoantigen in patients with chronic hepatitis C during  $\alpha$ -interferon therapy. *J Hepatol* 1999;30:366-75.
94. Goodman ZD, McNally PR, Davis DR, Ishak KG. Autoimmune cholangitis. A variant of primary biliary cirrhosis: clinicopathological and serologic correlations in 200 cases. *Dig Dis Sci* 1995;40:1232-42.
95. Inverizzi P, Crosignani A, Battezzati PM, et al. Comparison of the clinical features and clinical course of antimitochondrial antibody-positive and -negative primary biliary cirrhosis. *Hepatology* 1997;25:1090-5.
96. Kim WR, Poterucha JJ, Jorgensen RA, et al. Does antimitochondrial antibody status affect response to treatment in patients with primary biliary cirrhosis? Outcomes of ursodeoxycholic acid therapy and liver transplantation. *Hepatology* 1997;26:22-6.
97. Heathcote J. Overlap syndromes of autoimmune hepatitis, primary biliary cirrhosis and primary sclerosing cholangitis. In: Krawitt EL, Wiesner RH, Nishioka M, eds. *Autoimmune Liver Disease*, 2nd edn. Elsevier, Amsterdam, 1998:449-56.
98. Kinoshita H, Omagari K, Whittingham S, et al. Autoimmune cholangitis and primary biliary cirrhosis – an autoimmune enigma. *Liver* 1999;19:122-8.
99. Wilschanski M, Chait P, Wade JA, et al. Primary sclerosing cholangitis in 32 children: clinical, laboratory, and radiographic features, with survival analysis. *Hepatology* 1995;22:1415-22.
100. Protzer U, Dienes HP, Bianchi L, et al. Post infantile giant cell hepatitis in patients with primary sclerosing cholangitis and autoimmune hepatitis. *Liver* 1996;16:274-82.
101. Mieli-Vergani G, Vergani D. Autoimmune hepatitis in children. In: Krawitt EL, Wiesner RH, Nishioka M, eds. *Autoimmune liver diseases*, 2nd edn. Amsterdam: Elsevier, 1998:425-32.
102. Roberts EA. Primary sclerosing cholangitis in children. In: Krawitt EL, Wiesner RH, Nishioka M, eds. *Autoimmune liver diseases*, 2nd edn. Amsterdam: Elsevier, 1998:433-47.
103. Boberg KM, Fausa O, Haaland T, et al. Features of autoimmune hepatitis in primary sclerosing cholangitis: an evaluation of 114 primary sclerosing cholangitis patients according to a scoring system for the diagnosis of autoimmune hepatitis. *Hepatology* 1996;23:1369-76.



