Endoscopic evaluation of the small intestine

Steven J Shields MD[1], Jacques Van Dam MD PhD[2]

SJ Shields, J Van Dam. Endoscopic evaluation of the small intestine. Can J Gastroenterol 2002;16(3):178-183.

Technological achievements in the area of endoscope design and development have resulted in instruments capable of advancing beyond the reach of simple gastroscopes. Such instruments, known as enteroscopes, form the bases of small bowel endoscopy. Recent widespread use of enteroscopes have contributed significantly to the understanding of small intestinal pathology and improved the ability to diagnose and treat patients with intestinal bleeding sources.

Key Words: *Endoscopy; Intestinal bleeding*

Examen endoscopique de l'intestin grêle

RÉSUMÉ : Les progrès technologiques dans le domaine de l'endoscopie ont rendu possible la mise au point d'instruments capables de dépasser la portée des simples gastroscopes. Ces instruments, appelés entéroscopes, constituent la base de l'endoscopie de l'intestin grêle. L'utilisation récente mais répandue des entéroscopes a permis de comprendre beaucoup mieux les affections de l'intestin grêle, d'accroître la capacité de poser des diagnostics et de traiter de façon plus appropriée les patients présentant des hémorragies d'origine intestinale.

Until recently, patients suspected of having small intestinal pathology were evaluated primarily by contrast radiography, via either a single-contrast small bowel follow-through or a double-contrast enteroclysis (1,2). Radioisotope scans and angiography were also used, especially in patients suspected of having a bleeding source located in the small intestine (3). In general, however, the diagnostic yield of these methods was low.

Advances in the endoscopic examination of the small bowel have progressed slowly over the past 25 years. Using standard gastroscopes and side-viewing duodenoscopes, endoscopic visualization of the small intestine was limited to the most distal portions of the duodenum. In addition, portions of the terminal ileum could be visualized during colonoscopy. However, attempts to visualize the jejunum and proximal ileum more completely were restricted by technological limitations.

The 'rope-way method', originally reported in 1972 by Classen et al (4), was the first attempt at small bowel endoscopy . This method involved swallowing a guidestring

Division of Gastroenterology, [1]Brigham and Women's Hospital, Harvard Medical School, Boston, Massachusetts, and [2]Stanford University Medical Center, Stanford University School of Medicine, Stanford, California, USA
Correspondence and reprints: Dr Jacques Van Dam, Stanford University School of Medicine, Clinical Chief and Director of Endoscopy, Division of Gastroenterology and Hepatology, Stanford University Medical Center, Room H1121, Mail Code 5202, 300 Pasteur Drive, Stanford, California 94305, USA
Received for publication January 11, 2000. Accepted April 26, 2000

and allowing it to pass through the anus. The string was then exchanged for a stiffening tube, and a long endoscope was advanced over the stiffening tube either orally or transanally. Complete endoscopic visualization of the small intestine (and the remaining portions of the gastrointestinal tract) was possible using this method. The technique was time-consuming (between two and five days for the passage of the string), and painful due to the tightening and straightening of the string and guide tube during advancement of the endoscope. General anesthesia was often required to complete the procedure.

The next advance in the endoscopic evaluation of the small intestine was the use of the dedicated push enteroscope (5). First reported in 1973, the instrument was 162 cm in length and was reportedly capable of intubating up to 30 cm beyond the ligament of Treitz. Most push enteroscopy has not been performed using dedicated instruments but rather using standard colonoscopes, adult or pediatric (6). The depth of insertion using standard colonoscopes has been reported to be up to 50 to 60 cm beyond the ligament of Treitz. Advancements in video technology have led to several commercially available dedicated push enteroscopes. These have long insertion tubes, excellent tip deflection, and large accessory channels allowing both diagnostic and therapeutic interventions. The depth of insertion with dedicated enteroscopes has been reported to be up to 150 cm beyond the ligament of Treitz (7).

By 1977, Sonde enteroscopes were being used in clinical research (8). Sonde-type enteroscopes require peristalsis for passage from the proximal to distal small bowel. The first Sonde-type enteroscopes used a weighted metal hood to facilitate passage through the small bowel. Subsequent designs used an inflatable balloon at the tip of the scope to exploit peristaltic motion. Most Sonde enteroscopes are passed orally, although thinner models can be passed transnasally (9). Examination of the entire ileum and jejunum is possible. However, the main limitation of Sonde enteroscopy is the time required for the procedure. The original technique required an average of 12 to 24 h for completion. A more rapid technique involves endoscopically carrying the Sonde enteroscope into the small intestine as far distally as possible (10). This shortens the procedure time considerably, although the examination still requires 6 to 8 h to complete. The small bowel mucosa is visualized during slow withdrawal of the Sonde enteroscope. Readvancement of the Sonde instrument to visualize a suspicious or missed area is not practical. In addition, most Sonde enteroscopes lack full tip deflection and do not have an accessory channel for diagnostic or therapeutic applications.

Intraoperative enteroscopy is another method used to evaluate the small intestine (11). The procedure is typically performed with the assistance of an operating surgeon who either uses laparoscopic instruments to manipulate portions of the small intestine at laparoscopy or manually advances the enteroscope through the small intestine during laparotomy (12). This method has the potential to allow the entire length of the small intestine to be viewed and permit surgical resection when small intestinal pathology is discovered.

TABLE 1
Indications for small bowel enteroscopy

Occult gastrointestinal bleeding of obscure cause
Unexplained iron-deficiency anemia
Abnormal small bowel radiography
Unexplained chronic diarrhea or malabsorption
Evaluation of small bowel strictures
Screening for familial adenomatosis polyposis syndrome
Evaluation for Whipple's disease
Unexplained abdominal pain
Jejunal feeding tube insertion
Preoperative tattoo placement
Assisted enteroclysis
Assisted endoscopic retrograde cholangiopancreatography after creation of a Roux-en-Y limb

INDICATIONS

The typical indications for small bowel enteroscopy are listed in Table 1. The most common indication is the evaluation of the patient with chronic gastrointestinal bleeding of obscure origin. Obscure bleeding is usually defined as no identifiable cause of blood loss despite thorough diagnostic testing, including upper gastrointestinal endoscopy, colonoscopy and contrast radiography of the small bowel. Other common indications for small bowel enteroscopy include unexplained iron-deficiency anemia, unexplained chronic diarrhea, malabsorption and follow-up of an abnormal small bowel x-ray. Enteroscopy has been used in the evaluation of abdominal pain of undetermined cause, although the diagnostic yield is low due to the typical nonspecific nature of the symptoms.

TECHNIQUES

Push enteroscopy

Preparation for enteroscopy is the same as for routine upper endoscopy. Patients should fast for approximately 8 h before the examination – longer if there is known or suspected gastrointestinal dysmotility. Acetylsalicylic acid (ASA) and other nonsteroidal anti-inflammatory medications (NSAIDs) should be discontinued at least five days before the procedure, especially if a therapeutic intervention is anticipated. Prophylactic periprocedure antibiotics should be administered according to the same guidelines suggested for routine upper gastrointestinal endoscopy. Standard push enteroscopy is performed with the patient under conscious sedation. Medications typically include a benzodiazepine for sedation and, if necessary, a narcotic (eg, meperidine or fentanyl) for pain control.

If an overtube is used, it should be backloaded over the insertion tube using a generous amount of lubricant. The enteroscope is introduced in the same manner as any standard endoscope with the patient in the left lateral decubitus position. After the enteroscope is advanced into the distal duodenum or proximal jejunum, the instrument should be straightened, thereby removing the intragastric loop along the greater curvature of the stomach. If an overtube has been backloaded onto the enteroscope, it should be advanced carefully over the enteroscope while in the shortened, straight position. The overtube is intended to help prevent reformation of the intragastric loop, thereby allowing a potentially greater depth of insertion.

If excessive amounts of bile with its associated bubbles are encountered, simethecone can be administered into the small intestine via the accessory channel of the enteroscope. This should be done early in the procedure to optimize visualization of the small bowel mucosa during insertion of the enteroscope. Simethecone should also be used before administration of glucagon or other agents that inhibit intestinal peristaltic contractions.

The enteroscope is advanced as far distally into the small bowel as possible while attempting to maintain the patient's comfort. Deep penetration of the enteroscope may be achieved using a combination of manual insertion ('pushing') and a series of shortening manoeuvres, similar to those used during colonoscopy. The endoscopy assistant may provide manual pressure on the abdomen to facilitate additional advancement. The patient can also be repositioned as necessary. To negotiate difficult angles, it may be helpful to apply a continuous steady forward pressure on the enteroscope rather than making repeated movements back and forth with the instrument. The steady pressure technique is more effective if antiperistaltic medications are not administered during the insertion phase of the procedure. The peristaltic activity of the upper intestinal tract can assist passage around difficult bends by the propulsive nature of the contractions.

The use of fluoroscopy during small bowel enteroscopy has been recommended by some authors (13). Fluoroscopy aids in the monitoring of loop formation (and reformation) during insertion and allows a more accurate assessment of insertion depth. Fluoroscopy may be used during overtube placement to ensure successful positioning across the pylorus. While fluoroscopy is useful, it is not a required component of the procedure. Certainly, the procedure can be performed safely without it.

Mucosal inspection occurs primarily during withdrawal of the enteroscope. If arteriovenous malformations (AVMs) are suspected, careful inspection should be performed on insertion as well as on withdrawal. Inspection on insertion helps to reduce the potential misinterpretation of mucosal trauma caused by the enteroscope as being caused by an actual AVM.

The enteroscope is withdrawn in a slow, deliberate manner. Unlike Sonde enteroscopy, if a segment of suspicious mucosa moves by the tip of the enteroscope too quickly or a review of the area is desired, the segment can be recaptured by advancing the enteroscope. Antiperistaltic agents can be administered during the withdrawal phase of the procedure, if necessary. Mild rhythmic small bowel contractions may actually assist in a more thorough visualization of the mucosa; however, rapid, vigorous contractions impair visualization and slow the withdrawal process. Antiperistaltic agents may be especially useful during therapeutic interventions such as the electrocoagulation of AVMs. If an overtube is used, it should be withdrawn simultaneously with the enteroscope. Mucosal stripping is a reported complication of enteroscope withdrawal into a stationary overtube (13).

Sonde enteroscopy

Several different Sonde-type enteroscopes are available for commercial and research purposes. The main difference between the various devices is the diameter of the insertion tube, which determines whether the instrument can be passed orally or transnasally. A balloon attached to the distal end facilitates passive antegrade movement of the instrument during intestinal peristalsis. The 'piggyback' method of insertion expedites the insertion phase of the procedure. This method involves the insertion of a second endoscope to grasp a suture tied to the tip of the Sonde enteroscope to pull the Sonde instrument from the stomach into the small intestine as far distally as possible. Once in position within the small intestine, the balloon is inflated with approximately 12 to 20 cm^3 of air, and the second gastroscope may be removed. A promotility agent may be administered to assist in the distal passage of the instrument, although the benefits of promotility agents have not been shown clearly (14). Distal passage may take several hours to complete, which is important to discuss with the patient before the procedure. The patient is typically under mild conscious sedation during the insertion phase. The enteroscope should be gently advanced 10 to 20 cm into the stomach every 30 to 60 min to provide slack for distal passage. The patient is typically kept in the supine position during insertion. Progress of the enteroscope may be monitored fluoroscopically. The insertion phase is complete when the entire length of the enteroscope has been advanced into the patient or when failure to progress has been observed. Failed progression is usually defined as an unchanged fluoroscopic position after 1 to 2 h. One cause of a lack of progression may be overuse of sedative medications. Small bowel adhesions, tumours, strictures or areas of inflammation may also prevent advancement of the instrument. Enteroscopy-assisted enteroclysis may be used to visualize the portions of the intestinal tract distal to the tip of the enteroscope (15).

During the withdrawal phase, the patient is usually maintained in the supine position with knees bent. The balloon at the tip of the enteroscope should remain inflated to keep the endoscopic view centred in the lumen to optimize mucosal inspection. Air is insufflated into the lumen to aid inspection. The assistant may also manipulate the

endoscopic view by gentle palpation of the abdomen over the intestinal segment being visualized. Careful withdrawal is essential to reduce the likelihood of rapid retrograde sliding, which limits adequate visualization of the segment involved. This can successfully be accomplished by withdrawing the instrument slowly, palpating the abdoman gently, adjusting the patient's position and varying the amount of balloon inflation.

Withdrawal of the Sonde enteroscope typically requires 30 to 60 min. Despite traversing the entire length of the small bowel, Sonde enteroscopy has been estimated to allow visualization of only 50% to 80% of the small bowel mucosa (16). Factors contributing to the limited mucosal visualization include the inability to deflect the tip of the enteroscope, especially along the inner portions of curves, uncontrolled retrograde slides and the limited ability to readvance over a section not adequately examined. Until recently, most Sonde enteroscopes have not had an accessory channel, thus limiting both diagnostic and therapeutic capabilities. Some prototype instruments have attempted to add an accessory channel or tip deflection. However, these technological advances come at the expense of an increased scope diameter and/or loss of flexibility, which may impair distal migration (17).

Intraoperative enteroscopy

Virtually any endoscope may be used for intraoperative enteroscopy. In general, a long instrument with an accessory channel should be used. Originally, intraoperative enteroscopy was performed via a standard laparotomy incision. However, successful laparoscopically assisted enteroscopy has been reported (15). Using either method, the surgeon assists the endoscopist by pleating the small bowel onto the endoscope after each segment has been visualized and inspected for pathology. If the distal ileum cannot be reached, an enterotomy can be performed, after which a gas-sterilized endoscope can be inserted and manipulated distally. Therapeutic interventions for intraoperative enteroscopy include endoscopic measures and surgical resection when necessary.

FINDINGS

The diagnostic yield of small bowel enteroscopy varies depending on the indication for its use. Interestingly, many of the abnormalities found during enteroscopy are within reach of (and therefore can be diagnosed by) a standard gastroscope (Table 2). As many as 20% to 60% of abnormalities found during enteroscopy have been located proximal to the second portion of the duodenum (13). Presumably, these endoscopic abnormalities were overlooked despite previous extensive investigation before referral for enteroscopy (Figures 1 and 2). Missed lesions have occurred more commonly in patients taking ASA or other NSAIDs. In a prospective study by Chak et al (18), 31 consecutive asymptomatic patients with iron-deficiency anemia and a negative colonoscopy underwent an upper gastrointestinal tract evaluation using an enteroscope. All patients were initially examined as though undergoing a standard esophagogastroduodenoscopy (EGD), albeit using the enteroscope. After completion of the EGD, the enteroscope was advanced as far as possible into the small bowel. Findings were recorded for both portions of the procedure. A bleeding source was identified during the EGD portion in 35% of patients; 26% had a bleeding source located only in the jejunum, and two patients (6%) had a bleeding source located in both the jejunum and the upper gastrointestinal tract. Cost analysis showed a substantial benefit of performing the EGD using the enteroscope and completing the endoscopic small bowel examination when the evaluation of the upper gastrointestinal tract was negative compared with performing an enteroscopy as a second procedure in patients only after a negative EGD had been performed using a gastroscope.

TABLE 2
Reported abnormalities within reach of a standard gastroscope, detected at small bowel enteroscopy

Recurrence of gastric adenocarcinoma
Duodenal stricture secondary to pancreatic cancer
Gastric and duodenal polyps
Hiatal hernia with erosions
Ulcerative esophagitis
Erosive gastritis
Gastric and duodenal ulcers
Arteriovenous malformations
Gastric antral vascular ectasia
Esophageal and gastric varices
Hypertensive portal gastropathy
Dieulafoy's lesion
Celiac sprue

The diagnostic yield of push enteroscopy for occult or obscure gastrointestinal bleeding varies from 26% to 80% (Table 3) (15,19-29). Several factors contribute to the reported differences, including dissimilar patient populations, the length of the small intestine examined, the use of an overtube, the manner in which investigators judged whether an abnormality represented a pathological lesion, and the frequency of use of ASA or other NSAIDs by the study patients.

AVMs are the lesions most commonly identified in the evaluation of patients with occult or obscure gastrointestinal bleeding, occurring in 70% of patients (Table 4). Small bowel tumours, considered to be a rare finding, are identified during enteroscopy in 4% to 5% of patients (Figure 3). The yield is substantially higher in patients with either familial adenomatous polyposis or familial juvenile polyposis (30,31). To examine areas of the small intestine that are distal to the reach of the push enteroscope, enteroclysis can be performed via the enteroscope by passing the entero-

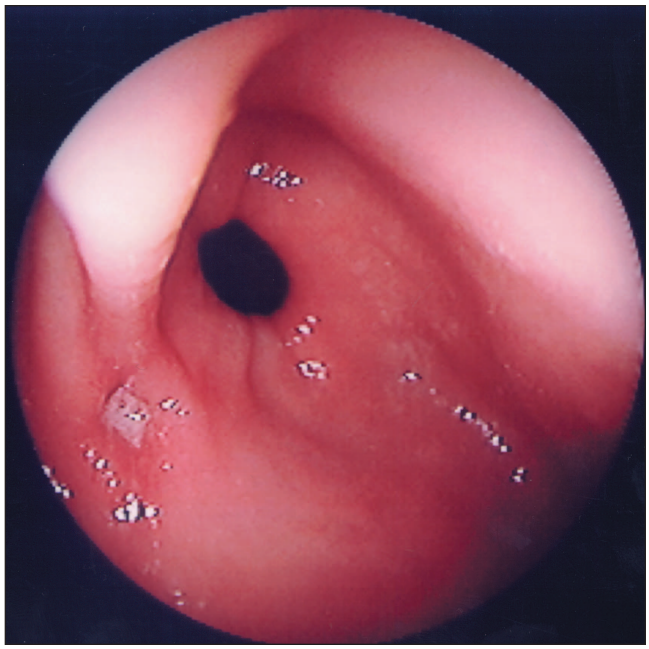

Figure 1) *Antral ulcer detected in a patient with obscure gastrointestinal bleeding referred for enteroscopy. The patient had undergone a 'negative' colonoscopy and an upper gastrointestinal endoscopy at another insitution before being referred for small bowel enteroscopy. There were no small bowel findings on enteroscopy*

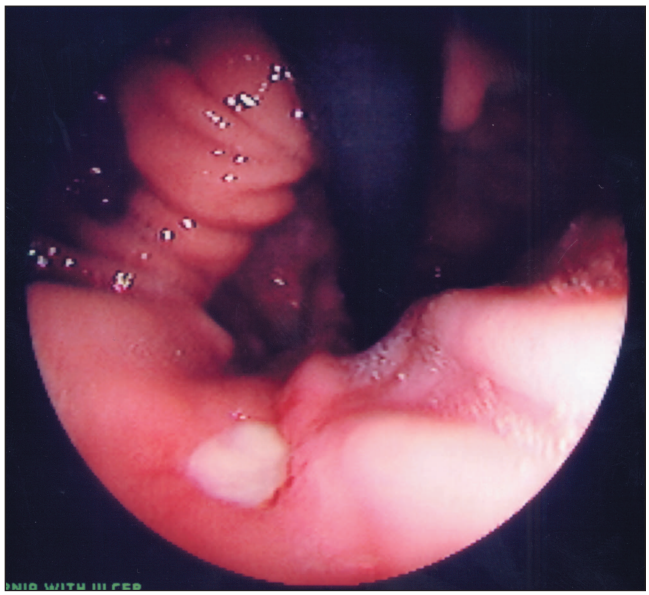

Figure 2) *Gastric ulcer detected on retroflexed view near the base of a large hiatal hernia in a patient with obscure gastrointestinal bleeding referred for enteroscopy. The patient had undergone a 'negative' colonoscopy and an upper gastrointestinal endoscopy at another insitution before being referred for small bowel enteroscopy. There were no small bowel findings on enteroscopy*

clysis catheter through the accessory channel and injecting contrast material under fluoroscopy. In one study evaluating the yield of enteroscopy-assisted enteroclysis, small bowel masses were detected in two of 24 (8%) patients undergoing enteroscopy for obscure gastrointestinal bleeding and in one of 10 (10%) patients undergoing enteroscopy for an abnormal radiographic study (15).

TABLE 3
Diagnostic yield of push enteroscopy for occult or obscure gastrointestinal bleeding

Author, year (reference)	Number of patients	Number of lesions	Yield (%)
Foutch et al, 1990 (19)	39	15	38
Rutgeerts et al, 1993 (20)	57	27	47
Harris et al, 1994 (21)	31	19	61
Barkin et al, 1994 (22)	20	16	80
Chong et al, 1994 (23)	55	35	64
Pennazio et al, 1995 (24)	20	9	45
Schmit et al, 1996 (25)	83	49	59
Willis et al, 1997 (15)	54	29	54
Vakil et al, 1997 (26)	29	18	62
Zaman and Katon, 1998 (27)	95	39	41
Landi et al, 1998 (28)	76	20	26
Chak et al, 1998 (29)	129	91	70
Sharma et al, 2000 (7)	21	9	48

TABLE 4
Lesions identified during push enteroscopy for the evaluation of occult or obscure gastrointestinal bleeding

Type of lesion	Cause
Vascular	Arteriovenous malformations, Dieulafoy's lesion, varices, portal hypertension, phlebectasias, blue rubber bleb nevi
Tumours	Adenoma, adenocarcinoma, lipoma, leiomyoma, leiomyosarcoma, carcinoid, lymphoma, hemangioma, hamartoma, Kaposi's sarcoma
Infiltrative	Amyloidosis, sarcoidosis, tuberculosis, myeloma
Miscellaneous	Celiac sprue, inflammatory bowel disease, Meckel's diverticulum, endometriosis, aortoenteric fistula, vasculitis, infectious enteritis

Enteroscopy has been used in the evaluation of diarrhea or steatorrhea of suspected small bowel origin. In such patients, findings at enteroscopy have included celiac sprue, tropical sprue, Crohn's disease, jejunal diverticulosis with bacterial overgrowth, radiation enteropathy, NSAID enteropathy, opportunistic infections (eg, cytomegalovirus), small bowel lymphoma (Figure 4), worms (eg, strongyloidiasis) and parasites (eg, giardiasis) (7,28,29,32). The diagnostic yield of push enteroscopy for chronic diarrhea has ranged from 22% to 40%. It is important to note that the macroscopic appearance of the small bowel mucosa may seem normal in some instances and that endoscopic mucosal biopsies are essential to exclude histological abnormalities.

Another important indication for enteroscopy is the evaluation of abnormalities detected on x-rays, including

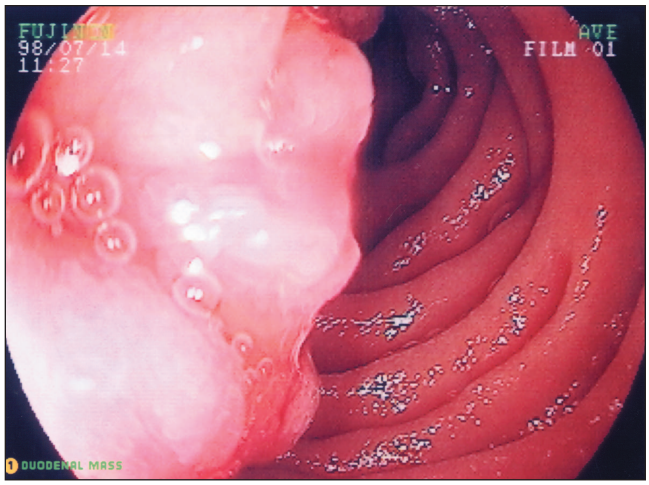

Figure 3) *Duodenal adenocarcinoma detected in a patient after a 'negative' single-contrast small bowel x-ray. The tumour had a distinctly 'villous' appearance at endoscopy. The patient did not have an underlying polyposis syndrome, and underwent endoscopic and radiographic evaluation for unexplained iron-deficiency anemia*

barium contrast examinations and abdominal computed tomography scans. In these circumstances, enteroscopy is useful for providing a histological diagnosis when an abnormality is discovered or for verifying the normal appearance of the bowel if a lesion is not found. Fluoroscopy during enteroscopy for this indication is especially useful because it helps to ensure that the instrument has reached the area of suspected abnormality. In addition to the identification of Crohn's disease, lymphoma, radiation enteritis and idiopathic jejunitis, enteroscopy for abnormal radiological studies has identified amyloidosis and leishmaniasis of the small bowel (28,32). The diagnostic yield of enteroscopy in this setting is quite high, approximately 55% to 60% (13,32).

The routine use of enteroscopy for the evaluation of unexplained abdominal pain should be discouraged. The diagnostic yield tends to be very low. In one report of 12 patients undergoing push enteroscopy, the diagnostic yield was 0%, although peritoneal carcinomatosis was subsequently diagnosed in one of the 12 patients at exploratory surgery (28). Positive findings, including duodenal strictures (secondary to lymphoma and pancreatic cancer) and recurrent adenocarcinoma at the gastrojejunal anastomosis, have been reported (32).

THERAPEUTIC ENTEROSCOPY

The therapeutic applications of enteroscopy are listed in Table 5. The push enteroscope can be used to access long afferent Billroth II limbs or Roux-en-Y limbs to assist in performing endoscopic retrograde cholangiopancreatography (33). Direct endoscopic placement of jejunal feeding tubes has also been reported (34). However, the most common therapeutic application is hemostasis via electrocoagulation (heater probe, BiCAP probe, laser) or injection therapy. Enteroscopic treatment of bleeding small intestinal angiodysplasia has been shown to reduce the requirement

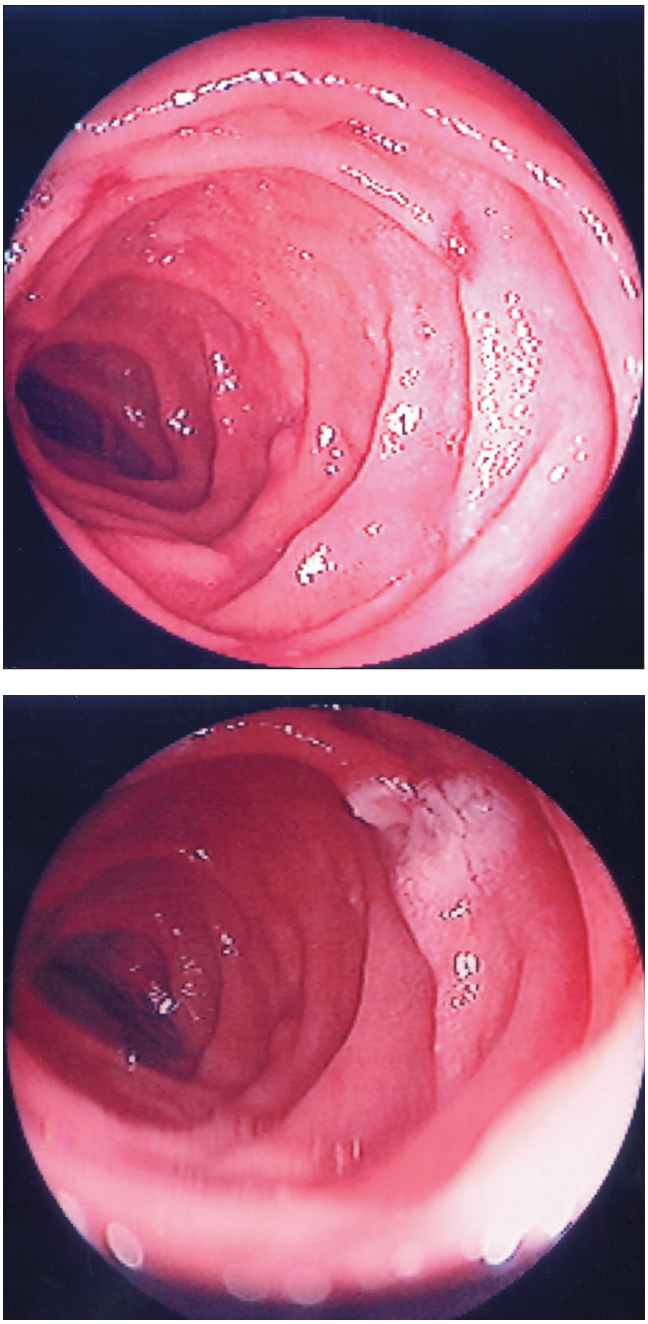

Figure 4) *Small intestinal lymphoma detected on enteroscopy in a patient with iron-deficiency anemia and diarrhea*

TABLE 5
Therapeutic applications of enteroscopy

Electrocoagulation for hemostasis
Endoscopic laser therapy for hemostasis
Injection therapy for hemostasis
Polypectomy
India ink tattoo marking
Enteroscopic-assisted endoscopic retrograde cholangiopancreatography
Direct percutaneous endoscopic jejunostomy placement
Dilation of strictures

for blood transfusion, improve hemoglobin levels, and improve functional status and quality of life significantly (35-37). In one study, endoscopic hemostasis in the small intestine via enteroscopy resulted in a decrease in transfusion requirement from 2.40 units of blood per month before treatment to 0.32 units per month after treatment (P<0.0001) (35). In another study, enteroscopic treatment of AVMs resulted in a greater than 50% reduction in the average number of transfusions required in the year following treatment, while 31% of patients required no transfusions in the year following treatment (37).

COMPLICATIONS OF SMALL BOWEL ENTEROSCOPY

The complications associated with diagnostic enteroscopy are essentially the same as those encountered during routine upper endoscopy, including pharyngeal trauma, aspiration, adverse reaction to the medications used during conscious sedation, and perforation of the esophagus, stomach or small intestine. Therapeutic interventions during enteroscopy may increase the risk of perforation, bleeding or infectious complications. Intraoperative enteroscopy may result in prolonged postprocedural ileus (38). Most of the reported complications of push enteroscopy have been related to the use of the overtube. These have included pharyngeal tears, Mallory-Weiss tears, perforation of the esophagus, acute pancreatitis presumably due to ampullary trauma, duodenal perforation and mucosal stripping with hemorrhage (13,39,40). Overtube trauma appears to be related to the space between the enteroscope and the overtube, with the potential for tissue entrapment during overtube insertion over the enteroscope or upon enteroscope withdrawal into the overtube. The risk can be limited using an overtube with a diameter as close to that of the enteroscope as possible, advancing the overtube over a Maloney dilator as described by Goldschmiedt et al (41) and retracting the overtube before withdrawal of the enteroscope. Some authors do not advocate the use of an overtube during push enteroscopy (13). However, published data suggest that the overtube assists in deeper insertion of the enteroscope by limiting intragastric and intraduodenal looping during advancement of the enteroscope. In a study comparing the mean lengths of insertion when the procedure was performed with or without an overtube, the distance of the enteroscope insertion past the ligament of Treitz was only 11 cm without an overtube compared with 108 cm with an overtube (42). Thus, the use of an overtube seems to facilitate the performance of the procedure.

REFERENCES

1. Rabe FE, Becker GJ, Besozzi MJ, Miller RE. Efficacy study of the small bowel examination. Radiology 1981;140:47-50.
2. Rex DK, Lappas JC, Maglinte DDT, Malczewski MC, Kopecky KA, Cockerill EM. Enteroclysis in the evaluation of suspected small intestinal bleeding. Gastroenterology 1989;97:58-60.
3. Szasz IJ, Morrison RT, Lyster DM. Technetium – 99m labelled red blood cell scanning to diagnose occult gastrointestinal bleeding. Can J Surg 1985;28:512-4.
4. Classen M, Fruhmergen P, Koch H. Peroral enteroscopy of the small and large intestine. Endoscopy 1972;4:157.
5. Ogoshi K, Hara Y, Ashizawa S. New technique for small intestinal fiberoscopy. Gastrointest Endosc 1973;20:64.
6. Parker H, Agayoff J. Enteroscopy and small bowel biopsy utilizing a peroral colonoscope. Gastrointest Endosc 1983;29:139-40.
7. Sharma BC, Bhasin DK, Makharia G, et al. Diagnostic yield of push-type enteroscopy: a review from India. Am J Gastroenterol 2000;95:137-40.
8. Tada M, Akasaka Y, Misaki F, Kawai K. Clinical evaluation of a Sonde-type small intestinal fiber scope. Endoscopy 1977;8:33-8.
9. Tada M, Shimizu S, Kawai K. A new transnasal Sonde-type fiberoscope (SSIF VII) as a pan-enteroscope. Endoscopy 1986;18:121-4.
10. Lewis B, Waye JD. Total small bowel enteroscopy. Gastrointest Endosc 1987;33:435-8.
11. Desa L, Ohri S, Hutton K, et al. Role of intra-operative enteroscopy in obscure gastrointestinal bleeding of small bowel origin. Br J Surg 1991;78:192-5.
12. Zaman A, Sheppard B, Katon RM. Total peroral intraoperative enteroscopy for obscure GI bleeding using a dedicated push enteroscope: diagnostic yield and patient outcome. Gastrointest Endosc 1999;50:506-10.
13. Waye JD. Enteroscopy. Gastrointest Endosc 1997;46:247-56.
14. Goldstein S. The use of erythromycin and metaclopramide to facilitate the passage of the Sonde small bowel enteroscope. Gastrointest Endosc 1994;40:21.
15. Willis JR, Chokshi HR, Zuckerman GR, Aliperti A. Enteroscopy-enteroclysis: Experience with a combined endoscopic-radiographic technique. Gastrointest Endosc 1997;45:163-7.
16. Seensalu R. The Sonde examination. Gastrointest Endosc Clin N Am 1999;9:37-59.
17. Lewis BS. Enteroscopy. Gastrointest Endosc Clin N Am 2000;10:101-16.
18. Chak A, Cooper GS, Canto MI, Pollack BJ, Sivak MV. Enteroscopy for the initial evaluation of iron deficiency. Gastrointest Endosc 1998;47:144-8.
19. Foutch P, Sawyer R, Sanowski RA. Push-enteroscopy for diagnosis of patients with gastrointestinal bleeding of obscure origin. Gastrointest Endosc 1990;36:337-41.
20. Rutgeerts P, Broeckaert L, Willemse P, et al. Push enteroscopy has a higher yield for the diagnosis of the source of occult bleeding than Sonde-type enteroscopy. Gastrointest Endosc 1993;39:257.
21. Harris A, Dabezies M, Catalano M, et al. Early experience with a video push enteroscope. Gastrointest Endosc 1994;40:62-4.
22. Barkin JS, Chong J, Reiner DK. First-generation video enteroscope: fourth generation push-type small bowel enteroscopy using an overtube. Gastrointest Endosc 1994;40:743-7.
23. Chong J, Tagle M, Barking J, et al. Small bowel push-type fiberoptic enteroscopy for patients with occult gastrointestinal bleeding or suspected small bowel pathology. Am J Gastroenterol 1994;89:243-6.
24. Pennazio M, Arrigoni A, Risio M, et al. Clinical evaluation of push enteroscopy. Endoscopy 1995;27:164-70.
25. Schmit A, Gay F, Adler M, Cremer M, Gossum AV. Diagnostic efficacy of push-enteroscopy and long-term follow-up of patients with small bowel angiodysplasias. Dig Dis Sci 1996;41:2348-52.
26. Vakil N, Huilgol V, Khan I. Effect of push enteroscopy on transfusion requirements and quality of life in patients with unexplained gastrointestinal bleeding. Am J Gastroenterol 1997;92:425-8.
27. Zaman A, Katon RM. Push enteroscopy for obscure gastrointestinal bleeding yields a high incidence of proximal lesions within reach of a standard endoscope. Gastrointest Endosc 1998;47:372-6.
28. Landi B, Tkoub M, Gaudric M, et al. Diagnostic yield of push-type enteroscopy in relation to indication. Gut 1998;42:421-5.
29. Chak A, Koehler MK, Sundaram SN, Cooper GS, Canto MI, Sivak MV. Diagnostic and therapeutic impact of push enteroscopy: analysis of factors associated with positive findings. Gastrointest Endosc 1998;47:18-22.

30. Rodriguez- Bigas MA, Penetrante RB, Herrera L, Petrilli NJ. Intraoperative small bowel enteroscopy in familial adenomatous and familial juvenile polyposis. Gastrointest Endosc 1995;42:560-4.
31. Pennazio M, Arrigoni A, Rossini FP. Enteroscopic identification of adenocarcinoma of the small bowel in a patient with previously unrecognized hereditary nonpolyposis colorectal cancer syndrome. Am J Gastroenterol 1999;94:1962-6.
32. Davies GR, Benson MJ, Gertner DJ, Van Someren RMN, Rampton DS, Swain CP. Diagnostic and therapeutic push type enteroscopy in clinical use. Gut 1995;37:346-52.
33. Gostout CJ, Bender CE. Cholangiopancreatography, sphincterotomy, and common duct stone removal via Roux-en-Y limb enteroscopy. Gastroenterology 1988;95:156-63.
34. Shike M, Latkany L, Gerdes H, Bloch AS. Direct percutaneous endoscopic jejunostomies for enteral feeding. Gastrointest Endosc 1996;44:536-40.
35. Askin MP, Lewis BS. Push enteroscopic cauterization: long-term follow-up of 83 patients with bleeding small intestinal angiodysplasia. Gastrointest Endosc 1996;43:580-3.
36. Morris AJ, Mokhashi M, Straiton M, Murray L, MacKenzie JF. Push enteroscopy and heater probe therapy for a small bowel bleeding. Gastrointest Endosc 1996;44:394-7.
37. Vakil N, Huilgol V, Khan I. Effect of push enteroscopy on transfusion requirements and quality of life in patients with unexplained gastrointestinal bleeding. Am J Gastroenterol 1997;92:425-8.
38. Lopez MJ, Cooley JS, Petros JG, Sullivan JG, Cave DR. Complete intraoperative small bowel endoscopy in the evaluation of occult gastrointestinal bleeding using the Sonde enteroscope. Arch Surg 1996;131:272-7.
39. Yang R, Laine L. Mucosal stripping: a complication of push enteroscopy. Gastrointest Endosc 1995;41:156-8.
40. Landi B, Cellier C, Fayemendy L, Cugnene PM, Barbier JP. Duodenal perforation occurring during push enteroscopy. Gastrointest Endosc 1996;43:631.
41. Goldschmiedt M, Haber G, Kandel G, Kortan P, Marcon N. A safety maneuver for placing overtubes during endoscopic variceal ligation. Gastrointest Endosc 1992;38:399-400.
42. Barkin JS, Chong J, Reiner DK. First-generation video enteroscope: fourth-generation push-type small bowel enteroscopy utilizing an overtube. Gastrointest Endosc 1994;40:743-7.



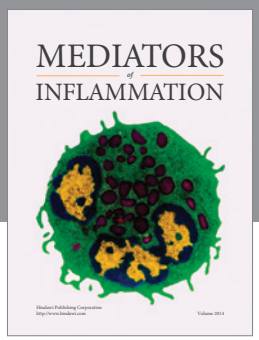

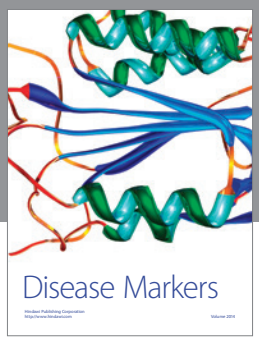



Hindawi
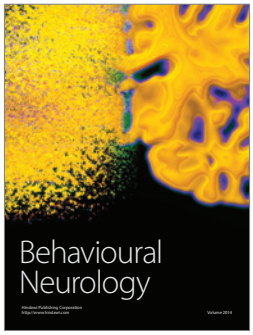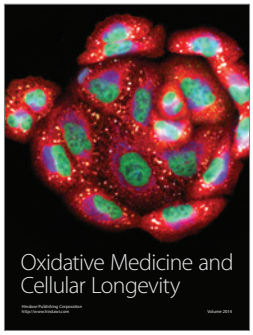
Submit your manuscripts at
http://www.hindawi.com