A new method of enteroscopy – The double-balloon method

Hironori Yamamoto MD, Kentaro Sugano MD

H Yamamoto, K Sugano. A new method of enteroscopy – The double-balloon method. Can J Gastroenterol 2003;17(4):273-274.

The diagnosis and treatment of diseases of the small intestine have been impeded by difficult technical challenges. Traditionally, endoscopic evaluation of this organ has required open laparotomy with the surgically assisted passage of the scope through the intestine. Nonsurgical endoscopic techniques have been developed, including push enteroscopy, passage of a scope over a guide-string, and a method that depends on peristalsis to advance the instrument, but each of these is subject to severe limitations. A novel procedure has been devised, whereby an endoscope and a soft flexible overtube, each of which has an inflatable balloon attached to its distal end, are employed together. The technique is described in detail in the present article. Double-balloon enteroscopy allows visualization of the entire small intestine, to and fro examination of an area of interest, and the taking of biopsy specimens in a manner that is safer, quicker and less painful than previous techniques. It constitutes an important advance in the diagnosis and management of bleeding and other small intestinal disorders.

Key Words: *Double-balloon; Enteroscopy; Small intestine*

Un nouveau mode d'entéroscopie : La méthode à double ballonnet

Le diagnostic et le traitement des maladies de l'intestin grêle sont entravés par des défis techniques difficiles. Par le passé, l'évaluation endoscopique de cet organe exigeait une laparotomie ouverte accompagnée du passage chirurgical de l'entéroscope dans l'intestin. Des techniques endoscopiques non chirurgicales ont été élaborées, y compris l'entéroscopie par poussée, le passage de l'entéroscope à l'aide d'une ficelle d'orientation et une méthode qui dépend du péristaltisme pour faire progresser l'instrument, mais chacune de ces méthodes est gravement limitée. Une nouvelle intervention a été mise au point, selon laquelle sont utilisés ensemble un endoscope et une sursonde molle et flexible, tous deux munis d'un ballonnet gonflable fixé à leur extrémité distale. Le présent article présente la technique de manière détaillée. L'entéroscopie à double ballonnet permet de visualiser tout l'intestin grêle, de procéder à un examen en va-et-vient d'une région de l'intestin grêle et de prélever des biopsies de manière plus sûre, plus rapide et moins douloureuse que les techniques précédentes. C'est un progrès important dans le diagnostic et la prise en charge des saignements et d'autres troubles de l'intestin grêle.

The small intestine is located quite far from both the mouth and the anus. Because it is relatively inaccessible endoscopically, diseases in this organ are difficult to diagnose. Although visualization of the small intestine by a capsule endoscope has been reported in recent years, it is not yet a suitable diagnostic method, because to and fro observation of a particular area of interest is impossible, and biopsies and therapeutic procedures cannot be accomplished. We devised a new method of enteroscopy that uses two balloons, one attached to the tip of the endoscope and another at the distal end of a soft overtube. We reported that endoscopic examination of the entire small intestine was possible with this method using an endoscope of 200 cm in working length (1). This article describes the double-balloon endoscopic system.

The importance of endoscopic exploration of the small bowel has been well documented. Established indications for small-bowel enteroscopy include unexplained bleeding from the gastrointestinal tract, radiographic abnormalities of the small intestine and chronic diarrhea or malabsorption (2). Push enteroscopy is the most frequently used method for inserting the instrument. Deep insertion of an enteroscope is difficult with this method, however, because the force applied to advance the instrument is dissipated by the tortuosity of the small intestine. Moreover, this process causes tremendous discomfort to the patient. Therefore, even with new-generation video-push enteroscopes with overtubes, the depth of insertion is at most 160 cm beyond the ligament of Treitz. This is far less than the length of the small intestine, which is approximately 14 feet (430 cm) (3).

At present, intraoperative enteroscopy is the most reliable procedure for visualization of the entire small intestine. In this method, the passage of the enteroscope is assisted by the surgeon during open laparotomy. Although the technique is not difficult, both an endoscopist and a surgeon are required to perform the procedure, and it is invasive in nature.

Nonsurgical total small bowel enteroscopy has been successfully accomplished by two different methods. One method uses an instrument that is pushed over a previously passed guide-string (4-6), whereas the other relies on peristalsis to propel a long, flexible fiberoptic endoscope through the intes-

This article was originally presented at the 15th International Course on Therapeutic Endoscopy, hosted by the Wellesley Group, Division of Gastroenterology, St Michael's Hospital, Toronto, Ontario, October 9-12, 2002
Department of Gastroenterology, Jichi Medical School, Japan
Correspondence and reprints: Dr Hironori Yamamoto, Department of Gastroenterology, Jichi Medical School, 3311-1 Yakushiji, Minamikawachi Kawachi, Tochigi 329-0498, Japan. Telephone 81-285-44-2111, fax 81-285-44-8297, e-mail yamamoto@jichi.ac.jp

tine (7). Both methods are tedious, uncomfortable and time consuming. The guide-string for the 'ropeway' method can take several days to pass from mouth to rectum. Stretching of the string can damage the small bowel mucosa and cause tremendous pain and discomfort that necessitates the use of general anesthesia. The limitations of the 'sonde' procedure are the lack of either tip deflection or intervention capabilities (2). Despite their ability to inspect the entire small bowel, neither method has gained general clinical acceptance.

Because each of the currently available methods has limitations, the development of a relatively noninvasive and steerable endoscopic technique that could explore the entire small bowel and allow interventions is highly desirable.

THE DOUBLE-BALLOON SYSTEM

This technique uses a specifically designed videoendoscope, with an outer diameter of 8.5 mm and a working length of 200 cm and an attachable balloon at its tip. This is used together with a soft overtube of 140 cm length that has another balloon at the distal end. For safety and simplification of insertion procedures, latex soft balloons are used for both the endoscope and the overtube. The balloons can be inflated and deflated with a single touch using a specifically designed pump, while the balloon pressure is accurately monitored.

Procedure

As shown in Figure 1, the overtube is back-loaded onto the endoscope before intubation, while both balloons are deflated. When both balloons reach the duodenum, the balloon on the overtube is inflated to fix the tube to the intestine. The endoscope is inserted further while holding the overtube in place. When the tip of the endoscope is inserted as far as possible, the balloon on the endoscope tip is inflated, the balloon on the overtube is deflated, and the overtube is advanced along the endoscope. When the distal end of the overtube reaches the end of the endoscope, the balloon on the overtube is inflated to fix the device to a second point on the intestine. At this point, gentle withdrawal of the overtube with the balloon inflated causes pleating of the intestine onto the overtube, which prevents looping of the endoscope. This sequence is repeated until the entire small bowel is examined. The volume of insufflated air is controlled according to the pressure in the balloons (up to 50 mmHg) and the discomfort experienced by the patient. The procedure is performed under fluoroscopic guidance.

A retrograde (per rectum) approach to enteroscopy can also be used.

This new double-balloon method could be considered a modification of the push method. However, the technique for the advancement of the instrument is different. In push enteroscopy, deep insertion of the enteroscope is limited by the formation of loops of small intestine that absorb the force exerted to advance the instrument. With the new double-balloon technique, a semi-flexible overtube is used to maintain a straight instrument configuration and prevent bowing in the stomach, thus permitting deeper intubation of the small intestine. The main source of the difficulty, however, is not the formation of loops, but the compliant nature of the looped intestine. In our method, the main purpose of the flexible overtube and balloon is not to keep the instrument straight, but to prevent stretching of the shortened intestine. Redundant instrument loops can easily be reduced and the intubated intestine is shortened by gentle withdrawal of the endoscope while the balloon at its tip is inflated to grip the intestine. Thus, the shortened intestine with minimal looping is maintained by the overtube. As long as the stretching of the intubated intestine is prevented, the endoscope tip can be advanced by pushing it through the overtube. Because excessive stretching of the intestine is prevented and forceful straightening of the stomach and intestine is not required, the procedure can be performed safely and with a minimum of patient discomfort. The endoscope for the double balloon method need not be as stiff as that used for the push method nor be as long as that required for the 'sonde' method. The entire small intestine can be examined using an instrument that is roughly the length of a standard push enteroscope.

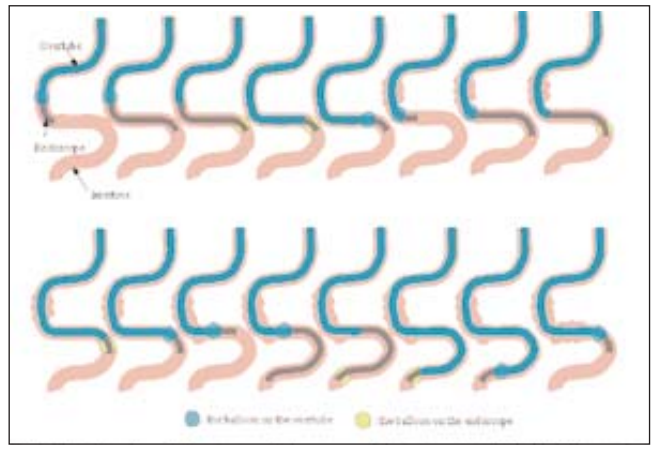

Figure 1) *Illustrations demonstrating the sequential maneuvers of the instruments in the double-balloon method*

The double-balloon method of enteroscopy enables deep insertion of an endoscope into the small intestine while preventing excessive stretching of the intestinal tract. This technique can use either an oral approach or an anal approach. To and fro observation of almost any part of the small intestine is possible, as are interventions, such as the taking of biopsy specimens. This new method could assist in the diagnosis and treatment of diseases of the small intestine, where endoscopic access is otherwise difficult.

REFERENCES

1. Yamamoto H, Sekine Y, Sato Y, et al. Total enteroscopy with a nonsurgical steerable double-balloon method. Gastrointest Endosc 2001;53:216-20.
2. Waye JD. Enteroscopy. Gastrointest Endosc 1997;46:247-56.
3. Landi B, Tkoub M, Gaudric M, et al. Diagnostic yield of push-type enteroscopy in relation to indication. Gut 1998;42:421-5.
4. Hiratsuka H, Hasegawa M, Ushiromachi K, et al. Endoscopic diagnosis of the small intestine. Stomach Intestine 1972;7:1679-85.
5. Deyhle P, Jenny S, Fumagalli J, Linder E, Ammann R. Endoscopy of the whole small intestine. Endoscopy 1972;4:155-7.
6. Classen M, Frühmorgen P, Koch H, Demling L. Peroral enteroscopy of the small and the large intestine. Endoscopy 1972;4:157-62.
7. Tada M, Akasaka Y, Misaki F, Kwaie K. Clinical evaluation of a sonde-type small intestinal fiberscope. Endoscopy 1977;9:33-8.