

Octreotide treatment of massive hemorrhage due to cytomegalovirus colitis

Christopher N Andrews MD, Paul L Beck MD PhD FRCPC

CN Andrews, PL Beck. Octreotide treatment of massive hemorrhage due to cytomegalovirus colitis. *Can J Gastroenterol* 2003;17(12):722-725.

Cytomegalovirus (CMV)-associated colitis can result in abdominal pain, diarrhea, significant blood loss and perforation. The standard therapy for CMV colitis includes supportive measures and antiviral medications. Severe hemorrhage due to CMV colitis often necessitates surgical resection. We present a case of a patient who was undergoing chemotherapy for acute B-cell lymphoblastic leukemia and developed significant abdominal pain and diarrhea followed by massive hematochezia. Colonoscopy showed numerous actively bleeding deep ulcers in the cecum. A provisional diagnosis of CMV colitis was made and she was started on ganciclovir. Histological assessment confirmed the diagnosis of CMV colitis. She continued to bleed profusely per rectum over the following five days, passing up to 1 L to 1.5 L of blood per day. She required 10 units of packed red blood cells over this time period. The patient refused surgical intervention and after discussion of possible options, octreotide was instituted. Her blood loss stopped almost immediately and she required no further transfusions. She tolerated the medication well and was discharged home at a later date in stable condition. This is the first reported case of the use of octreotide in the treatment of massive hematochezia from CMV colitis.

Key Words: CMV; Colitis; Cytomegalovirus; Octreotide

In the immunosuppressed host, cytomegalovirus (CMV) colitis can result in significant blood loss. Current management of severe bleeding in CMV colitis consists of antiviral therapy, and if the bleeding remains uncontrolled, surgery is usually required. Mortality from CMV colitis is high, with recent series reporting rates between 15% and 44% (1,2), depending on the cause of immunosuppression. Patients with CMV colitis are often poor surgical candidates due to their underlying disease processes; if they fail standard antiviral therapy, the treatment options are limited. We present a case of prolonged colonic bleeding due to CMV colitis successfully treated with octreotide, a synthetic somatostatin analogue.

CASE PRESENTATION

A 46-year-old woman with a new diagnosis of B-cell acute lymphoblastic leukemia was treated with induction chemotherapy, and by day 4 she was pancytopenic with an undetectable lymphocyte count and an absolute neutrophil count below

Traitement à l'octréotide d'une hémorragie massive due à une colite à cytomégalovirus

La colite associée au cytomégalovirus (CMV) peut donner lieu à des douleurs abdominales, à de la diarrhée, à des pertes importantes de sang et même à des perforations. Le traitement courant de la colite à CMV consiste en des mesures de soutien et en l'administration d'antiviraux. Les hémorragies graves dues à la colite à CMV nécessitent souvent la résection chirurgicale. Voici le cas d'une patiente, déjà soumise à la chimiothérapie pour une leucémie aiguë lymphoblastique de type B, chez qui sont apparues de fortes douleurs abdominales et de la diarrhée, suivie d'un méleane massif. La coloscopie a révélé de nombreux ulcères profonds, hémorragiques dans le caecum. Un diagnostic provisoire de colite à CMV a été posé à la suite de quoi on a commencé un traitement au ganciclovir. L'examen histologique a confirmé le diagnostic. La patiente a continué à présenter des hémorragies abondantes par le rectum au cours des cinq jours suivants; ses pertes sont passées de 1 à 1,5 litre de sang par jour. Durant ce temps, il a fallu lui administrer 10 culots globulaires. La patiente a refusé l'intervention chirurgicale et, après discussion sur les différentes options possibles, il a été décidé de lui prescrire de l'octréotide. L'hémorragie a cessé presque immédiatement et la patiente n'a pas eu besoin d'autres transfusions. Elle a bien toléré le médicament et elle a obtenu son congé plus tard dans un état stable. Il s'agit là du premier cas déclaré de colite à CMV, traitée par l'octréotide pour un méleane massif.

0.5×10^9 cells/L (normal 2.0 to 9.0×10^9 cells/L). Her past medical history was significant for type 2 diabetes mellitus, hyperlipidemia and previous appendectomy, cholecystectomy and hysterectomy. Her prechemotherapy CMV serology was negative.

On day 10, post induction chemotherapy, she developed mild diffuse abdominal pain, loose nonbloody stools and intermittent fevers. These symptoms continued for the next two weeks. Extensive work-up during that time, including repeated stool assays for *Clostridium difficile* toxin and a computed tomography scan of the abdomen, were negative.

At day 23 she passed 500 mL of bright red blood per rectum. Urgent endoscopy was undertaken, which showed friable, small, shallow esophageal ulcers and small nonbleeding shallow gastric ulcers. Colonoscopy revealed features characteristic of CMV colitis, including diffuse erythema, edema and numerous actively bleeding deep ulcers in the cecum (Figure 1). A provisional diagnosis of CMV colitis was made and she was

Division of Gastroenterology, Faculty of Medicine, University of Calgary, Calgary, Alberta

Correspondence: Dr Paul L Beck, Division of Gastroenterology, Faculty of Medicine, University of Calgary Health Sciences Center,

3330 Hospital Drive Northwest, Calgary, Alberta T2N 4N1. Telephone 403-220-4500, fax 403-270-0995, e-mail plbeck@ucalgary.ca

Received for publication May 22, 2003. Accepted September 10, 2003

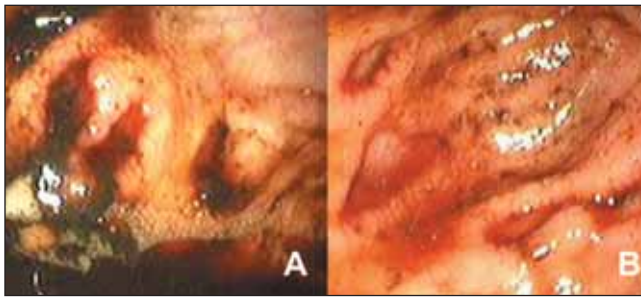


Figure 1) A Endoscopic appearance of oozing cytomegalovirus ulcers in cecum. **B** Multiple cytomegalovirus ulcers

started on ganciclovir (Cytovene, Hoffman-LaRoche Inc, USA) 400 mg intravenously every 12 h. Histological assessment confirmed the diagnosis of CMV colitis.

She continued to bleed profusely from the colon over the following five days, passing up to 1 L to 1.5 L of hematochezia per day. She required 10 units of packed red blood cells to maintain her hemoglobin in the range of 100 to 110 g/L (normal 120 to 160 g/L). She had no evidence of coagulopathy during this time, with lowest platelet count 130×10^9 cells/L (normal 150 to 400×10^9 cells/L) and the highest international normalized ratio was 1.2.

The general surgery service was consulted but the patient was not keen to proceed to surgery. After her insistence on information on possible medical interventions, the theoretical possibility that octreotide could slow the bleeding was discussed. Because the hematochezia continued without improvement, on day 27 octreotide (Sandostatin; Novartis Pharmaceuticals Corp, USA) was started with the patient's informed consent, with a 50 µg intravenous bolus, followed by a 25 µg/h infusion for 48 h (Figure 2). The bleeding stopped completely within 24 h of beginning the infusion. There were no adverse effects from the infusion. After the infusion was finished, there was no evidence of further gastrointestinal bleeding. She completed 14 days of ganciclovir therapy. A follow-up colonoscopy was refused by the patient and she was discharged home in good condition on day 38.

DISCUSSION

CMV infection is a well-documented cause of gastrointestinal disease in immunosuppressed patients (3-5). Clinical symptoms of CMV colitis include diarrhea, hematochezia, urgency, tenesmus and abdominal pain. Constitutional symptoms such as fever, malaise, night sweats and weight loss may also be present (5). Hemorrhage is a common presentation of CMV colitis, affecting 35% to 70% of such patients (1,2,5). The bleeding can be massive (6,7), and is not amenable to endoscopic therapy due to the friable and diffuse nature of the ulceration and inflammation. It is unclear how often significant bleeding occurs in CMV colitis in the postchemotherapy setting. However, CMV-associated hemorrhage is one of the more common causes of lower gastrointestinal bleeding in those with acquired immune deficiency syndrome (8).

Ganciclovir is the antiviral treatment of choice for CMV colitis. In most patients, the bleeding resolves soon after initiating therapy (8). However, despite adequate antiviral therapy, hemorrhage from CMV colitis can be fatal (9). In our patient, significant blood loss continued after five days of ganciclovir

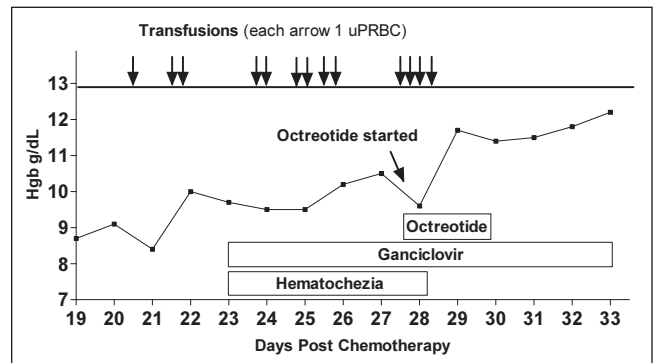


Figure 2) Hemoglobin (Hgb) and transfusion requirements before and after octreotide 50 µg intravenous bolus, followed by a 25 µg/h infusion for 48 h. Each arrow represents one unit of packed red blood cells (uPRBC). The bleeding stopped completely within 24 h of beginning the infusion. Ganciclovir (400 mg intravenous) was started on day 23 and given every 12 h. The histological assessment confirmed the diagnosis of cytomegalovirus colitis

therapy, and octreotide was thus considered as a possible adjunct to reduce blood loss.

Octreotide is a long-acting somatostatin analogue known to decrease splanchnic blood flow, and is used to control gastrointestinal bleeding from esophageal varices in the context of portal hypertension (10,11). This agent has also been used to control gastrointestinal hemorrhage from various causes, including peptic ulcer (12,13), angiodysplasia (14), portal hypertensive gastropathy (15), portal hypertensive colopathy (16), vascular ectasia (17) and blue rubber bleb nevus syndrome (18). To our knowledge, there have been no reports of its use in treating hemorrhage from CMV colitis.

The exact mechanisms by which octreotide reduces gastrointestinal bleeding are not fully understood, but are thought to include both vascular and nonvascular effects. The vascular effects are reasonably well described and are thought to affect both intestinal microcirculation as well as larger vasculature. In a rat model of ischemia-reperfusion, octreotide caused a reduction in mucosal perfusion in the jejunum in both physiological conditions and after ischemia-reperfusion (19). In a swine model, octreotide reduced superior mesenteric artery blood flow but the doses assessed were much greater than those used clinically (20 µg/kg to 25 µg/kg) and not seen with 5 µg/kg and 10 µg/kg doses (20). In human studies, octreotide caused a reduction in gastric (21), superior mesenteric artery (22) and portal flow in healthy volunteers at the clinically appropriate doses of 25 µg/h to 100 µg/h (23). In portal hypertension, octreotide reduces variceal pressure (24), hepatic artery pulsatility, portal vein diameter, and both the volume and velocity of portal vein flow (10). Octreotide can also cause reductions in heart rate and cardiac output, and a paradoxical increase in systemic and pulmonary pressures, but these changes are dose related and are insignificant when the dose is limited to 50 µg/h (25-27).

The potential nonvascular effects of octreotide are numerous. Octreotide has been found to reduce bacterial translocation in several animal model systems (28-30) but not in all settings (31,32). Octreotide has also been found to inhibit hepatic fibrosis and bile duct proliferation in a bile duct-ligated obstructive jaundice model (28). Other studies have shown that octreotide can reduce gastric injury in the rat induced by

hemorrhagic shock, stress and ethanol (33,34). Somatostatin can reduce renal plasma flow and glomerular filtration rate, but cardiovascular and renal complications have not been reported in clinical trials with somatostatin or octreotide (27,35). Octreotide can also decrease gastric and vasoactive intestinal peptide secretion resulting in increased gastric pH, and even small doses can result in increased gastric pH in healthy volunteers, putting into question the commonly encountered combined use of intravenous proton pump inhibitors with octreotide (21). Octreotide inhibits colonic motility, and the impact of this on hemostasis is unclear (36).

After a detailed review of the actions of octreotide, the most likely mechanisms that resulted in reduced blood loss in our patient with CMV colitis are probably reduced blood flow to the region involved, but other nonvascular actions may have been involved.

Theoretically, octreotide could increase the risk of mesenteric ischemia. The incidence of this complication is unclear; we were unable to identify any reported cases of intestinal ischemia using the search parameters "octreotide" or

"somatostatin" and "intestinal ischemia" on a MEDLINE database search from 1990 to the present. Furthermore, the prescribing monograph (2002) for Sandostatin (octreotide) does not include intestinal ischemia as a reported adverse effect. Interestingly, octreotide and/or somatostatin have been found in animal models to reduce ischemia reperfusion injury in numerous tissues, including the intestine (37). In addition, there is a case report of the successful management of a patient with intestinal angina with octreotide (38). We discussed this theoretical risk and the other known complications of octreotide with our patient before administration.

Octreotide is generally well tolerated and can be considered in patients with hemorrhage from CMV colitis who do not respond adequately to antiviral therapy.

ACKNOWLEDGEMENTS: This work was supported by the Canadian Institute of Health Research (CIHR) and the Alberta Heritage Foundation for Medical Research (AHFMR). Dr Beck is a New Investigator (CIHR) and a Clinical Investigator (AHFMR).

REFERENCES

- Page MJ, Dreese JC, Poritz LS, Koltun WA. Cytomegalovirus enteritis: A highly lethal condition requiring early detection and intervention. *Dis Colon Rectum* 1998;41:619-23.
- Kaufman HS, Kahn AC, Iacobuzio-Donahue C, Talamini MA, Lillemoe KD, Hamilton SR. Cytomegaloviral enterocolitis: Clinical associations and outcome. *Dis Colon Rectum* 1999;42:24-30.
- Bini EJ, Weinshel EH, Falkenstein DB. Risk factors for recurrent bleeding and mortality in human immunodeficiency virus infected patients with acute lower GI hemorrhage. *Gastrointest Endosc* 1999;49:748-53.
- Chetty R, Roskell DE. Cytomegalovirus infection in the gastrointestinal tract. *J Clin Pathol* 1994;47:968-72.
- Goodgame RW. Gastrointestinal cytomegalovirus disease. *Ann Intern Med* 1993;119:924-35.
- Keates J, Lagahee S, Crilley P, Haber M, Kowalski T. CMV enteritis causing segmental ischemia and massive intestinal hemorrhage. *Gastrointest Endosc* 2001;53:355-9.
- Sun JH, Johnson WS, Bascom JF. Cytomegalovirus-induced massive small intestinal bleed. Case report and review of the literature. *Rev Med Chir Soc Med Nat Iasi* 1997;101:209-12.
- Chalasani N, Wilcox CM. Etiology and outcome of lower gastrointestinal bleeding in patients with AIDS. *Am J Gastroenterol* 1998;93:175-8.
- Leung SF, Lee KC, Lam HW. Gastro-intestinal cytomegalovirus infection and extensive colonic ulceration in a renal transplant recipient. *Hong Kong Med J* 1998;4:434-6.
- Zhang HB, Wong BC, Zhou XM, et al. Effects of somatostatin, octreotide and pitressin plus nifedipine on systemic and portal haemodynamics in the control of acute variceal bleeding. *Int J Clin Pract* 2002;56:447-51.
- Banares R, Albillos A, Rincon D, et al. Endoscopic treatment versus endoscopic plus pharmacologic treatment for acute variceal bleeding: A meta-analysis. *Hepatology* 2002;35:609-15.
- Jenkins SA, Taylor BA, Nott DM, Ellenbogen S, Haggie J, Shields R. Management of massive upper gastrointestinal haemorrhage from multiple sites of peptic ulceration with somatostatin and octreotide - A report of five cases. *Gut* 1992;33:404-7.
- Imperiale TF, Birgisson S. Somatostatin or octreotide compared with H2 antagonists and placebo in the management of acute nonvariceal upper gastrointestinal hemorrhage: A meta-analysis. *Ann Intern Med* 1997;127:1062-71.
- Nardone G, Rocco A, Balzano T, Budillon G. The efficacy of octreotide therapy in chronic bleeding due to vascular abnormalities of the gastrointestinal tract. *Aliment Pharmacol Ther* 1999;13:1429-36.
- Zhou Y, Qiao L, Wu J, Hu H, Xu C. Comparison of the efficacy of octreotide, vasopressin, and omeprazole in the control of acute bleeding in patients with portal hypertensive gastropathy: A controlled study. *J Gastroenterol Hepatol* 2002;17:973-9.
- Yoshie K, Fujita Y, Moriya A, Kawana I, Miyamoto K, Umemura S. Octreotide for severe acute bleeding from portal hypertensive colopathy: A case report. *Eur J Gastroenterol Hepatol* 2001;13:1111-3.
- Garcia N, Sanyal AJ. Portal hypertensive gastropathy and gastric antral vascular ectasia. *Curr Treat Options Gastroenterol* 2001;4:163-71.
- Gonzalez D, Elizondo BJ, Haslag S, et al. Chronic subcutaneous octreotide decreases gastrointestinal blood loss in blue rubber-bleb nevus syndrome. *J Pediatr Gastroenterol Nutr* 2001;33:183-8.
- Heuser M, Popken O, Kleiman I, Post S. Detrimental effects of octreotide on intestinal microcirculation. *J Surg Res* 2000;92:186-92.
- Tocchi A, Costa G, Lepre L, Liotta G, Mazzoni G, Miccini M. [Effects of octreotide (somatostatin analog SMS 201-995) on superior mesenteric artery blood flow in swine. An experimental study using Doppler color ultrasonography]. *G Chir* 1999;20:9-13.
- Kubba AK, Dallal H, Haydon GH, Hayes PC, Palmer KR. The effect of octreotide on gastroduodenal blood flow measured by laser Doppler flowmetry in rabbits and man. *Am J Gastroenterol* 1999;94:1077-82.
- McCormick PA, Seifalian AM, Stansby G, et al. Superior mesenteric artery blood flow in man measured with intra-arterial Doppler catheters: Effect of octreotide. *J Hepatol* 1993;17:20-7.
- Schiedermaier P, Brensing KA, Goke B, Schatzle T, Sauerbruch T. Effects of different octreotide dosages on splanchnic hemodynamics and glucagon in healthy volunteers. *Digestion* 1999;60:132-40.
- Nevens F, Van Steenberghe W, Yap SH, Fevery J. Assessment of variceal pressure by continuous non-invasive endoscopic registration: A placebo controlled evaluation of the effect of terlipressin and octreotide. *Gut* 1996;38:129-34.
- McCormick PA, Chin J, Greenslade L, et al. Cardiovascular effects of octreotide in patients with hepatic cirrhosis. *Hepatology* 1995;21:1255-60.
- Lin HC, Tsai YT, Lee FY, et al. Hemodynamic evaluation of octreotide in patients with hepatitis B-related cirrhosis. *Gastroenterology* 1992;103:229-34.
- Chan LY, Sung JJ. Review article: The role of pharmacotherapy for acute variceal haemorrhage in the era of endoscopic haemostasis. *Aliment Pharmacol Ther* 1997;11:45-50.
- Turkcapar N, Bayar S, Koyuncu A, Ceyhan K. Octreotide inhibits hepatic fibrosis, bile duct proliferation and bacterial translocation in obstructive jaundice. *Hepatogastroenterology* 2003;50:680-3.
- Aldemir M, Kokoglu OF, Geyik MF, Buyukbayram H. Effects of octreotide acetate and *Saccharomyces boulardii* on bacterial translocation in an experimental intestinal loop obstruction model of rats. *Tohoku J Exp Med* 2002;198:1-9.
- Akyildiz M, Ersin S, Oymaci E, Dayangac M, Kapkac M, Alkanat M. Effects of somatostatin analogues and vitamin C on

- bacterial translocation in an experimental intestinal obstruction model of rats. *J Invest Surg* 2000;13:169-73.
 31. Taylor GE, Hebra A, McGowan KL, et al. Octreotide does not prevent bacterial translocation in an infant piglet model of intestinal ischemia-reperfusion. *J Pediatr Surg* 1995;30:967-70.
 32. Turkcapar AG, Ersoz S, Gur U, et al. The effect of octreotide on bacterial translocation from the gut. An experimental study. *Int Surg* 1995;80:264-6.
 33. Wallace JL, Boichot E, Sidoti C, Brex A, Paubert-Braquet M. Protective effects of somatostatin against gastric damage induced by hemorrhagic shock, stress and PAF in the rat. *Regul Pept* 1993;47:195-203.
 34. Kusterer K, Buchheit KH, Schade A, et al. The somatostatin analogue octreotide protects against ethanol-induced microcirculatory stasis and elevated vascular permeability in rat gastric mucosa. *Eur J Pharmacol* 1994;259:265-71.
 35. Gines A, Salmeron JM, Gines P, et al. Effects of somatostatin on renal function in cirrhosis. *Gastroenterology* 1992;103:1868-74.
 36. John KD, Ballantyne GH, Modlin IM. Octreotide acetate inhibits motility in the rabbit distal colon. *Eur Surg Res* 1997;29:311-8.
 37. Morris JB, Guerrero NH, Furth EE, Stellato TA. Somatostatin attenuates ischemic intestinal injury. *Am J Surg* 1993;165:676-80.
 38. Anderson SH, Dalton HR. Use of octreotide in the treatment of mesenteric angina. *Am J Gastroenterol* 1997;92:1222-3.
-
-

