Diffuse skin reaction in a patient with hepatitis B, treated with two different formulations of pegylated interferon

Piotr Milkiewicz MD[1,2], Colina Yim RN[1], Isabelle Pache MD[1], Jenny Heathcote MD[1]

P Milkiewicz, C Yim, I Pache, J Heathcote. Diffuse skin reaction in a patient with hepatitis B, treated with two different formulations of pegylated interferon. Can J Gastroenterol 2005;19(11):677-678.

Diffuse skin reactions, commonly leading to discontinuation of the treatment, have been reported in patients with hepatitis C treated with interferon. They were not as yet described in patients treated with a newer formulation of interferon, namely, pegylated interferon (PegINF). A 37-year-old male patient with viral hepatitis B developed a diffuse urticarial skin reaction during treatment with two different forms of PegINF. Despite the skin reaction, the treatment was continued, and the patient responded very well to topical steroids and antihistamines. The present report suggests that despite the severity of reaction, withdrawal of PegINF may not always be required because this particular skin reaction responded well to symptomatic treatment. This is important, because discontinuation of PegINF may decrease the chance of achieving a sustained virological response in patients with viral hepatitis.

Key Words: *Hepatitis B; Pegylated interferon; Skin reaction*

Réaction cutanée diffuse chez un patient atteint de l'hépatite B traité au moyen de deux formulations différentes d'interféron pégylé

Des réactions cutanées diffuses, qui entraînent souvent l'arrêt du traitement, ont été déclarées chez des patients atteints d'hépatite C traités à l'interféron. Elles n'avaient pas encore été décrites chez des patients traités au moyen d'une nouvelle formulation d'interféron, l'interféron pégylé (PegINF). Un patient de 37 ans atteint d'hépatite B virale a manifesté une réaction cutanée urticarienne diffuse pendant un traitement à l'aide de deux formes de PegINF. Malgré la réaction cutanée, le traitement s'est poursuivi, et le patient a très bien réagi aux stéroïdes topiques et aux antihistaminiques. Le présent rapport laisse supposer que malgré la gravité de la réaction, l'arrêt du PegINF ne serait pas toujours nécessaire puisque la réaction symptomatique réagit bien à un traitement symptomatique. C'est important, car l'arrêt du PegINF pourrait réduire la possibilité d'obtenir une réponse virologique soutenue chez les patients atteints d'une hépatite virale.

Pegylated interferon (PegINF) is a newer formulation of interferon (INF), consisting of INF-alpha combined with polyethyleneglycol. It is now the standard of care in the treatment of patients with hepatitis C virus, and recent studies indicate its effectiveness in the treatment of hepatitis B virus (HBV) infection (1,2). Skin reactions, except erythema at the injection site, are considered to be uncommon in patients treated with INF (3,4). They have been reported in patients with hepatitis C virus (but not HBV) who were treated with the standard (ie, not containing the polyethyleneglycol moiety) formulation of INF. Skin reactions have been linked with hypersensitivity and have led to discontinuation of the treatment in several cases (5).

CASE PRESENTATION

A 37-year-old male patient with HBV, who developed a diffuse skin reaction during treatment with two different formulations of PegINF, is described. He was diagnosed with HBV approximately 14 years previously. In 2003, he was found to have elevated levels of alanine aminotransferase at 294 U/L (normal 3 U/L to 30 U/L) and aspartate aminotransferase at 91 U/L (normal 3 U/L to 30 U/L). His liver biopsy showed features compatible with HBV infection with grade 2 to 3 fibrosis and grade 2 to 3 inflammatory activity (according to the Laennec score). He was treated with PegINF-alpha2b (Unitron PEG, Schering Canada) at a dose of 150 µg/week for four months and lamivudine 100 mg/day. Approximately two months into the treatment, he developed a generalized skin lesion surrounding not only the site of injection, but also affecting both flanks, and his neck and palms. This rash was very itchy, confluent and raised, with well-delineated erythematous areas. A biopsy of the lesions was not performed and the rash was successfully treated with topical steroids. Because he had achieved hepatitis B e antigen loss and had undetectable HBV DNA, his PegINF-alpha2b was stopped after four months. The lamivudine was continued for 52 weeks.

Unfortunately, one year after discontinuing his lamivudine, his HBV was reactivated. Blood tests showed an increase of alanine aminotransferase to 351 U/L and aspartate aminotransferase to 86 U/L, and he tested hepatitis B e antigen-positive once again. This time he was prescribed PegINF-alpha2a (Pegasys, Hoffmann-La Roche Limited, Canada) at a dose of 180 µg/week (without lamivudine).

[1]*Toronto Western Hospital, University Health Network, Toronto, Ontario;* [2]*Department of Gastroenterology, Pomeranian Medical School, Unii Lubelskiej 1, Poland.*
Correspondence: Dr Piotr Milkiewicz, Toronto Western Hospital, University Health Network, 399 Bathurst Street, 6B Fell Pavilon, Room 172, Toronto, Ontario M5T 2S8. Telephone 416-603-5800, fax 416-603-6281, e-mail p.milkiewicz@wp.pl

 ©2005 Pulsus Group Inc. All rights reserved

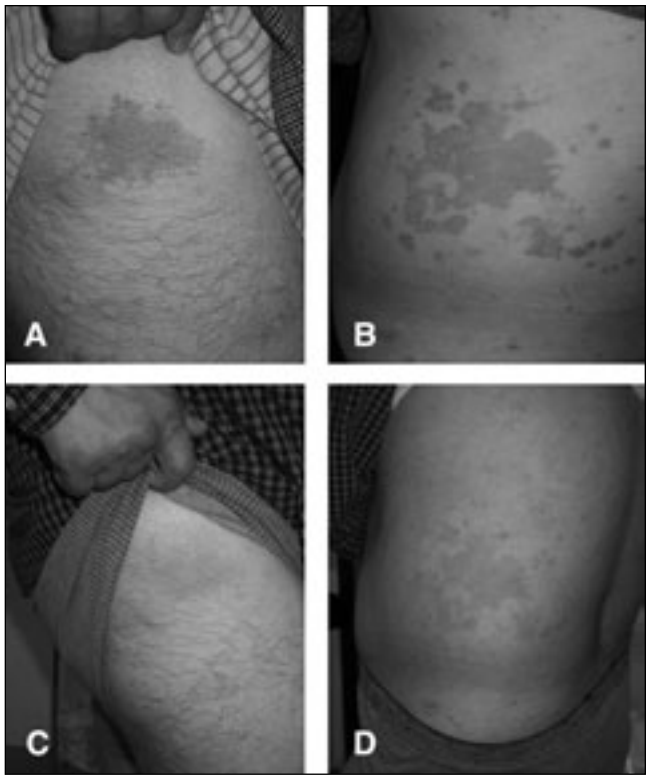

Figure 1) A *and* **B** *Diffuse skin reaction after second dose of pegylated interferon-alpha2a.* **C** *and* **D** *Significant improvement after topical steroids and cetrizine hydrochloride*

Again, he developed a diffuse skin reaction, affecting the site of injection, his trunk, hands and scalp (Figures 1A and 1B). On this occasion, the reaction occurred after only the second injection of PegINF-alpha2a. Although the patient's vital signs were stable, discontinuation of the medication was considered. However, the patient was very determined to continue his treatment, and thus, PegINF-alpha2a was not stopped. His urticaria was treated with topical steroids and an antihistamine, cetrizine hydrochloride (Reactine, Pfizer Canada Inc), at a dose of 10 mg twice per day. He responded very well (Figures 1C and 1D). The topical steroids were stopped and the dose of cetrizine hydrochloride was reduced to 5 mg/day

DISCUSSION

Various skin reactions have been reported in patients treated with standard INF. These include erythema multiforme, diffuse urticaria, vitiligo, hair loss, angioedema, lichen planus and de novo psoriasis (3). With the exception of erythema at the site of injection, which may occur in up to 12% of patients (6), skin lesions in patients treated with INF-alpha are uncommon, and diffuse urticaria away from the injection sites is extremely rare (5). The occurrence of a widespread skin reaction frequently leads to discontinuation of INF treatment, but this decreases the chance of obtaining a virological response and, hence, effective treatment of the underlying infection.

The present case report is the first description of a diffuse skin reaction in a patient with HBV treated with two different formulations of PegINF-alpha. It suggests that, despite the severity of reaction, discontinuation of PegINF-alpha may not be necessary, because the rash may respond well to symptomatic modalities, thus allowing the individual to achieve viral suppression and/or clearance.

REFERENCES

1. Marcellin P, Lau GK, Bonino F, et al. Peginterferon alfa-2a alone, lamivudine alone, and the two in combination in patients with HBeAg-negative chronic hepatitis B. N Engl J Med 2004;351:1206-17.
2. Lok AS, McMahon BJ. Chronic hepatitis B: Update of recommendations. Hepatology 2004;39:857-61.
3. Dusheiko G. Side effects of alpha interferon in chronic hepatitis C. Hepatology 1997;26:112S-21S.
4. Sparsa A, Loustaud-Ratti V, Liozon E, et al. Cutaneous reactions or necrosis from interferon alpha: Can interferon be reintroduced after healing? Six case reports. Rev Med Interne 2000;21:756-63.
5. Dereure O, Raison-Peyron N, Larrey D, Blanc F, Guilhou JJ. Diffuse inflammatory lesions in patients treated with interferon alfa and ribavirin for hepatitis C: A series of 20 patients. Br J Dermatol 2002;147:1142-6.
6. Asnis LA, Gaspari AA. Cutaneous reactions to recombinant cytokine therapy. J Am Acad Dermatol 1995;33:393-410.



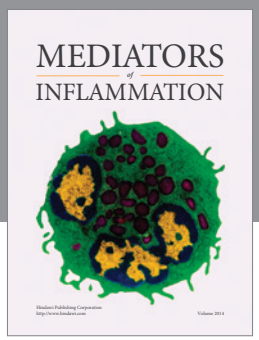

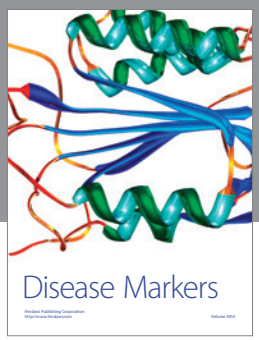



Hindawi
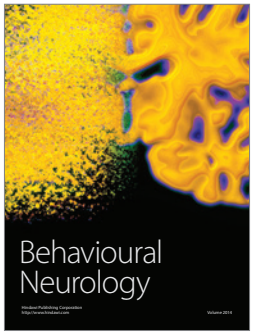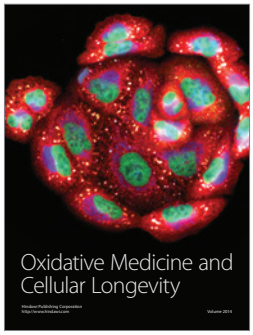
Submit your manuscripts at
http://www.hindawi.com