New diagnostic techniques for esophageal disorders

A Lazarescu MD FRCPC

A Lazarescu. New diagnostic techniques for esophageal disorders. Can J Gastroenterol 2008;22(11):903-908.

Esophageal disorders are common in the general population and can be associated with significant morbidity. Several new diagnostic techniques for esophageal disorders have become available in recent years. These include capsule pH-metry, high-resolution manometry, impedance combined with either pH-metry or manometry, and high-frequency ultrasound. Capsule pH-metry is useful in children and in patients who cannot tolerate the conventional pH-metry catheter. It has the advantage of not interfering with a patient's usual meals and activities during the 24 h study. High-resolution manometery is easier to perform and interpret than conventional manometry. This has led to improved diagnosis of various esophageal motility disorders. Impedance measures the movement of liquid and gas in the esophagus. When combined with pH-metry, impedance can confirm that retrograde bolus movement (ie, reflux) is occurring while simultaneously measuring changes in pH levels. It has also highlighted the importance of weakly acidic reflux in patients who do not respond to proton pump inhibitors. Weakly acidic reflux cannot be diagnosed with pH-metry alone. Impedance combined with manometry can determine whether a manometric abnormality leads to abnormal bolus clearance. In the past, this was performed with fluoroscopy, yet impedance is equally effective and does not carry the risk of increased radiation exposure. High-frequency ultrasound is currently a research tool to image the esophageal wall, particulary the two muscle layers, in real time during swallows and at rest. It has broadened our understanding of the pathophysiology of esophageal motility disorders.

Key Words: *Diagnostic techniques; Esophageal motility disorders; GERD*

Les nouvelles techniques diagnostiques des troubles œsophagiens

Les troubles œsophagiens sont courants au sein de la population générale et peuvent s'associer à une importante morbidité. Plusieurs nouvelles techniques diagnostiques des troubles œsophagiens ont été mises au point ces dernières années. Parmi ces techniques, soulignons la pH-métrie capsulaire, la manométrie à haute résolution, l'impédance combinée avec la pH-métrie ou la manométrie et l'échographie à haute fréquence. La pH-métrie capsulaire est utile chez les enfants et les patients qui ne peuvent tolérer le cathéter de pH-métrie classique. Elle a l'avantage de ne pas entraver les repas et les activités du patient pendant l'étude de 24 heures. La manométrie à haute résolution est plus facile à exécuter et à interpréter que la manométrie classique. Elle a permis d'améliorer le diagnostic de divers troubles de motilité œsophagienne. L'impédance mesure le mouvement du liquide et du gaz dans l'œsophage. Combinée à la pH-métrie, elle peut confirmer qu'un mouvement rétrograde du bolus (c'est-à-dire un reflux) se produit tout en mesurant les changements de pH. Elle a également démontré l'importance du reflux acide bénin chez les patients qui ne répondent pas aux inhibiteurs de la pompe à protons. Le reflux acide bénin ne peut être diagnostiqué par simple pH-métrie. L'impédance combinée à la manométrie peut déterminer si une anomalie manométrique s'associe à une clairance anormale du bolus. Par le passé, on obtenait ce résultat par fluoroscopie, mais l'impédance est tout aussi efficace et ne comporte pas le risque d'exposition accrue aux radiations. L'échographie à haute fréquence est un outil de recherche pour obtenir une image de la paroi œsophagienne, notamment les deux couches musculaires, en temps réel, pendant la déglutition et au repos. Elle nous a permis de mieux comprendre la physiopathologie des troubles de motilité œsophagienne.

Esophageal disorders span the spectrum from motility to reflux to functional conditions. Such disorders affect a large proportion of the population and lead to significant morbidity. A better understanding of the pathophysiology of esophageal disorders can help in their diagnosis and management. In the past decade, significant advances have been made in the diagnostic techniques for esophageal disorders. The present review will address current state-of-the-art diagnostic techniques for esophageal disorders, in addition to a technique that is still used only for research, but with potential future clinical applications. The techniques will be discussed as they relate to three common symptoms: heartburn/reflux, chest pain and dysphagia.

HEARTBURN/REFLUX

Heartburn is very common in the general population. While the use of proton pump inhibitors (PPIs) has helped many patients, a significant number do not respond to acid suppression. This is often the time when they are referred to a gastroenterologist. With endoscopy and 24 h pH-metry, patients can be categorized as having erosive disease, nonerosive disease (NERD), or simply gastroesophageal reflux disease (GERD). Symptom-reflux analysis has been particularly helpful in NERD patients, some of whom may not have an increased overall acid exposure, yet have a strong correlation between their symptoms and reflux.

Division of Gastroenterology, University of Alberta, Edmonton, Alberta
Correspondence: Dr Adriana Lazarescu, Division of Gastroenterology, University of Alberta, Zeidler Ledcor Centre, Edmonton, Alberta T6G 2X8. Telephone 780-248-1498, fax 780-248-1499, e-mail adriana.lazarescu@ualberta.ca

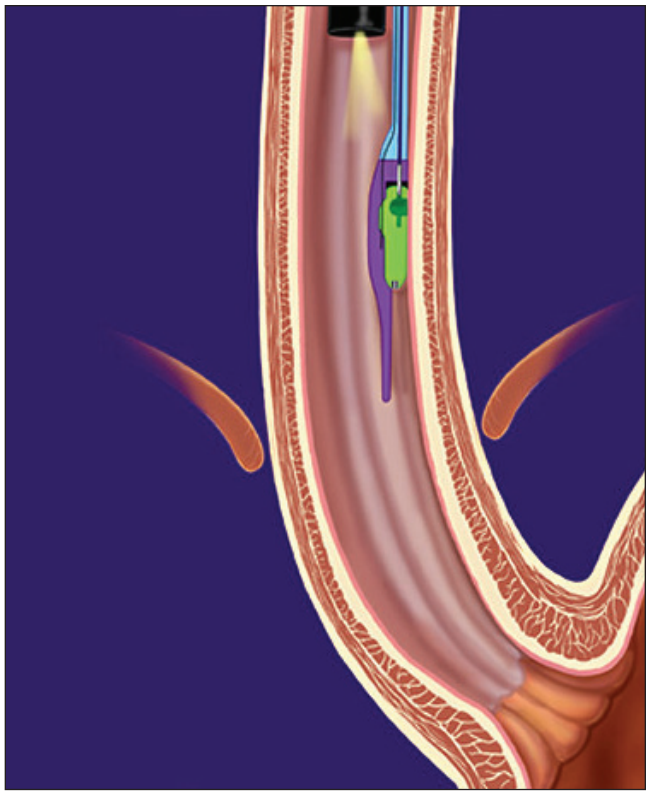

Figure 1) *Wireless pH-metry capsule attached to distal esophageal mucosa (Bravo system, Medtronic, USA)*

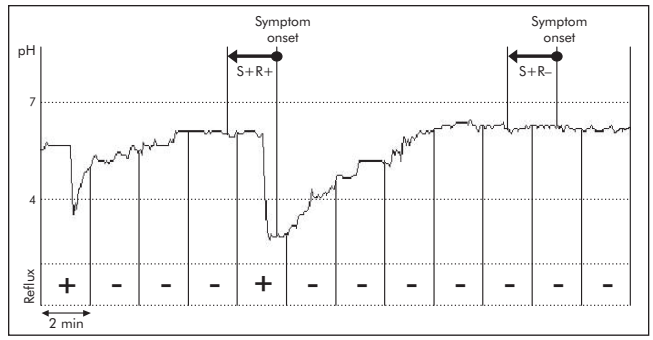

Figure 2) *Symptom association probability index. The 24 h period of monitoring is divided into 2 min intervals. Each interval is classified into one of four categories: Reflux-positive (R+), symptom-positive (S+); R+ S-negative (S–); R-negative (R–)S+; and R–S–. A Fisher's exact test is then performed and a symptom association probability value greater than 95% means that the association between symptoms and reflux can be attributed to chance less than 5% of the time. Figure reproduced with permission from reference 6.*

Catheter versus capsule

Esophageal pH monitoring is considered to be the gold standard for gastroesophageal reflux detection. Currently, it can be performed using either a catheter-based or capsule-based wireless system. The catheter-based measurements are conventionally performed with a pH sensor located 5 cm above the proximal border of the lower esophageal sphincter (LES) as determined by manometry.

It is recognized that patients may sometimes subconsciously alter their meals and physical activity during catheter-based 24 h pH monitoring. Recently, a wireless pH monitoring method has been devised that is more comfortable for the patient and thus less likely to affect the pH measurement. A wireless capsule (Bravo system, Medtronic, USA) containing an antimony electrode transmits esophageal pH data via radiofrequency telemetry to an external receiver worn by the patient (Figure 1). The capsule containing the pH sensor is introduced into the esophagus through the mouth with its own insertion mechanism and is attached to the esophageal mucosa 5 cm above the squamocolumnar junction (SCJ). It must be noted that some patients experience a vague chest discomfort or foreign body sensation while the capsule is in place. Other disadvantages of the wireless pH system are early capsule detachment and the need of a previous endoscopy to determine the position of the SCJ.

The catheter-based and capsule-based methods provide comparable results. Some patients who do not tolerate the catheter or whose lifestyle and eating patterns are significantly disrupted by the catheter may benefit from using the Bravo capsule instead. The capsule is also easy to use in children.

Reflux symptom association analysis

It is recognized that an abnormal number of acid reflux episodes or increased acid exposure does not automatically imply that acid reflux is the cause of the patient's symptoms. More importantly, a normal number of reflux events or normal acid exposure does not exclude reflux as the cause of the symptoms.

Several methods of symptom-reflux correlation have been devised to quantify the temporal relationship between acid reflux and symptoms. The symptom index and the symptom sensitivity index both use the number of symptoms and the number of acid reflux events to determine whether there is any association between the patient's symptoms and reflux. The symptom association probability (SAP) divides the 24 h period of monitoring into 2 min intervals (Figure 2). Each interval is classified into one of four categories:

1. Reflux-positive, symptom-positive;
2. Reflux-positive, symptom-negative;
3. Reflux-negative, symptom-positive; and
4. Reflux-negative, symptom-negative.

A Fisher's exact test is then performed and an SAP value of greater than 95% means that the association between symptoms and reflux can be attributed to chance less than 5% of the time. While all three indexes are suboptimal in predicting response to PPIs, the SAP appears to be the most clinically useful index.

Symptom-reflux association should be assessed in all patients undergoing pH-metry. All three indexes are usually calculated automatically by most pH-metry software programs on the market in North America and are helpful in reaching a diagnosis and guiding therapy.

Refractory GERD

Patients with heartburn or other symptoms typical of reflux who do not respond to PPIs represent a major clinical challenge for gastroenterologists today. Part of the problem rests in the fact that this is not a homogeneous group of patients. Some refractory GERD patients have erosive esophagitis with incomplete healing on PPIs, some have functional dyspepsia

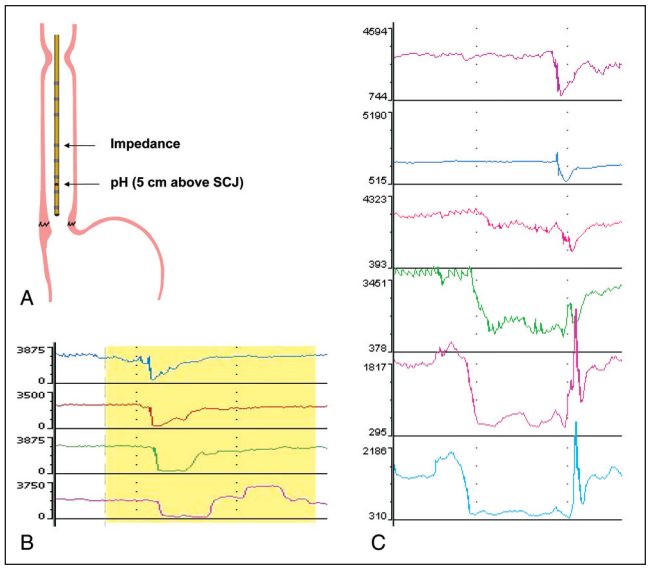

Figure 3) A *Combined impedance-pH catheter;* **B** *Impedance tracing showing antegrade movement of a liquid bolus, ie, a swallow;* **C** *Impedance tracing showing retrograde movement of a liquid bolus, ie, reflux. SCJ Squamocolumnar junction*

instead. However, a large group of patients fall into the category of NERD.

Often, NERD patients undergo a conventional 24 h pH study. There is still a great deal of controversy whether this test should be performed while taking PPIs; however, this discussion is beyond the scope of the present article. Regardless, if the rate of acid reflux into the esophagus over a 24 hour period is in the normal range, the patient may be told that his or her symptoms are not the result of acid reflux. This has been challenged in recent years with the introduction of esophageal impedance and the detection of weakly acidic reflux.

Esophageal impedance

Esophageal impedance is a technique based on measuring the flow of electrical current between closely arranged electrodes mounted on a thin intraluminal probe (Figure 3A). Pairs of electrodes representing an impedance segment are connected to an impedance voltage transducer, which delivers a measuring current. The impedance is inversely proportional to the electrical conductivity of the luminal contents and the cross-sectional area between the two electrodes. Air has a low conductivity and yields an impedance increase, while swallowed or refluxed material has a high conductivity and yields an impedance drop (Figure 3B). When the esophagus is empty, the impedance catheter measures the conductivity of the esophageal wall. As a result, impedance can be affected by mucosal inflammation and altered muscle tone.

Changes in temporal-spatial patterns in impedance are identified at various levels within the esophagus allowing differentiation between antegrade (ie, swallow) and retrograde (ie, reflux) bolus movement (Figure 3C). In this way, impedance can be used to evaluate intraesophageal liquid movements (bolus transit tests and reflux monitoring) or gas movement (aerophagia and belching). Currently, it is not possible to quantify the volume of gastroesophageal reflux using impedance.

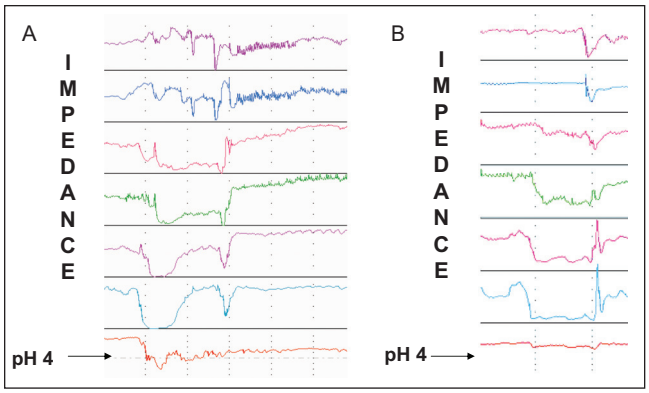

Figure 4) A *The impedance tracing shows that reflux is occurring while the pH tracing classifies the reflux as acidic.* **B** *The impedance tracing shows that reflux is occurring while the pH tracing classifies the reflux as weakly acidic*

Combined impedance-pH

Impedance and pH-metry can be combined into one catheter which can identify both when retrograde bolus movement (reflux) is occurring, as well as its acidity. Weakly acidic reflux, with a pH of between four and seven, cannot be identified by pH-metry alone, and has been found to cause at least some of the remaining symptoms in patients with refractory GERD (Figure 4). For example, an American multicentre study (1) of 168 patients with refractory GERD used ambulatory impedance-pH monitoring while 'on PPIs' and showed that 11% of patients had a positive SI for acid reflux and 37% had a positive SI for nonacid reflux. A French/Belgian multicentre study (2) found similar results and showed that adding impedance to pH monitoring improves diagnostic yield by 15% to 20% and allows better symptom analysis than pH-metry alone. Most patients whose symptoms are associated with weakly acidic reflux do not have an increased number of reflux events, suggesting that they have hypersensitivity of the esophagus to less acidic refluxate (3). Interestingly, the most important factor associated with perception of weakly acidic reflux is high proximal extent, suggesting an increased sensitivity of the proximal esophagus in certain patients (4).

Combined impedance-pH is useful in reaching a diagnosis in patients with refractory GERD. It has also focused research on potential alternate causes of symptoms, such as hypersensitivity, and therapies that can address them.

DYSPHAGIA

Patients with esophageal dysphagia complain of difficulty in swallowing, with food sticking or slow bolus transit. In those with solids-dysphagia, a barium x-ray and/or endoscopy is performed to rule out a structural cause, such as a stricture or a tumour. If no obstructive lesion is found, or if the dysphagia occurs with both solids and liquids, manometry, impedance or combined manometry-impedance testing is undertaken to look for abnormal motility and/or bolus transit.

High-resolution manometry

Esophageal manometry is considered to be the gold standard for diagnosing primary esophageal motility disorders such as achalasia, diffuse esophageal spasm (DES) and 'nutcracker' esophagus. The conventional manometry catheter has up to



Figure 5) *High-resolution manometry catheter*

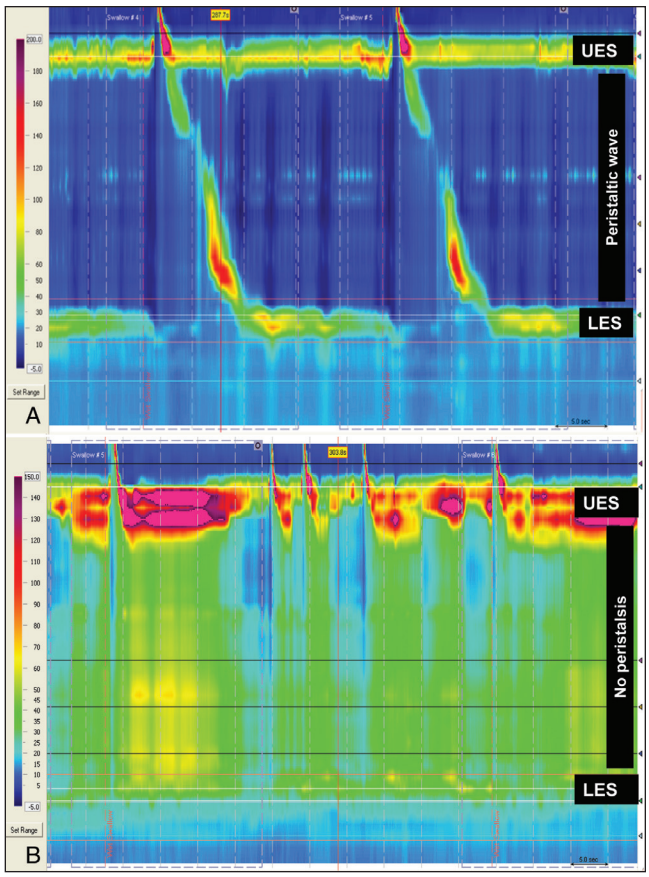

Figure 6) *High-resolution manometry (HRM) isocontour plots.* **A** *Normal swallow. Normal pressure in lower esophageal sphincter (LES) with adequate relaxation with swallowing. Normal propagation in esophageal body;* **B** *Achalasia. Elevated LES pressure. LES fails to relax with swallowing. All contractions in the esophageal body are simultaneous. UES Upper esophageal sphincter*

eight sensors, can be solid-state or water-perfused, and may have a sleeve to measure LES pressure. Compared with conventional manometry, high-resolution manometry (HRM) increases the amount and quality of information gathered by

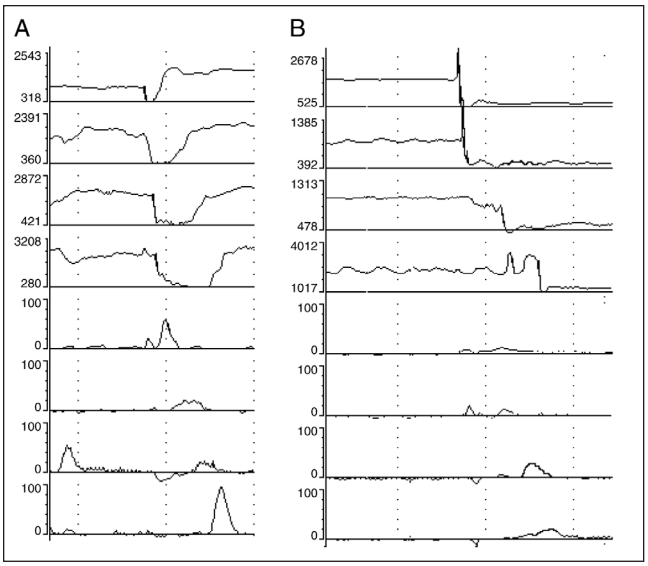

Figure 7) *Combined impedance-manometry.* **A** *Representative tracing of a swallow with ineffective esophageal motility (IEM) and normal bolus clearance,* **B** *Representative tracing of a swallow with IEM and abnormal bolus clearance. Figure reproduced with permission from Elsevier (reference 7)*

increasing the number of sensors and decreasing the space between them.

The HRM catheter typically has 32 sensor sites (Figure 5). In addition, each measuring site can have up to four sensors around the circumference of the catheter. The information gathered by the sensors may be displayed in a typical line plot; however, interpretation of the data would be confusing given the very large number of tracings. Instead, the data are converted to a spatiotemporal plot with time on the x-axis, position of the catheter on the y-axis, and pressure on the z-axis. This is in turn is converted by a computer into a colour-coded isocontour plot (Figure 6).

An HRM procedure takes less time to perform than conventional manometry because the high density of sensors across the LES functions as a pseudo-sleeve and removes the need for a pull-through for LES localization. The HRM plots are also easy to read and allow the reader to take into account potential confounders such as a hiatal hernia or esophageal shortening during a swallow. While an experienced clinician can make a diagnosis with either conventional or high resolution manometry, the latter is gaining in popularity due to its ease of use and interpretation.

Combined impedance-manometry

Historically, radiological contrast studies have been used to confirm that a manometrically-successful swallow did in fact lead to normal bolus transport and clearance. This method is cumbersome and of limited use due to exposure to radiation. With the introduction of impedance, it is now possible to gather the same information in a radiation-free and comfortable way for the patient. Impedance has been validated again by videofluoroscopy for its accuracy in determining bolus transit. Impedance and manometry sensors are combined into one catheter and the procedure is performed the same way as manometry alone.

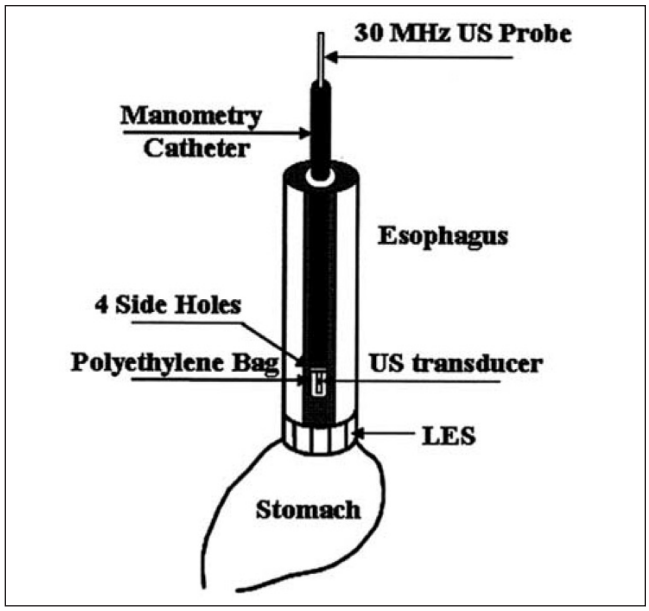

Figure 8) *High-frequency ultrasound (US) probe inside the middle channel of a manometry catheter. LES Lower esophageal sphincter. Reproduced with permission from Elsevier (reference 8)*

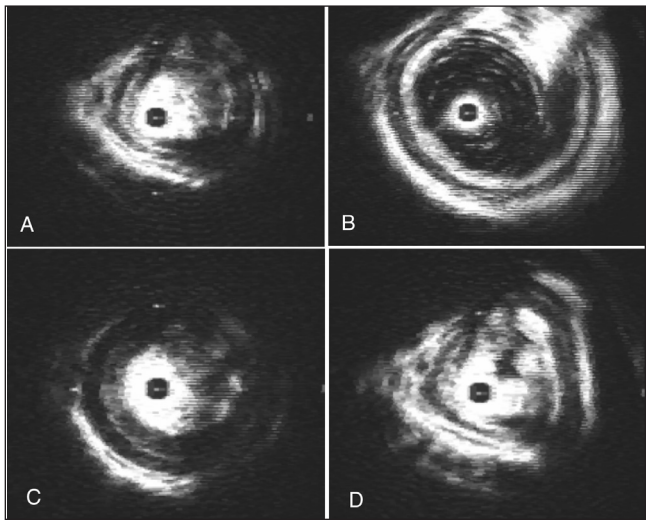

Figure 9) *High-frequency ultrasound cross-sectional views of the esophagus. Normal swallow at 2 cm above the lower esophageal sphincter (LES):* **A** *Lumen closed and empty between swallows;* **B** *Lumen wide open during a swallow as bolus passes through,* **C** *Contraction of peristalsis with thickening of both the longitudinal and circular muscle layers, lumen is closing;* **D** *Esophagus back to resting position after swallow with lumen closed*

Combined impedance-manometry is most useful in patients with ineffective esophageal motility (IEM) or DES. IEM refers to 30% or more of swallows having an amplitude below 30 mmHg in at least one of the two most distal manometry channels. IEM is often seen in GERD patients, although it is not reliably associated with symptoms. In GERD patients with IEM and dysphagia, combined impedance-manometry can determine whether IEM is causing abnormal bolus transit and contributing to the dysphagia (Figure 7).

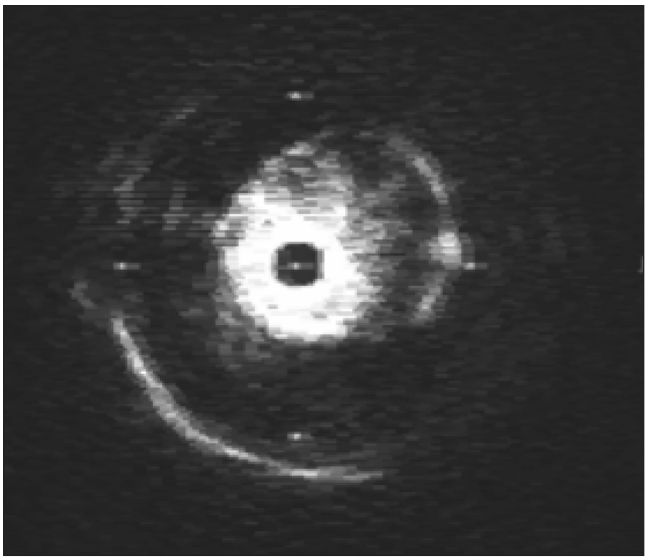

Figure 10) *High-frequency ultrasound cross-sectional view of abnormally thickened muscle layers in the lower esophageal sphincter of a patient with achalasia*

CHEST PAIN

Noncardiac chest pain is a common reason for a patient to be referred to a gastroenterologist. Normally, the patient has previously been investigated to rule out a cardiac cause for the pain. GERD is often present in these patients and, as such, 24 h pH-metry is often used. Symptom-reflux association analysis is particularly helpful given that there are other nonreflux conditions in the differential diagnosis.

Noncardiac chest pain is also present in patients with spastic motor disorders, such as DES, nutrcracker esophagus and achalasia. These conditions are usually diagnosed with manometry. In recent years, high-frequency ultrasound has been used to study the underlying pathophysiology of these motor disorders and holds promise in evaluating future therapies.

High-frequency ultrasound

High-frequency ultrasound consists of a probe, just over 1 mm in diameter, that operates at a frequency of 30 MHz (Figure 8). This device is also used in cardiology for intracoronary echocardiography. Due to the delicate nature of the probe, it is usually inserted into the middle channel of a manometry catheter to aid transnasal introduction into the esophagus. The manometry catheter also helps in determining the location of the LES and standardizes the locations where ultrasound images are taken (Figure 9). Dogan et al (5) have used high-frequency ultrasound to look at both the circular and longitudinal muscle layers of the esophagus. There appears to be a spectrum of increasing thickness of both muscle layers and of the LES ranging from healthy volunteers to DES, nutcracker esophagus, and finally to achalasia (Figure 10). In advanced achalasia, the esophageal wall thins out as the lumen is grossly enlarged, yet the cross-sectional area of the muscle layer is still much greater than in healthy volunteers. However, discrete diagnostic ranges particular to any one condition have yet to be determined.

During a normal swallow, the circular and longitudinal muscles contract in synchrony. In spastic motor disorders, there can be asynchrony in the timing and amplitude of contractions of the muscle layers giving rise to symptoms. For example, prolonged contractions of the longitudinal muscle have been observed to cause chest pain. Longitudinal muscle contraction also causes esophageal shortening and an axial stretch of the LES leading to relaxation. High-frequency ultrasound is currently being used to study the relationship among esophageal shortening, transient LES relaxations and reflux. It may be that some patients with chest pain and reflux who are not responding to PPI could benefit from therapies that target transient LES relaxations and longitudinal muscle contractions.

SUMMARY

Clinicians currently have several new techniques, in addition to refinements of old techniques, available for the diagnosis of esophageal disorders. Some of these techniques can be used in combination to gather additional information about a patient's condition. They also continue to provide new insights into normal esophageal motor function and the pathophysiology of primary motility disorders.

REFERENCES

1. Mainie I, Tutuian R, Shay S, et al. Acid and non-acid reflux in patients with persistent symptoms despite acid suppressive therapy: A multicentre study using combined ambulatory impedance-pH monitoring. Gut 2006;55:1398-402.
2. Zerbib F, Roman S, Ropert A, et al. Esophageal pH-impedance monitoring and symptom analysis in GERD: A study in patients off and on therapy. Am J Gastroenterol 2006;101:1956-63.
3. Katz P, Gideon RM, Tutuian R. Reflux symptoms on twice daily (BID) proton pump inhibitor (PPI) associated with non acid reflux: A manifestation of hypersensitive esophagus? Gastroenterology 2005;128:A130 (Abst).
4. Zerbib F, Duriez A, Roman S, Capdepont M, Mion F. Determinants of gastroesophageal reflux perception in patients with persistent symptoms despite proton pump inhibitors. Gut 2007;57:157-60
5. Dogan I, Puckett JL, Padda BS, Mittal RK. Prevalence of increased esophageal muscle thickness in patients with esophageal symptoms. Am J Gastroenterol 2007;102:137-45.
6. Bredenoord AJ, Wuesten BL, Smout AJ. Symptom association analysis in ambulatory gastroesophageal reflux monitoring. Gut 2005;54:1810-7.
7. Tutian R, Castell DO. Esophageal function testing: Role of combined multichannel intraluminal impedance and manometry. Endosc Clin N Am 2005;15:265-75.
8. Hwoon-Yong J, Puckett JL, Bhalla V, Rojas-Feria M, et al. Asynchrony between the circular and longitudinal muscle contraction in patients with nutcracker esophagus. Gastroenterology 2005;128:1179-86.