

Dicrocoelium dendriticum infection in a patient with Crohn's disease

Franzjosef Schweiger MD FRCPC FACP FACG, Magdalena Kuhn MD FRCPC

F Schweiger, M Kuhn. *Dicrocoelium dendriticum* infection in a patient with Crohn's disease. *Can J Gastroenterol* 2008;22(6): 571-573.

Infection with *Dicrocoelium dendriticum* in humans is rarely reported in the medical literature. This liver fluke, which commonly infects ruminants, has a complex life cycle with two intermediate hosts – the land snail and the ant. True human infection occurs by ingestion of the second intermediate host, but spurious infections have occurred after consumption of undercooked animal liver. The present report describes a patient with active Crohn's disease whose stool contained *D dendriticum* eggs. A brief discussion of the medical literature is presented.

Key Words: *Dicrocoelium dendriticum*; *Lancet fluke*; *Liver fluke*

Dicrocoelium dendriticum is a terrestrial bile fluke of herbivorous animals such as sheep, cows, goats, deer and rabbits (1). Its characteristic slender, leaf-like shape earned it the name lancet fluke, a small trematode with a complex and interesting life cycle (Figure 1). Adult flukes live in the gallbladder and bile ducts of ruminants.

True human infection is rare and results from ingestion of the second intermediate host, the field ant, which is found in grass, herbs, raw fruit, vegetables or even drinking water (2). Spurious infection is the consequence of eating raw or undercooked animal liver, in which case, the eggs pass through the digestive tract unchanged.

We report a case of a 49-year-old man with Crohn's disease whose stool analysis revealed the presence of *D dendriticum* before starting infliximab therapy.

CASE PRESENTATION

A 49-year-old man presented with diarrhea and a 12 kg weight loss over several months. He had a 17-year history of Crohn's disease and underwent a right hemicolectomy for ileocecal obstruction one year earlier. He had known anal fissures and four previous drainage procedures for perianal abscesses over the course of his disease.

Six weeks before referral, he was started on prednisone 40 mg per day, but attempts to reduce the dose to 20 mg per day resulted in exacerbation of his diarrhea. He had up to

Une infection par *Dicrocoelium dendriticum* chez un patient atteint de la maladie de Crohn

L'infection par *Dicrocoelium dendriticum* chez les humains est rarement déclarée dans les publications médicales. Cette douve du foie, qui infecte souvent les ruminants, a un cycle de vie complexe et est doté de deux hôtes intermédiaires : le limaçon et la fourmi. La véritable infection des humains se produit par ingestion du deuxième hôte intermédiaire, mais de fausses infections se sont produites après l'ingestion du foie mal cuit d'animaux. Le présent rapport décrit le cas d'un patient atteint d'une maladie de Crohn active dont les selles contenaient des œufs de *Dicrocoelium dendriticum*. Un bref exposé des publications médicales est présenté.

eight loose, nonbloody bowel movements per day and nocturnal diarrhea, accompanied by lower abdominal and perianal pain.

His medication included mesalamine 4 g/day, azathioprine 50 mg/day, iron supplementation and monthly vitamin B₁₂ injections. He had been taking diclofenac sodium-misoprostol for eight years for lower back pain, and he smoked one package of cigarettes per day.

He denied fever, night sweats or any extraintestinal manifestations of inflammatory bowel disease.

He admitted to consuming beef liver several times per year, but denied that these organ meats were undercooked or consumed within the past few weeks before presentation.

Physical examination revealed right lower quadrant abdominal tenderness but no mass. There were perianal skin tags and fissures but no fistulae.

The complete blood count and C-reactive protein level were normal, and there was no eosinophilia.

Serum electrolyte, glucose, liver enzyme and albumin levels were normal. Serum vitamin B₁₂ was reduced to 159 pmol/L (normal 171 pmol/L to 571 pmol/L) and ferritin level was 17 µg/L (normal 20 µg/L to 250 µg/L).

Stool examination for ova and parasites revealed many *D dendriticum* eggs (Figure 2).

Computed tomography of the abdomen showed segmental stenosis of the terminal ileum over a distance of 8 cm.

Department of Internal Medicine and Department of Laboratories, South East Health Care Corporation, The Moncton Hospital, Moncton, New Brunswick

Correspondence and reprints: Dr Franzjosef Schweiger, 100 Arden Street, Suite 405, Moncton, New Brunswick E1C 4B7.

Telephone 506-858-8441, fax 506-858-0859, e-mail fschweig@nb.sympatico.ca

Received for publication January 12, 2008. Accepted March 19, 2008

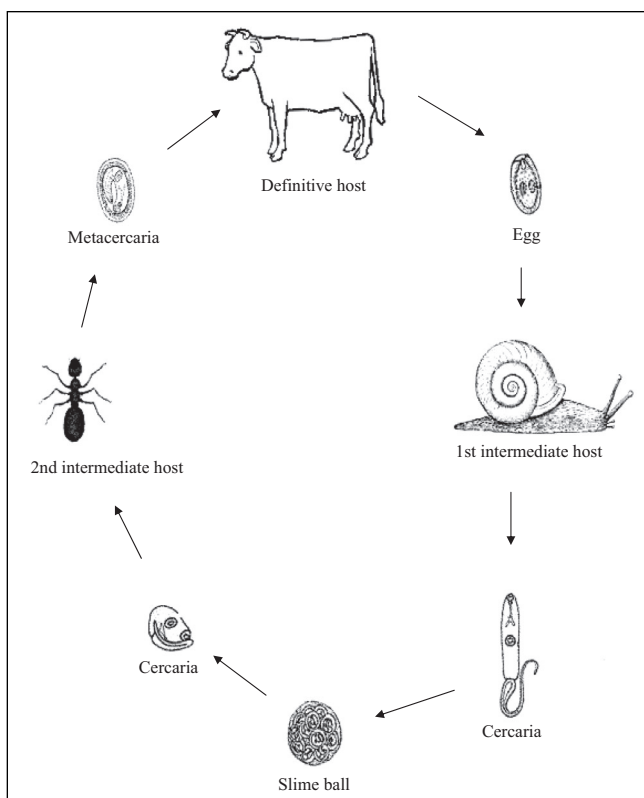


Figure 1) Life cycle of the lancet fluke. The adult fluke lives in the gallbladder and bile ducts of its final host, a herbivore. Eggs are passed in the feces and swallowed by the first intermediate host, a land snail. Miracidia emerge inside the snail's intestine and develop into cercariae after approximately three to four months. Cercariae are subsequently excreted into the environment in slime balls, a favoured food of ants, which are the second intermediate hosts. Once ingested by ants, the swallowed cercariae develop into metacercariae in the hemocoel of the insect, and are infective to any definite host that might accidentally ingest ants while grazing. Some metacercariae, however, encyst in the subesophageal ganglion, a part of the ant's brain, where they dramatically affect the behaviour of the ant – instead of returning to its burrow when the daytime temperature falls, the infected ant moves up to the top of a blade of grass, where it clamps its mandibles into the plant and remains paralyzed as long as the temperature remains below 20°C. As a result, the ant becomes the prime target of accidental ingestion by grazing animals and the continued survival of the fluke is ensured. In the duodenum of the final host, metacercariae excyst and develop into flukes, which migrate into the common bile duct. The adult fluke, a hermaphrodite, matures in six to seven weeks and produces eggs, thus completing the life cycle (13)

Colonoscopy showed a normal colon, but the anastomosis was narrowed and ulcerated, not allowing advancement of the instrument more than 2 cm into the neoterminal ileum.

Iron and vitamin B₁₂ were administered, and diclofenac sodium-misoprostol treatment was discontinued. Praziquantel 25 mg/kg three times daily was administered orally for three days. Five further stool samples were negative for ova and parasites, but his symptoms did not improve.

The dose of azathioprine was increased to 125 mg/kg/day (2 mg/kg) and infliximab was infused intravenously (5 mg/kg), and repeated two and six weeks later. Review at that time revealed that he felt much better, had two formed bowel movements per day and had gained 3.2 kg.

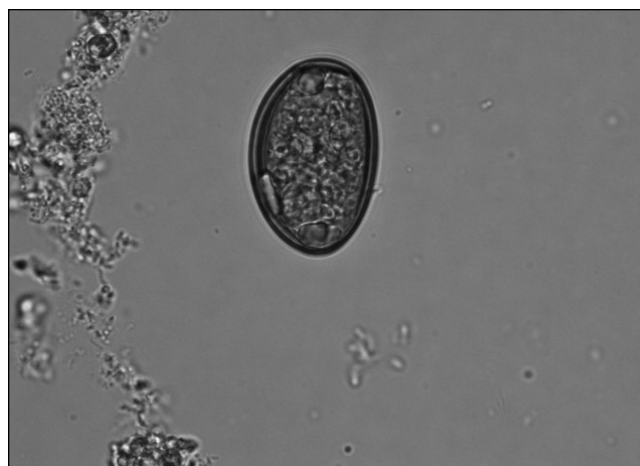

Figure 2) *Dicrocoelium dendriticum* egg ($\times 1000$ magnification, wet mount preparation, original magnification). Eggs are small ($20\ \mu\text{m} \times 35\ \mu\text{m}$ to $50\ \mu\text{m}$), thick-shelled and dark brown in colour

His Crohn's disease is currently stable on azathioprine and infliximab infusions every two months.

DISCUSSION

Although previously identified in North America, Asia and Africa, most reports of human infection by *D dendriticum* originate in Europe and the Middle East, where the lancet fluke is a common parasite in sheep and cattle. This small liver fluke is not rare in Atlantic Canada, where archaeological findings suggest that it has been in Newfoundland since at least the 17th century (3). Recently, it was also found to be well established in southern Alberta (4). However, human infection has not been previously reported in Canada.

Most human cases represent spurious infections, reflecting the gastrointestinal passage of parasite eggs by consumption of infected animal liver.

In a four-year study from Switzerland (5), where the lancet fluke is a common parasite in sheep and cattle, the annual incidence of human stool specimens positive for *D dendriticum* was between 0.2% and 0.38%, but no true human infection could be documented. A report from Saudi Arabia (6) described 121 patients' stools as being positive for *D dendriticum*. The authors suggested that 32 of the 121 patients had true dicrocoeliasis, because their stools were still positive for the parasite after three days on a liver-free diet.

In another study from Saudi Arabia (7), 208 patients were reported to carry the eggs of the parasite in their stools for three years. The authors claim that at least seven of these patients had a true infection.

Although our patient denied recent ingestion of animal liver, he admitted that he consumed such food several times per year. We suspect that he passed *Dicrocoelium* eggs in his stool after possibly inadvertent consumption of infected liver, in keeping with a pseudoparasitic infection. True human infection is acquired by ingesting the field ant, which can occur after drinking contaminated water, or eating salads or raw vegetables containing infected ants. The present patient reported no history of recent ant ingestion.

Symptoms of true human infection are often absent or mild, but may include constipation, chronic diarrhea, vomiting and

abdominal pain (8,9). Hepatomegaly and peripheral eosinophilia have been reported (7,9). Infection by this fluke can present as biliary obstruction and cholangitis (10).

We could not find any previous reports of Crohn's disease and dicrocoeliasis, and believe that the present case likely represents a coincidental occurrence. Although two cases of patients infected with HIV and *D dendriticum* have been reported in the literature (11,12), there is no indication that our patient's immunosuppressive therapy had any influence on his clinical course. His symptoms did not improve after successful treatment with praziquantel, but responded rapidly to infliximab infusions, indicating that his symptoms were largely related to his underlying Crohn's disease. Generally,

there is no need to initiate antiparasitic treatment in patients who pass *Dicrocoelium* eggs after ingesting contaminated liver, but we decided to treat the present patient with praziquantel and confirm the absence of eggs in the stool, because of his immunosuppressed state and the concern about further immune interference with the introduction of infliximab therapy.

CONCLUSIONS

The present report underlines the importance of screening the stool of patients with inflammatory bowel disease and diarrhea for underlying, often unsuspected parasitic infections, particularly if immunosuppressive treatments are administered.

REFERENCES

1. Burger NC, Nesvadba J, Nesvadba Z, Busato A, Gottstein B. [The incidence of *Dicrocoelium dendriticum* in Emmmental.] Berl Munch Tierarztl Wochenschr 2006;119:324-9.
2. Haridy FM, Morsy TA, Ibrahim BB, Abdel-Aziz A. A preliminary study on dicrocoeliasis in Egypt, with a general review. J Egypt Soc Parasitol 2003;33:85-96.
3. Peacock A. *Dicrocoelium dendriticum* – the lancet fluke of sheep. Animal diseases fact sheet. Publication AP059. Department of Natural Resources, Government of Newfoundland and Labrador, 2004. <http://www.nr.gov.nl.ca/agric/animal_diseases/domestic/pdf/dicro.pdf> (Version current at April 18, 2008).
4. Goater CP, Colwell DD. Epidemiological characteristics of an invading parasite: *Dicrocoelium dendriticum* in sympatric wapiti and beef cattle in southern Alberta, Canada. J Parasitol 2007;93:491-4.
5. Stahel E. [Spurious infections by the small liver fluke (*Dicrocoelium dendriticum*) in Switzerland 1976-1980.] Schweiz Med Wochenschr 1981;111:1159-62.
6. Helmy MM, Al-Mathal EM. Human infection with *Dicrocoelium dendriticum* in Riyadh district (Saudi Arabia). J Egypt Soc Parasitol 2003;33:139-44.
7. el-Shiekh Mohamed AR, Mummery V. Human dicrocoeliasis. Report on 208 cases from Saudi Arabia. Trop Geogr Med 1990;42:1-7.
8. Jelinek T, Rack J, Adusu E. [Human infection with *Dicrocoelium dendriticum*.] Deut Med Wochenschr 2004;129:2538-40.
9. Ondriska F, Sobota K, Janosek J, Joklova E. [A rare case of human autochthonous dicrocoeliasis in Czechoslovakia.] Bratisl Lek Listy 1989;90:467-9.
10. Karadag B, Bilici A, Doventas A, et al. An unusual case of biliary obstruction caused by *Dicrocoelium dendriticum*. Scand J Infect Dis 2005;37:385-8.
11. Drabick JJ, Egan JE, Brown SL, Vick RG, Sandman BM, Neafie RC. Dicrocoeliasis (lancet fluke disease) in an HIV seropositive man. JAMA 1988;259:567-8.
12. Zali MR, Mehr AJ, Rezaian M, Meamar AR, Vaziri S, Mohraz M. Prevalence of intestinal parasitic pathogens among HIV-positive individuals in Iran. Jpn J Infect Dis 2004;57:268-70.
13. Sing A. Of ants and men (an antology). Clin Infect Dis 2007;44:145-6.



Hindawi
Submit your manuscripts at
<http://www.hindawi.com>

