ORIGINAL ARTICLE

The potential impact of contemporary developments in the management of patients with gastroesophageal reflux disease undergoing an initial gastroscopy

Suhail B Salem MDCM[1], Yael Kushner MDCM[2], Victoria Marcus MDCM FRCPC[2], Serge Mayrand MDCM FRCPC[1], Carlo A Fallone MDCM FRCPC AGAF[1], Alan N Barkun MDCM FRCPC FACP FACG AGAF FASGE MSc[1]

SB Salem, Y Kushner, V Marcus, S Mayrand, CA Fallone, AN Barkun. The potential impact of contemporary developments in the management of patients with gastroesophageal reflux disease undergoing an initial gastroscopy. Can J Gastroenterol 2009;23(2):99-104.

BACKGROUND: Recent developments may alter the approach to patients presenting with gastroesophageal reflux disease (GERD)-like symptoms. A newly proposed Montreal consensus definition of Barrett's esophagus includes all types of esophageal columnar metaplasia, with or without intestinal-type metaplasia. There is also increasing recognition of eosinophilic esophagitis (EE) in patients with GERD-like symptoms.
OBJECTIVE: To quantify the impact of these developments on a multiphysician general gastroenterology practice in a tertiary care medical centre.
METHODS: Medical charts of all patients having an initial gastroscopy for GERD-like symptoms over a one-year period were reviewed retrospectively, and audits of their endoscopic images and esophageal biopsies were performed.
RESULTS: Of the 353 study participants, typical symptoms of heartburn and acid reflux were present in 87.7% and 23.2%, respectively. Less commonly, patients presented with atypical symptoms (eg, dysphagia in 9.4%). At endoscopy, 26% were found to have erosive esophagitis and 12% had endoscopically suspected esophageal metaplasia. Histological evaluation was available for 65 patients. Ten of the 65 biopsied patients (15%) met traditional criteria for Barrett's esophagus (ie, exhibiting intestinal-type metaplasia), whereas 49 (75%) fulfilled the newly proposed consensus definition of Barrett's esophagus. Five patients (7.7%) met the study criteria for EE (more than 20 eosinophils per high-power field), four of whom had not been previously recognized.
CONCLUSIONS: Among patients presenting with GERD-like symptoms, the prevalence of Barrett's esophagus may increase markedly if the Montreal definition is adopted. In addition, growing awareness of EE may lead to an increase in the prevalence of this diagnosis. Prospective studies of the management implications of these findings are warranted.

Key Words: *Barrett's esophagus; Eosinophilic esophagitis; Gastroesophageal reflux disease (GERD)*

Impact potentiel des récents développements sur la prise en charge des patients souffrant de reflux gastro-œsophagien soumis à une première gastroscopie

HISTORIQUE : De récents développements pourraient modifier l'approche aux symptômes de type reflux gastro-œsophagien (RGO). Selon la nouvelle définition consensuelle de Montréal, l'œsophage de Barrett inclut tous les types de métaplasies cylindriques œsophagiennes, avec ou sans métaplasie intestinale. On reconnaît en outre de plus en plus l'œsophagite éosinophilique (OÉ) chez les patients qui présentent des symptômes de type RGO.
OBJECTIF : Mesurer l'impact de ces changements sur la polyclinique de gastro-entérologie générale d'un centre hospitalier de soins tertiaires.
MÉTHODES : Les dossiers médicaux de tous les patients ayant subi une première gastroscopie pour des symptômes de type RGO sur une période d'un an ont été passés en revue de manière rétrospective et les auteurs ont examiné les clichés endoscopiques et les biopsies œsophagiennes.
RÉSULTATS : Parmi les 353 cas étudiés, les auteurs ont relevé des symptômes typiques de brûlure d'estomac et de reflux acide chez 87,7 % et 23,2 % des sujets, respectivement. Plus rarement, les patients présentaient des symptômes atypiques (p. ex., dysphagie chez 9,4 %). À l'endoscopie, 26 % se sont révélés porteurs d'une œsophagite érosive et 12 % présentaient une métaplasie œsophagienne soupçonnée à l'endoscopie. On disposait des résultats de l'examen histologique pour 65 patients. Dix patients sur les 65 qui ont subi la biopsie (15 %) répondaient aux critères classiques de l'œsophage de Barrett (c.-à-d., métaplasie intestinale), tandis que 49 (75 %) répondaient à la nouvelle définition consensuelle de l'œsophage de Barrett. Cinq patients (7,7 %) répondaient aux critères de l'étude pour l'OÉ (plus de 20 éosinophiles par champ à fort grossissement), dont quatre n'avaient pas encore été diagnostiqués.
CONCLUSIONS : Parmi les patients qui se présentent avec des symptômes de type RGO, la prévalence de l'œsophage de Barrett pourrait connaître une augmentation marquée si l'on adopte la définition de Montréal. De plus, une meilleure connaissance de l'OÉ pourrait aussi donner lieu à une augmentation de sa prévalence. Des études prospectives sur les répercussions thérapeutiques de telles observations s'imposent.

Recent developments have the potential to alter the current approach to patients with suspected gastroesophageal reflux disease (GERD). First, there is an increased recognition of atypical presenting symptoms. Second, a controversial revision of the definition of Barrett's esophagus was recently proposed (1). Finally, recent data suggest that eosinophilic esophagitis (EE) may be more prevalent than previously recognized among patients with GERD-like symptoms (2).

The recent consensus paper by Vakil et al (1) proposed the Montreal definition and classification of GERD. This population of patients with GERD is increasingly being recognized as having a variety of symptoms apart from heartburn and regurgitation, including dysphagia, atypical chest pain and hoarseness, which are all now more frequently investigated as part of suspected GERD. Furthermore, the recommendations from this International Consensus Group suggested a significant change

[1]*Division of Gastroenterology;* [2]*Department of Pathology, McGill University Health Centre, McGill University, Montreal, Quebec*
Correspondence: Dr Alan N Barkun, McGill University Health Centre, Division of Gastroenterology and Clinical Epidemiology, Montreal General Hospital Site, Room D7-148, 1650 Cedar Avenue, Montreal, Quebec H3G 1A4. Telephone 514-934-8233, fax 514-934-8375, e-mail alan.barkun@muhc.mcgill.ca
Received for publication March 28, 2008. Accepted November 4, 2008

to the histological definition of Barrett's esophagus. In brief, the participating experts proposed that the definition of Barrett's esophagus be expanded to include all types of columnar metaplasia noted on histology, and that the presence or absence of intestinal metaplasia (IM) be specified (1). This new 'Montreal definition' of Barrett's esophagus, however, was the most contentious topic among the participants at the meeting and its application remains a controversial issue.

In addition, it has become increasingly recognized that EE may present with GERD-like symptoms (2). In spite of this, it is unclear how frequently EE goes unrecognized in patients with GERD-like symptoms, especially in adults. Appropriate targeted treatment for EE, such as the use of systemic or topical glucocorticoids, leads to symptomatic and histological improvement, while patients incorrectly diagnosed with another condition such as GERD may continue to experience EE-related symptoms with ongoing evidence of esophageal injury (2).

These developments thus bear the potential to alter our current approach to patients presenting with GERD-like symptoms. The purpose of the present study was to assess the impact of such considerations in a general multiphysician, hospital-based, gastroenterology practice, by reviewing a cohort of patients referred for GERD-like symptoms undergoing an initial endoscopy. In particular, the present study aimed to determine the impact of the Montreal definition of Barrett's esophagus and the possible underdiagnosis of EE in a typical patient population managed by gastroenterologists.

METHODS

Patient population

An audit of all patients undergoing a gastroscopy for a recorded indication of GERD-like symptoms (3), over a one-year period ending November 2006, was undertaken. Patients were excluded if they had undergone a previous gastroscopy for GERD. All medical charts and endoscopic reports were retrospectively reviewed using a standardized data abstraction form by one research associate, while independent prospective reviews of all available endoscopic images (grading of esophagitis and endoscopically suspected endoscopic metaplasia [ESEM]) and esophageal biopsies were performed by a single digestive endoscopist (A Barkun) and two experienced pathologists (Y Kushner and V Marcus). The study adhered to the ethical standards of McGill University, Montreal, Quebec.

Historical information

Patients were identified using an institutional electronic endoscopy database, and related charts were reviewed retrospectively. The clinical information included demographic information and the presence of symptoms (including heartburn, acid regurgitation, atypical chest pain, dysphagia, nocturnal symptoms, sleep disturbance, cough, asthma, hoarseness and other complaints). Ongoing intake of medications (proton pump inhibitors, H_2 receptor antagonists, antacids, as well as acetylsalicylic acid and nonsteroidal anti-inflammatory medications) and patient habits (alcohol use and smoking) were also noted.

Endoscopic findings

Endoscopic findings were categorized as nonerosive or erosive esophagitis. The presence or absence of ESEM was noted using established criteria (1). Endoscopic esophagitis was independently classified prospectively by an expert endoscopist blinded to all other data, according to the Los Angeles (LA) classification, using available photodocumentation (4). ESEM was similarly independently and prospectively classified as long segment, short segment or ultra-short segment using published definitions (5). The presence or absence of strictures was also noted, as were other findings (eg, hiatal hernia, Schatzki's ring, etc).

Histological analysis

A review of every esophageal biopsy specimen was independently undertaken by two digestive pathologists blinded to all other data. The biopsies had been fixed in 10% buffered formalin, processed routinely and stained with hematoxylin and eosin. All fragments from each biopsy site were evaluated. Two slides from each biopsy site were prepared. The type of mucosa was classified as pure squamous, pure glandular (cardiac, oxyntocardiac or oxyntic mucosa), or admixed squamous and glandular mucosa, as previously described (6). The evaluation of the glandular component also included the assessment of the presence or absence of IM, as characterized by the presence of goblet cells. The biopsy fulfilled the Montreal definition of Barrett's esophagus if it contained any cardiac or oxyntocardiac mucosa with or without IM (1,6). All slides were also scanned to identify the area with the highest density of eosinophils. This area was used to count the number of eosinophils per high-power field (hpf; Olympus BX40 microscope [Olympus, Japan]; UPlanFL 40× lens, ocular magnification 10×; area of microscopic field 0.34 mm^2). The eosinophil count included intact eosinophils and degranulated eosinophils if the cluster of granules was discretely localized and interpretable as deriving from a single eosinophil. The presence of eosinophil microabscesses (defined as aggregates of four or more contiguous eosinophils) was noted. EE was defined as greater than 20 eosinophils per hpf (7,8). To rule out the presence of possible fungal organisms, Grocott's silver and periodic acid-Schiff with diastase stains were also performed, when indicated.

Statistical analysis

Categorical variables are reported as proportions with the appropriate numerators and denominators, and 95% CIs using the normal approximation of the binomial distribution. Continuous variables are reported as means and SDs.

RESULTS

Patient characteristics

In total, 353 patients underwent a gastroscopy between November 1, 2005, and October 31, 2006, for an initial investigation of GERD-like symptoms (Table 1). The mean (± SD) age of patients was 53.3±15.4 years (range 16 to 94 years), and 194 (55%) were women. A chart review revealed details of presenting symptoms in 311 patients. Typical symptoms of heartburn and acid regurgitation were found in 87.7% (95% CI 84% to 91%) and 23.2% (95% CI 19% to 28%) of these patients, respectively. Nocturnal symptoms were noted in 11.3% (95% CI 7.9% to 15%), dysphagia in 9.4% (95% CI 6.2% to 13%), hoarseness in 5.5% (95% CI 3.3% to 8.3%), atypical chest pain in 4.2% (95% CI 2.4% to 6.9%), sleep disturbance in 2.9% (95% CI 1.4% to 5.1%), chronic cough in 2.6% (95% CI 1.2% to 4.8%) and asthma-related symptoms in 1.3% (95% CI 0.46% to 3.3%). Fifty-six per cent (95% CI 50% to 63%) of all patients were noted to be taking a proton-pump inhibitor (PPI) before endoscopy.

Endoscopic findings

Endoscopic findings are listed in Table 2; 92 patients (26%, 95% CI 21% to 31%) were noted to have erosive esophagitis.

TABLE 1
Patient characteristics (n=353)

Characteristic	n (%)	95% CI
Age, years, mean ± SD (range) 53.3±15.4 (16–94)	–	–
Women	194 (55)	50–60
GERD-related symptoms (n=311)		
Heartburn	272 (87.7)	84–91
Regurgitation	72 (23.2)	19–28
Nocturnal symptoms	35 (11.3)	7.9–15
Dysphagia	29 (9.4)	6.2–13
Hoarseness	17 (5.5)	3.3–8.3
Atypical chest pain	13 (4.2)	2.4–6.9
Sleep disturbance	9 (2.9)	1.4–5.1
Cough	8 (2.6)	1.2–4.8
Asthma	4 (1.3)	0.46–3.3
Other symptoms		
Abdominal pain	38 (12)	8.4–16
Bloating	17 (5.5)	3.2–8.6
Nausea and vomiting	11 (3.5)	1.8–6.2
Dyspepsia	6 (1.9)	0.71–4.2
Odynophagia	2 (0.64)	0.078–2.3
Globus	2 (0.64)	0.078–2.3
Sore throat	1 (0.32)	0.01–1.8
Habits		
Smoking (n=190)	34 (18)	12–24
Regular alcohol use (n=186)	58 (31)	24–38
Medication use (n=250)		
Taking a PPI before consultation	141 (56)	50–63
Taking a H_2 receptor antagonist before consultation	14 (5.6)	3.1–9.2
Taking antacids before consultation	29 (12)	7.4–16
On no medications for GERD	82 (33)	27–39
Taking acetylsalicylic acid	34 (14)	9.1–18
Taking NSAIDs	17 (6.8)	4–11
Taking alendronate sodium	11 (4.4)	2.2–7.7

GERD Gastroesophageal reflux disease; NSAIDs Nonsteroidal anti-inflammatory drugs; PPI Proton pump inhibitor

TABLE 2
Endoscopic findings

Finding	n (%)	95% CI
Erosive esophagitis (n=353)	92 (26)	21–31
Los Angeles class A (n=83)	52 (63)	51–73
Los Angeles class B (n=83)	28 (34)	25–45
Los Angeles class C (n=83)	1 (1.2)	0.03–6.5
Los Angeles class D (n=83)	2 (2.4)	0.2–8.4
ESEM (n=353)	41 (12)	8.1–15
Ultra-short segment (n=40)	10 (25)	13–41
Short segment (n=40)	24 (60)	43–75
Long segment (n=40)	6 (15)	5.7–30
Eosinophilic esophagitis (n=353)	3 (0.76)	0.16–2.2
Other findings (n=353)		
Stricture	2 (0.6)	0.07–2
Gastritis	82 (23)	19–28
Duodenitis	15 (4.2)	2.4–6.9
Hiatus hernia	87 (25)	20–29
Schatzki ring	13 (3.7)	2–6.2
Gastric polyps	14 (4)	2.2–6.6

ESEM Endoscopically suspected esophageal metaplasia

TABLE 3
Histological findings

Finding	n (%)	95% CI
Barrett's esophagus – traditional definition	10 (15)	7.6–27
Barrett's esophagus – Montreal definition	49 (75)	63–85
Eosinophilic esophagitis	5 (7.7)	2.5–17

LA class grading could not be determined for nine patients due to inadequate photodocumentation. Among the 83 remaining patients with erosive esophagitis, 52 (63%; 95% CI 51% to 73%) were categorized as LA class A, 28 (34%; 95% CI 24% to 45%) as class B, one (1.2%; 95% CI 0.03% to 6.5%) as class C, and two (2.4%; 95% CI 0.29% to 8.4%) as class D. Forty-one patients (12%; 95% CI 8.1% to 15%) had ESEM. The length of ESEM could be determined in all but one patient; long segment was present in six (15%; 95% CI 5.7% to 30%), short segment in 24 (60%; 95% CI 43% to 75%), and ultra-short segment in 10 (25%; 95% CI 13% to 41%). Three patients (0.76%; 95% CI 0.16% to 2.2%) were suspected of having EE as noted on the endoscopy report because of the appearance of felinization and/or furrowing (9,10).

Pathology results

The esophageal biopsies of 65 patients (18%; 95% CI 14% to 23%) were available for evaluation, including 34 of 41 patients (83%; 95% CI 68% to 93%) with ESEM. Of these, 63 (97%; 95% CI 89% to 100%) had biopsies of the squamocolumnar junction, while six patients (1.7%; 95% CI 0.6% to 3.7%) also had biopsies of the esophagus proximal to the squamocolumnar junction. Two patients (0.57%; 95% CI 0.069% to 2%) had biopsies of the mid esophagus only. EE was suspected in three cases, but a biopsy was taken in only one of these cases. Between one and 11 fragments (mean 3±2.1 fragments) were evaluated from each biopsy site. Two slides were available from each biopsy site, with each slide displaying two to four levels. Pathological findings are shown in Table 3.

Ten of the 65 biopsied patients (15%; 95% CI 7.6% to 27%), including 24% (95% CI 11% to 41%) among those with ESEM, met traditional histological criteria for Barrett's esophagus with intestinal-type metaplasia identified. In contrast, 49 patients (75%; 95% CI 63% to 85%), including 97% (95% CI 85% to 100%) of those with ESEM, met the proposed criteria for the Montreal definition of Barrett's esophagus (14%; 95% CI 9.9% to 17.3% of the entire study population) (Figure 1).

Eosinophils were found in the biopsies of 30 of the 65 patients (46%; 95% CI 34% to 59%), of which 29 demonstrated a diffuse distribution, and one a peripapillary distribution. Five of the 65 patients (7.7%; 95% CI 2.5% to 17%) met the prestudy specified criteria for EE, representing 1.4% (95% CI 0.46% to 3.3%) of the entire study population. Four of the five patients with eosinophilic esophagitis also had eosinophilic microabscesses (6.2%; 95% CI 1.7% to 15%).

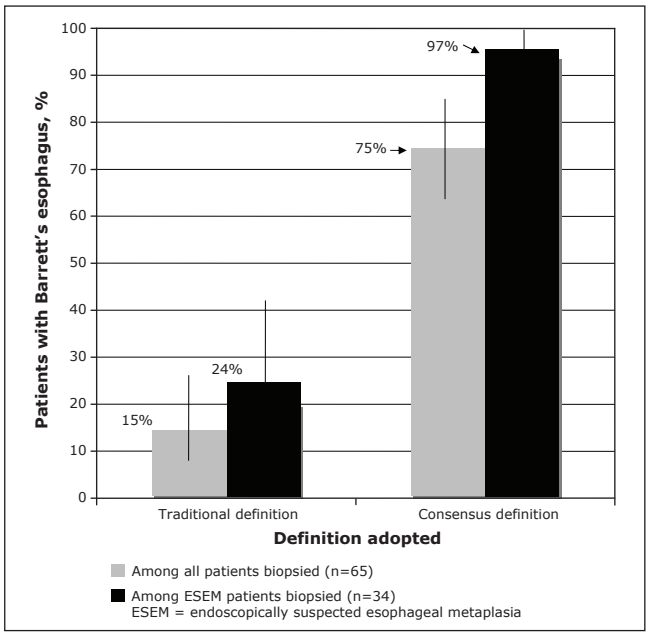

Figure 1) *Proportions of patients with Barrett's esophagus according to the traditional and proposed Montreal consensus definitions*

DISCUSSION

Of the 353 patients who presented for gastroscopy during the study period, the predominant symptoms, as expected, were heartburn and acid regurgitation, but patients also presented with nocturnal symptoms (11.3%), dysphagia (9.4%), hoarseness (5.5%) or atypical chest pain (4.2%). Endoscopically diagnosed esophagitis, identified in 26% of patients, may be under-represented considering 56% of patients were already taking a PPI at the time of endoscopy. ESEM was present in 12% of patients who underwent endoscopies. In addition, EE was suspected at endoscopy in three cases, but a biopsy was taken in only one of these patients. An independent, blinded histological review of all biopsy material in 65 patients yielded 10 cases of Barrett's esophagus, using a traditional definition. Adopting the Montreal definition of Barrett's esophagus proposed by Vakil et al (1), the number of Barrett's cases increased to 49. In addition, five cases of EE were diagnosed histologically.

The strengths of the present study include the broad generalizability of the study population referred for an initial gastroscopy for GERD-like symptoms to a general gastroenterology practice, and the independent reviews of endoscopic images and histology slides. While the present study is useful in answering the clinical aims we set out to address, there are important limitations. First, as a retrospective study, the clinical information for all of the categories studied was not readily available for every patient and depended on what was recorded as part of routine practice. This limitation is especially true for the presence of specific symptoms that may be influenced by detection or recall biases. Second, while the endoscopic images were prospectively reviewed, pictures were absent in a minority of cases. Finally, only 65 patients had esophageal biopsies.

Dysphagia emerged as a frequent presenting symptom of GERD in the present study. Of the 29 patients who complained of dysphagia, this symptom was explained by endoscopic findings in five cases, including four with Schatzki rings and one with a stricture. In addition, 11 of the 29 patients (37.9%) with dysphagia had reflux esophagitis, a figure comparable with previously reported data (11).

The new definition proposed by Vakil et al (1) is controversial, and clearly has the potential to dramatically affect the number of patients diagnosed with Barrett's esophagus. Whereas only 10 of 353 patients (2.8%) referred for evaluation met the classic diagnostic criteria for Barrett's esophagus, using the Montreal consensus definition would increase that number to 49 (14%), a fivefold increase. Among patients biopsied, 15% were diagnosed with Barrett's esophagus using traditional criteria, in contrast to 75% of patients if the new criteria were applied. We cannot be certain about the 'true' incidence because not all patients were biopsied; however, biopsies were collected in 34 of 41 patients exhibiting ESEM. In these patients, the proportion of Barrett's diagnoses would rise from 24% to 97% with adoption of the Montreal histological definition. Whether this represents a definition that has greater sensitivity for detecting patients at increased risk of esophageal adenocarcinoma is unclear. Previous research has indicated that esophageal columnar metaplasia with specialized IM is most strongly associated with adenocarcinoma (12). In contrast, the association between esophageal columnar metaplasia (cardiac or oxyntocardiac mucosa) without IM and adenocarcinoma has been more controversial (13,14). The inadequacy of biopsy protocols currently being practiced worldwide results in a poor sensitivity at detecting IM within an ESEM (1,12,15), which is one of the reasons for the proposed change in definition. Additionally, although the risk for adenocarcinoma is indeed highest with columnar metaplasia associated with IM, other forms of columnar metaplasia may also carry an associated risk (16). In fact, studies on patients with IM have shown that up to 35% of biopsies fail to demonstrate IM (12,17), and that at least eight biopsies may be needed for a reasonable diagnostic yield (12). The clinical impact of increased Barrett's diagnostic rates is significant because both long-term daily PPI therapy and inclusion in an endoscopic surveillance program are currently recommended for patients with a diagnosis of Barrett's esophagus (18-20).

EE was observed in five patients (1.4% of all patients). Among patients biopsied, 7.7% of patients met the criteria for EE. These figures may represent underestimates because this diagnosis was not suspected endoscopically in four of the five patients. In addition, only one of the five patients was diagnosed with EE on histology before our audit. Three of the five cases of EE were convincing, with eosinophil counts of greater than 100/hpf, while the remaining two had borderline eosinophil counts of 21/hpf and 26/hpf, respectively. The histological underdiagnosis may be partly explained by reports suggesting that variable numbers of eosinophils may also be noted in GERD (21). Currently, it is unclear whether the plethora of recent adult EE reports are related to an increase in diagnosis or an increase in the incidence of this condition (2,22). Presently, the most useful predictors appear to be clinical and not endoscopic, including male sex and a history of atopy (2). Despite the small sample size, our results show that instances of EE may have no distinguishing clinical or endoscopic features, suggesting that perhaps routine biopsies should be considered in all patients presenting with esophageal complaints (2). In addition, there appears to be a need for a heightened awareness of EE among clinicians, endoscopists and pathologists. A better correlation between the clinical and/or endoscopic suspicions and pathological findings through closer communication between clinicians and pathologists may help improve detection

rates. This is especially relevant because specifically targeted therapy for EE may be required for timely and complete symptom resolution.

With all of the above information, we attempted to quantify, in an exploratory fashion, the possible impact of these issues on clinical management, by extrapolating from the documented formal management recommendations recorded in the chart based on the initial consult and endoscopy report. Patients who had had a change in medication or its dose, those diagnosed with EE or those patients who were subsequently diagnosed with Barrett's esophagus, and thus needing subsequent surveillance (irrelevant of any change in medication that may have also occurred), were considered as having undergone a change in management compared with the pre-assessment status. This classification was independently reviewed by an experienced clinician with particular expertise in esophageal diseases (A Barkun). The clinical management of GERD patients was altered in 95 patients (27%; 95% CI 22% to 32%). Eighty-four of the 95 patients had a change of medications, including starting a PPI in 65 patients or increasing the PPI dose in 19 patients. Ten of the 95 patients were diagnosed with Barrett's esophagus and entered into an endoscopic surveillance program. One was diagnosed as having EE. Using the Montreal consensus definition of Barrett's esophagus, above and beyond these 95 patients, an additional 39 patients with columnar metaplasia but without IM would be considered for surveillance. Finally, an additional four patients were diagnosed with EE after the independent review was initiated as part of the present audit. The breakdown of patients is shown in Figure 2; up to 43 additional patients (12%; 95% CI 8.6% to 16%) would have undergone a change from current management.

The newly proposed Montreal consensus definition of Barrett's esophagus is controversial and, if implemented, would greatly increase the number of patients diagnosed with this condition. In addition, EE is a diagnosis that is probably much more prevalent than currently recognized, and may be missed in patients presenting with GERD-like symptoms. Both of these issues thus have the potential to significantly alter clinical practice. Prospective studies need to be undertaken to better define the implications of these findings.

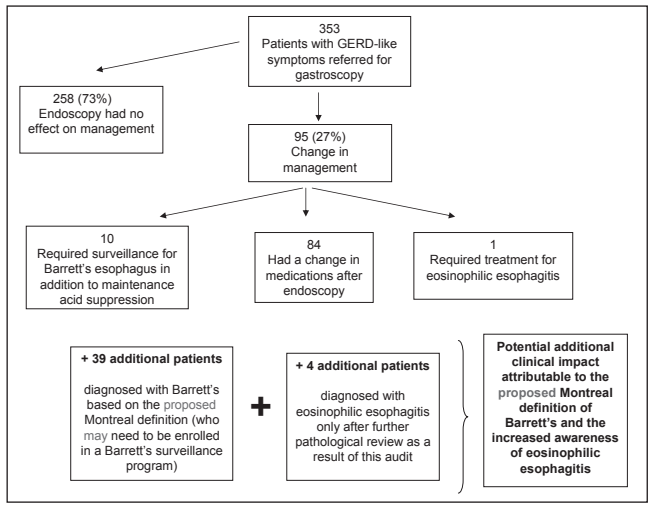

Figure 2) *Exploratory analysis of the potential impact on routine management of patients with gastroesophageal reflux disease (GERD)-like symptoms undergoing a gastroscopy*

DISCLOSURES: Dr Barkun is a research scholar funded by the *Fonds de la Recherche en Santé du Québec*. Dr AN Barkun is a consultant for AstraZeneca Inc. Dr Carlo Fallone is a consultant for or has received research support from AstraZeneca Canada Inc, Janssen-Ortho Canada, Nycomed Canada, Negma and Abbott Laboratories Canada Inc. Dr Serge Mayrand is a consultant for AstraZeneca Canada Inc, Janssen-Ortho Canada, Nycomed Canada and Axcan Pharma Inc. Dr Yael Kushner, Dr Victoria Marcus and Dr Suhail Salem have no conflict of interest disclosures or financial affiliations to declare. This study was undertaken with arm's-length support from Abbott Laboratories Canada Inc.

REFERENCES

1. Vakil N, van Zanten SV, Kahrilas P, et al. The Montreal definition and classification of gastroesophageal reflux disease: A global evidence-based consensus. Am J Gastroenterol 2006;101:1900-20.
2. Noel RJ, Tipnis NA. Eosinophilic esophagitis – a mimic of GERD. Int J Pediatr Otorhinolaryngol 2006;70:1147-53.
3. Moayyedi P, Talley NJ. Gastro-oesophageal reflux disease. Lancet 2006;367:2086-100.
4. Armstrong D, Bennett JR, Blum AL, et al. The endoscopic assessment of esophagitis: A progress report on observer agreement. Gastroenterology 1996;111:85-92.
5. Mueller J, Werner M, Stolte M. Barrett's esophagus: Histopathologic definitions and diagnostic criteria. World J Surg 2004;28:148-54.
6. Chandrasoma PT, Lokuhetty DM, Demeester TR, et al. Definition of histopathologic changes in gastroesophageal reflux disease. Am J Surg Pathol 2000;24:344-51.
7. Liacouras CA. Eosinophilic esophagitis in children and adults. J Pediatr Gastroenterol Nutr 2003;37(Suppl)1:S23-8.
8. Parfitt JR, Gregor JC, Suskin NG, et al. Eosinophilic esophagitis in adults: Distinguishing features from gastroesophageal reflux disease: A study of 41 patients. Mod Pathol 2006;19:90-6.
9. Gupta SK, Fitzgerald JF, Chong SK, et al. Vertical lines in distal esophageal mucosa (VLEM): A true endoscopic manifestation of esophagitis in children? Gastrointest Endosc 1997;45:485-9.
10. Remedios M, Campbell C, Jones DM, et al. Eosinophilic esophagitis in adults: Clinical, endoscopic, histologic findings, and response to treatment with fluticasone propionate. Gastrointest Endosc 2006;63:3-12.
11. Vakil NB, Traxler B, Levine D. Dysphagia in patients with erosive esophagitis: Prevalence, severity, and response to proton pump inhibitor treatment. Clin Gastroenterol Hepatol 2004;2:665-8.
12. Harrison R, Perry I, Haddadin W, et al. Detection of intestinal metaplasia in Barrett's esophagus: An observational comparator study suggests the need for a minimum of eight biopsies. Am J Gastroenterol 2007;102:1154-61.
13. Chandrasoma P, Wickramasinghe K, Ma Y, et al. Is intestinal metaplasia a necessary precursor lesion for adenocarcinomas of the distal esophagus, gastroesophageal junction and gastric cardia? Dis Esophagus 2007;20:36-41.
14. Spechler SJ, Goyal RK. The columnar-lined esophagus, intestinal metaplasia, and Norman Barrett. Gastroenterology 1996;110:614-21.
15. Meining A, Ott R, Becker I, et al. The Munich Barrett follow up study: Suspicion of Barrett's oesophagus based on either endoscopy or histology only – what is the clinical significance? Gut 2004;53:1402-7.
16. Santana J, Kahn M, Vakil N, et al. Systematic review of adenocarcinoma risk in Barrett's esophagus with particular reference to short segment Barrett's esophagus and intestinal metaplasia. Gastroenterology 2006;130:S1821:264. (Abst)
17. Chandrasoma PT, Der R, Dalton P, et al. Distribution and significance of epithelial types in columnar-lined esophagus. Am J Surg Pathol 2001;25:1188-93.

18. Horwhat JD, Baroni D, Maydonovitch C, et al. Normalization of intestinal metaplasia in the esophagus and esophagogastric junction: Incidence and clinical data. Am J Gastroenterol 2007;102:497-506.
19. Peters FT, Ganesh S, Kuipers EJ, et al. Endoscopic regression of Barrett's oesophagus during omeprazole treatment: A randomised double blind study. Gut 1999;45:489-94.
20. Sampliner RE. Updated guidelines for the diagnosis, surveillance, and therapy of Barrett's esophagus. Am J Gastroenterol 2002;97:1888-95.
21. Ngo P, Furuta GT, Antonioli DA, et al. Eosinophils in the esophagus – peptic or allergic eosinophilic esophagitis? Case series of three patients with esophageal eosinophilia. Am J Gastroenterol 2006;101:1666-70.
22. Vanderheyden AD, Petras RE, DeYoung BR, et al. Emerging eosinophilic (allergic) esophagitis: Increased incidence or increased recognition? Arch Pathol Lab Med 2007;131:777-9.