# Sacroiliitis and septicemia caused by *Campylobacter rectus* and *Actinomyces odontolyticus*

PIERRE HARVEY MD FRCPC, PAUL BAYARDELLE MD FRCPC, RAYMOND BÉLANGER MD FRCPC, LOUISE FORTIN MD FRCPC

**P HARVEY, P BAYARDELLE, R BÉLANGER, L FORTIN. Sacroiliitis and septicemia caused by *Campylobacter rectus* and *Actinomyces odontolyticus*. Can J Infect Dis 1994;5(3):133-136.** *Campylobacter rectus*, formerly known as *Wolinella recta*, is an anaerobic Gram-negative bacillus, generally recognized as an agent responsible for severe periodontitis; only two cases of extra-oral infections have been reported. The first case of septicemia with *C rectus* and *Actinomyces odontolyticus* is described in a 37-year-old farmer who suffered from severe sacroiliitis. Also presented are a review of *C rectus* in human pathology, and a brief review of pyogenic sacroiliitis, a rather rare disease.

**Key Words:** Actinomyces odontolyticus, Campylobacter rectus, *Pyogenic sacroiliitis*

## Sacro-iléite et septicémie causées par *Campylobacter rectus* et *Actinomyces odontolyticus*

**RÉSUMÉ :** *Campylobacter rectus*, que l'on appelait auparavant *Wolinella recta*, est un bacille gram négatif anaérobie qui est reconnu comme un agent étiologique de périodontite sévère; seulement deux cas d'infection originant hors de la cavité buccale ont été publiés. Nous rapportons le premier cas de septicémie à *C rectus* et *Actinomyces odontolyticus* chez un fermier de 37 ans qui a présenté une sacro-iléite sévère. Nous présentons également une revue de la pathogénicité humaine de *C rectus* et une brève revue de la sacro-iléite infectieuse, une maladie plutôt rare de nos jours.

*Departments of Microbiology and Infectious Diseases, Radiology, and Medicine, Division of Internal Medicine, Notre-Dame Hospital, Montreal, Quebec*
*Correspondence and reprints: Dr Pierre Harvey, Hôpital Nôtre-Dame, 1560 est rue Sherbrooke, Montréal, Québec H2L 4M1*
*Received for publication April 7, 1993. Accepted November 25, 1993*

CAMPYLOBACTER RECTUS, FORMERLY KNOWN AS *WOLINELLA recta* (1), is an anaerobic Gram-negative bacillus recognized as an agent responsible for severe periodontitis for more than a decade (2,3). Very few cases of extra-oral infections have been reported. The first case was that of an alcoholic man, who presented with a thoracic mass four months after pneumonia. The patient had severe periodontal disease. A culture of a biopsy of the mass revealed the presence of *C rectus* and *Actinomyces viscosus* (4). The only other extra-oral case of *C rectus* infection was a cerebral abscess in a 62-year-old women who was admitted to hospital with a history of headache, nausea and vomiting, chills and disorientation. There were no risk factors for cerebral abscess, nor periodontal disease. The cerebral biopsy yielded *C rectus* and *Streptococcus intermedius* (5). We report what, to our knowledge, is the first case of sacroiliitis and septicemia caused by *C rectus*.

## CASE REPORT

A 37-year-old farmer presented to the emergency room with severe low back pain of seven days' duration, progressively increasing in intensity, so he could no longer walk. There was no history of trauma. The patient had a remote past medical history of several dental abscesses and gum bleeding for several months. He also had a history of urethritis a few months before admission and admitted drinking unpasteurized cow's milk. In addition to severe low back pain, the patient reported chills and fever up to 40°C with pain in the left lower limb. Urological investigation was normal. The patient was referred to an orthopedic surgeon, but refused sacroiliac joint puncture and left hospital against medical advice. He was given cloxacillin 500 mg orally every 6 h.

The patient returned 48 h later with fever of 39.5°C. Physical examination revealed a toxic and dyspneic patient, severe periodontitis and exquisite pain on palpation of the left sacroiliac joint. Mobilization of the left lower limb was painless. Radiography of the sacroiliac joint and a technetium scan were normal. A puncture of the joint was traumatic and showed no organisms on Gram stain or culture. In the next few hours, the patient deteriorated with fever up to 40°C, septic shock and adult respiratory distress syndrome. White blood cell count was $16.2 \times 10^9$/L with a left shift, hemoglobin 98 g/L, platelets $83 \times 10^9$/L and erythrocyte sedimentation rate 58 mm/h. Hemodynamic and ventilatory support was provided. Antibiotic therapy was initiated with ampicillin, cloxacillin and gentamicin.

The patient was transferred 48 h later to our hospital with fever of 39°C and white blood cell count of $18.2 \times 10^9$/L. Computed tomography (CT) scan of the abdomen and pelvic cavity demonstrated asymmetry of the musculature anterior to the left sacroiliac joint with enlargement of iliacus, pyriformis and obturator internus muscles. There was a lumbarization of $S_1$ and sacrotransverse neoarticulation of $S_1$, the left transverse apophysis being wider than the right one. At the level of $L_3$-$L_4$ were a few left para-aortic lymph nodes. The next day, the antibiotics were replaced by imipenem for suspected intra-abdominal sepsis. A colonoscopy was normal. Stool cultures and peritoneal fluid were negative. Blood cultures drawn on the first visit at the first hospital when the patient was not receiving any antibiotic and three days before the sacroiliac puncture, yielded *C rectus* in both BACTEC NR7A (Becton-Dickinson, Maryland) anaerobic bottles, and *Actinomyces odontolyticus* in one BACTEC NR7A bottle after five days of incubation.

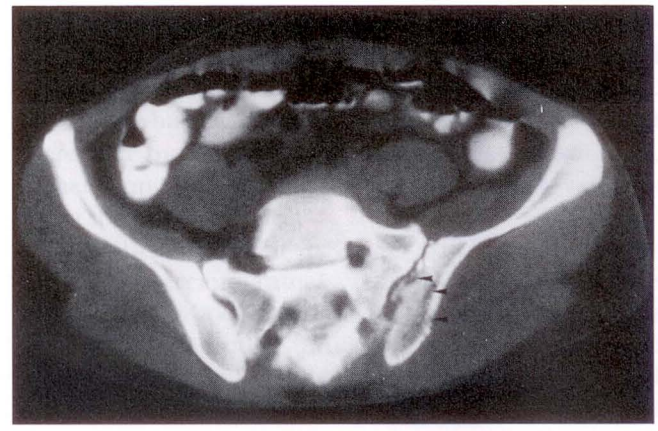

**Figure 1)** *Computed tomography scan17 days after admission, revealing osteomyelitis of the iliac side of the left sacroiliac joint with persistance of musculature enlargement*

An exploratory laparotomy performed after stabilization of the patient was negative. The patient improved significantly over the next 48 h. The gallium and technetium scans done one week after admission showed an increased activity in the left sacroiliac area. A surgical exploration of this area at the same time revealed no significant abnormality. Chest roentgenogram, upper gastrointestinal tract and barium enema were normal. A panoramic study of the teeth demonstrated severe periodontal disease; the patient subsequently had two molar extractions for dental abscesses and dental scaling. The final diagnosis was acute septic arthritis of the left sacroiliac joint following seeding from an oral source, considering the history of gum bleeding. The septic shock was presumably secondary to the attempted needle aspiration in an infected area.

Seventeen days after admission, CT scan was repeated and revealed the presence of osteomyelitis of the iliac side of the left sacroiliac joint with persistence of musculature enlargement (Figure 1). The isolate of *C rectus* was sensitive to penicillin, clindamycin, metronidazole, chloramphenicol and imipenem. The patient left the hospital after completion of five weeks of imipenem therapy, with oral penicillin and clindamycin for another three months. At the end of this treatment, the patient had returned to normal activities. CT scan

and scintigraphic examinations showed signs consistent with bone remodelling and decrease in size of the left iliacus and pyriformis muscles, which became nearly symmetric with the right-side muscles.

## MICROBIOLOGY

Both organisms were confirmed by the Canadian Laboratory Centre for Disease Control. *C rectus* was identified on the basis of the following characteristics: anaerobic, motile, Gram-negative straight bacillus, oxidase-positive, reduced nitrate to nitrite; catalase, indol, gelatin, esculin and urea were negative. Carbohydrates were not fermented; the main end-products of gas chromatography were succinate, acetate, fumarate and lactate. The isolate was sensitive to kanamycin, stimulated by formate-fumarate and showed pitting of the agar. The characteristics of this isolate were consistent with those of *C rectus* (6).

*A odontolyticus* was identified on the basis of the following reactions: a diphtheroidal Gram-positive rod, nonspore-forming, that grew in anaerobic atmosphere only, was catalase-negative, reduced nitrate, produced acid from sucrose, glucose and fructose; it did not produce acid from raffinose, lactose, maltose, mannitol or xylose, nor did it hydrolyze esculin, urea or starch or produce indol. Acetate, fumarate, lactate and succinate were produced in glucose-containing medium.

Antimicrobial susceptibility testing was done with the agar dilution method. *C rectus* isolate was susceptible to all antibiotics tested (penicillin 0.06 μg/mL; piperacillin 2.0 μg/mL or less; cefoxitin O.5 μg/mL or less; imipenem 0.125 μg/mL; clindamycin 0.5 μg/mL or less; and metronidazole 0.5 μg/mL or less).

## DISCUSSION

Bacterial sacroiliitis occurs infrequently. In their review of the English literature, Vyskocil et al (7) identified 163 cases of bacterial pyogenic sacroiliitis from 1878 to 1990, to which they added three cases of their own. They excluded cases of *Mycobacterium tuberculosis* and *Brucella* species, which occurred frequently in the preantibiotic era.

Pyogenic sacroiliitis accounts for 1.5% of all suppurative arthritis in children. The principal risk factors are cutaneous infections, trauma, intravenous drug abuse and respiratory tract infections. In 41% of patients, a primary site of infection could not be identified; an association with the presence of human leukocyte antigen B27 could not be demonstrated. The average age of patients was 22 years (range one to 71 years) (7).

Patients with pyogenic sacroiliitis usually report pain in the buttocks or in a limb; pain in the sacroiliac joint region is almost always described with associated tenderness on palpation. Because the anterior sacroiliac ligament is thin and easily ruptured, pus from the sacroiliac joint sometimes invades the anterior iliac fossa, generating a mass occasionally palpable on rectal examination. The posterior approach used by the surgeon could explain why our patient's sacroiliac joint had a normal appearance at surgery. The majority of cases have an acute presentation. The Gaenslen and FABERE manoeuvres can be used to stress the sacroiliac joint and elicit pain (7). There is no specific blood test, but erythrocyte sedimentation rate may be greater than 100 mm/h. As in other bone infections, roentgenograms are usually normal early in the course of the disease. The diagnosis may be made with bone scan as early as 48 h after onset of symptoms, but a negative bone scan after four days of symptoms was reported by Gordon and Kabins (8). The most common organism isolated is *Staphylococcus aureus* (46% of positive cultures); other organisms include *Pseudomonas aeruginosa*, *Staphylococcus epidermidis*, group A streptococci and enterobacteriaceae (7). Blood cultures provide a presumptive etiology in 23% of cases; when blood cultures cannot identify the responsible agent, fluoroscopic guided fine needle aspiration, as described by Miskew et al (9), is positive in 82% of cases. When these two procedures are not diagnostic, an open biopsy should be performed. Empirical antibiotic therapy should be directed against staphylococcal infection until a specific pathogen and its sensitivities are known. If the patient is an intravenous drug user, *P aeruginosa* should be covered with empirical therapy. Treatment should ideally be continued for six weeks with high dose intravenous antibiotics.

This article reports the first case of severe infection of the sacroiliac joint caused by *C rectus* probably originating from severe, neglected periodontitis with secondary bacteremia that lead to sacroiliac joint infection. Even though joint or bone cultures were not positive, the temporal relationship between the clinicoradiological picture and the blood cultures is supportive. In their review, Vyskocil et al (7) reported 39 positive blood cultures in 138 cases of bacterial pyogenic sacroiliitis. The usual organisms found, *S aureus* and *P aeruginosa*, would have been easily isolated if implicated in this patient's condition. The negative puncture, as well as the negative findings at surgery, could be related to the anterior location of the infection in the left sacroiliac joint. This procedure is often difficult and, as in our case, may be traumatic.

The treatment of this syndrome is primarily high dose antimicrobial therapy for at least six weeks. We chose to continue imipenem therapy because of the good clinical response and because susceptibility data were received after five weeks of treatment. In addition, the patient developed septic shock while receiving ampicillin, so penicillins were not considered further for therapy of the acute phase of the illness. There are no data concerning the comparative efficacy of penicillin versus imipenem.

The other isolate, *A odontolyticus*, is also highly sensitive to all beta-lactams; its presence is a strong

argument in favour of the oral source for these organisms. *A odontolyticus* appears to be rarely involved in the etiology of invasive infections, although it has been isolated from a few cases of cervicofacial lesions, pleural fluid and lung abscess, as well as from eye infections. *A odontolyticus* plays a role with other members of the genus in periodontal disease. All species of *Actinomyces* are normal inhabitants of the oral cavity of human animals. Disease results when these indigenous bacteria are introduced into the tissues, then considered to be an opportunistic infection. Actinomycotic infections are usually mixed infections, mostly with oral bacteria. Although they can be isolated in intra-abdominal infections, none of the *Actinomyces* species have been documented to be normal inhabitants of the intestinal tract (10). One other case of mixed extra-oral infection by *C rectus* and *A viscosus* was described by Spiegel and Telford (4), who isolated these organisms in an actinomycotic chest wall mass. Infections with *C rectus* are always mixed infections, as in this case with A *odontolyticus*.

*C rectus* is an anaerobic Gram-negative bacillus, found occasionally in the normal oral flora of humans, especially at the gingival sulcus (5,11,12); it is associated with severe periodontal disease (11,12). During a period of 12.5 years at Veterans Administration Wadsworth Medical Center, Johnson and Finegold (13) isolated 13 (0.9%) motile, anaerobic Gram-negative bacilli in 1523 clinical specimens that contained anaerobes. They described two cases of empyema and three cases of wound infection caused by *Campylobacter* species. Isolation of *Campylobacter* species from decubitus ulcers and lower extremity soft tissue ulcers led these authors to suggest that *C rectus* could be part of normal enteric flora; another explanation could be that patients with severe periodontitis swallow *C rectus* and the organism is transiently part of the enteric flora. The gastrointestinal investigations in our patient did not reveal any disease to explain the origin of either organism. The anaerobic nature of *C rectus* has recently been challenged (14). The pathogenicity of this organism may be explained by its lipopolysaccharide, which could have contributed to the clinical picture of septic shock in our patient (15). Metronidazole or clindamycin show more consistent activity towards this organism than penicillin (6,14); imipenem is also an alternative.

## CONCLUSION

This is the first description of a case of sacroiliitis with septicemia caused by *C rectus;* this case adds to others previously reported to confirm the pathogenic role of *C rectus* in human disease.

**ACKNOWLEDGEMENTS:** We thank Dr François Coutlée for his revision of the manuscript.

### REFERENCES

1. Summanen P. Recent taxonomic changes for anaerobic Gram-positive and selected Gram-negative organisms. Rev Infect Dis 1993;16(Suppl 4):Sl68-74.
2. Tanner ACR, Badger S, Lai C-H, Listgarten MA, Visconti RA, Socransky SS. *Wolinella* gen. nov., *Wolinella succinogenes (Vibrio succinogenes* Wolin et al) comb. nov., and description of *Bacteroides gracilis* sp. nov., *Wolinella recta* sp. nov., *Campylobacter consisus* sp. nov., and *Eikenella corrodens* from humans with periodontal disease. Int J Syst Bacteriol 1981;31;432-45.
3. Tanner A, Stillman N. Oral and dental infections with anaerobic bacteria: clinical features, predominant pathogens and treatment. Clin Infect Dis 1993;16 (Suppl 4):S304-9.
4. Spiegel CA, Telford G. Isolation of *Wolinella recta* and *Actinomyces viscosus* from an actinomycotic chest wall mass. J Clin Microbiol 1984;20:1187-9.
5. Marrie TJ, Kerr E. Brain abscess due to *Wolinella recta* and *Streptococcus intermedius*. Can J Infect Dis 1990;1:31-4.
6. Tanner ACR, Socransky SS. *Wolinella*. In: Krieg NR, Holt JG, eds. Bergey's Manual of Systematic Bacteriology. Baltimore: Williams and Wilkins, 1984:646-50.
7. Vyskocil JJ, McIlroy MA, Brennan TA, Wilson FM. Pyogenic infection of the sacroiliac joint: case report and review of the literature. Medicine 1991;70:188-97.
8. Gordon G, Kabins SA. Pyogenic sacroiliitis. Am J Med 1980;69:50-5.
9. Miskew DB, Block RR, Witt PF. Aspiration of infected sacroiliac joints. J Bone Joint Surg 1979;61A:1071-2.
10. Schaal KP. Genus *Actinomyces*. In: Krieg NR, Holt JG eds. Bergey's Manual of Systematic Bacteriology. Baltimore: Williams and Wilkins, 1984:1405.
11. Tanner ACR, Haffer C, Bratthall GT, Visconti RA, Socransky SS. A study of the bacteria associated with advancing periodontitis in man. J Clin Periodontol 1979;6:278-307.
12. Tanner ACR, Dzink JL, Ebersole JL, Socransky SS. *Wolinella recta, Campylobacter consisus, Bacteroides gracilis*, and *Eikenella corrodens* from periodontal lesions. J Periodontal Res 1987;22:327-30.
13. Johnson CC, Finegold SM. Uncommonly encountered, motile, anerobic Gram-negative bacilli associated with infection. Rev Infect Dis 1987;9:1150-62.
14. Han YH, Smibert RM, Krieg NR. *Wolinella recta, Wolinella curva, Bacteroides ureolyticus* and *Bacteroides gracilis* are microaerophiles, not anaerobes. Int J Syst Bacteriol 1991;41:218-22.
15. Kumada H, Watanabe K, Umemoto T, Kato K, Kondo S, Hisatsune K. Chemical and biological properties of lipopolysaccharide, lipid A and degrades polysaccharide from *Wolinella recta* ATCC 33238. J Gen Microbiol 1989;135:1017-25.



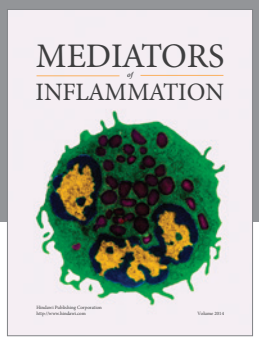

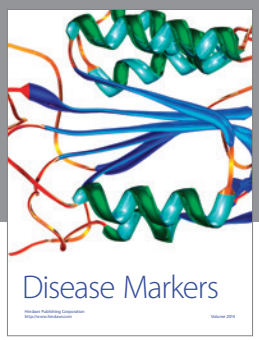



Hindawi

Submit your manuscripts at
http://www.hindawi.com