

Community-acquired *Serratia marcescens* spinal epidural abscess in a patient without risk factors: Case report and review

Michael D Parkins MD FRCPC¹, Daniel B Gregson MD FRCPC^{1,2,3}

MD Parkins, DB Gregson. Community-acquired *Serratia marcescens* spinal epidural abscess in a patient without risk factors: Case report and review. *Can J Infect Dis Med Microbiol* 2008;19(3):250-252.

Serratia marcescens has rarely been reported as an agent of invasive disease in patients presenting from the community. Furthermore, *S marcescens* is frequently opportunistic, affecting individuals with serious medical comorbidities including immune suppression and diabetes. A case of a community-acquired *S marcescens* spontaneous lumbar epidural abscess presenting as cauda equina syndrome is reported in a previously well 36-year-old man with no identifiable risk factors. To the authors' knowledge, this is the first report of invasive *S marcescens* causing disease in a patient with no medical comorbidities.

Key Words: *Community-acquired; Immunocompetent; Invasive; Serratia marcescens; Spinal epidural abscess*

Serratia marcescens is an aerobic, motile, Gram-negative bacillus that is well-recognized as a pathogen in nosocomial settings. One area in which there appears to be a predilection for infection is in postoperative central nervous system (CNS) infections (1). Although rare, *S marcescens* can cause disease in the community, primarily in immunocompromised hosts and illicit drug users (2). A case of a spontaneous community-acquired spinal epidural abscess (SEA) is reported in a previously well 36-year-old man presenting with cauda equina syndrome.

CASE PRESENTATION

A 36-year-old man was admitted to hospital because of fever, back and leg pain, and urinary retention. He had been unwell for seven days before admission, but he could not associate symptom onset with any inciting event. The patient worked as a computer programmer and was previously well, with the exception of chronic back pain, which was attributed to sports injuries, a remote laparoscopic cholecystectomy and remote bilateral meniscal repairs. The patient denied illicit drug use or risk factors for HIV. On admission, his temperature was 38.7°C, pulse rate 87 beats/min and blood pressure 129/81 mmHg. His neurological examination was remarkable only for diminished ankle reflexes with normal plantar responses, saddle anesthesia, reduced rectal tone and a distended bladder. The patient's cardiopulmonary and abdominal examinations were otherwise unremarkable. There was a

Un abcès spinal épidural à *Serratia marcescens* non nosocomial chez un patient sans facteur de risque : Rapport de cas et analyse

On a rarement déclaré des cas de *Serratia marcescens* comme agent de maladie envahissante chez des patients provenant de la collectivité. De plus, le *S marcescens* est souvent opportuniste, touchant des personnes atteintes de graves comorbidités médicales, y compris l'immunosuppression et le diabète. Un cas d'abcès lombaire épidural spontané à *S marcescens* non nosocomial se manifestant sous forme de syndrome de la queue de cheval est déclaré chez un homme de 36 ans auparavant en santé, sans facteur de risque dépitable. Pour autant que le sache l'auteur, c'est le premier rapport de maladie provoquant un *S marcescens* envahissant chez un patient n'ayant pas de comorbidités médicales.

notable absence of evidence of soft tissue infection, stigmata of infectious endocarditis or track marks.

Routine laboratory tests were normal, with the exception of neutrophilia ($13.2 \times 10^9/L$) and an elevated erythrocyte sedimentation rate (35 mm/h). His blood chemistry, liver function tests and urinalysis were normal. A magnetic resonance imaging (MRI) scan showed impingement of the nerve roots at L4-L5 and L5-S1, but there was no clear collection suggestive of epidural abscess or discitis. The patient was given a single dose of trimethoprim/sulfamethoxazole for a presumed urinary tract infection as cause of fever, despite a normal urinalysis, and was immediately taken to the operating room for a presumed disc herniation. At procedure, frank pus and granulation tissue were evident at L4-S1. An L5-S1 laminectomy was performed after irrigation and debridement. There was no intraoperative evidence of osteomyelitis. Intraoperative cultures and blood cultures were positive at 24 h for nonpigmented *S marcescens*. The patient did not receive empirical antibiotic therapy for a SEA until the surgical diagnosis was made 18 h after presentation; he was then started on 2 g ceftriaxone given intravenously every 12 h and 1 g vancomycin given intravenously every 12 h. Once the species was identified, antibiotics were corrected to 2 g meropenem given intravenously every 8 h. The patient was discharged after seven days on 1 g ertapenem taken intravenously every 24 h and 500 mg ciprofloxacin taken orally twice per day for six weeks. Dual-agent therapy was prolonged a further

¹Departments of Medicine; ²Pathology and Laboratory Medicine, University of Calgary, ³Calgary Laboratory Services, Calgary, Alberta
Correspondence: Dr Daniel B Gregson, Division of Microbiology, Calgary Laboratory Services, 9-3535 Research Road Northwest, Calgary, Alberta T2L 2K8. Telephone 403-770-3309, fax 403-770-3347, e-mail Dan.Gregson@CLS.ab.ca

Received for publication August 15, 2007. Accepted January 5, 2008

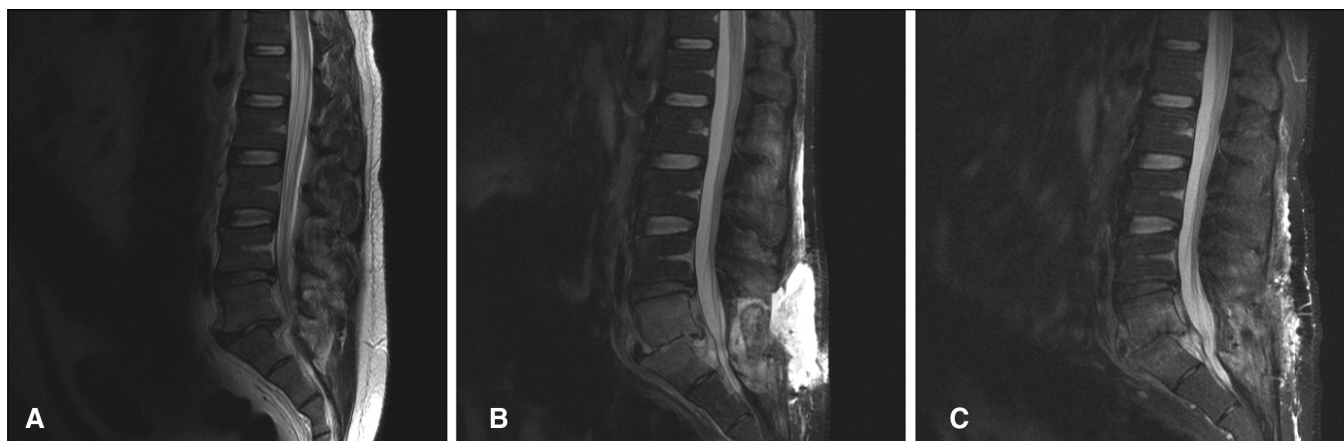


Figure 1) Serial T2-weighted magnetic resonance imaging scans of the lumbar spine before and during treatment showing progression and resolution of fluid collection (A – day 0, preoperative; B – day 35; C – day 78)

six weeks because of persistent fluid collection and progression of disease on reimaging (Figure 1). The patient regained full neurological function and was back to baseline clinical status within two weeks following postdischarge.

DISCUSSION

SEA is a rare event, comprising 0.2 to two cases per 10,000 hospital admission (3). SEA is associated with a mortality of 15%. Risk factors identified include surgical manipulation, distal site of infection, trauma, immune suppression, diabetes, renal failure and illicit parenteral drug abuse (3). Gram-negative bacteria are identified as causative organisms in fewer than 5% of cases. Spontaneous SEA in the absence of these risk factors represents fewer than 5% to 20% of occurrences (3,4). While neuroimaging may be an important tool in identifying and managing cases, its sensitivity is only 90% overall; acute cases are more likely to be unrecognized, as illustrated by the present case (3).

Using MEDLINE, we searched the English literature from 1966 to June 2007 for similar presentations. The terms searched included ‘*Serratia*’ combined with ‘invasive’, ‘abscess’, ‘epidural’, ‘spontaneous’, ‘community’ and ‘immunocompetent’. All articles had their references reviewed for inclusion. While *S marcescens* has not previously been reported to cause isolated SEA, it has been associated with CNS disease in various postsurgical forms, including osteomyelitis, spondylodiscitis, meningitis, brain and epidural abscesses (1,5), and secondary spread from other areas of infection (6). *S marcescens* spinal infection is associated with a mortality of greater than 50%, despite adequate recognition and treatment (1).

Risk factors for the acquisition of *S marcescens* infection include immune suppression, diabetes, renal failure, steroid use and malignancy (7). Community occurrences have commonly been associated with contaminated depot, parenteral solutions (8) and illicit drug use (9). Invasive *S marcescens* infection from the community has been reported in several circumstances, including late-onset post-traumatic meningitis (10), fistulizing Crohn’s disease (6), septic abortion and chorioamnionitis (11). In each instance of community-acquired invasive disease identified in the literature, an inciting event or risk factor could be identified. The present case is unique, given the notable absence of risk factors and the relatively rare clinical presentation.

The advent of MRI has greatly aided in the diagnosis and management of spinal cord impingement syndromes. However, over-reliance on MRI modalities can result in an inappropriate false-negative diagnosis in 10% of cases (3). Although uncommon as a cause of cauda equina syndrome in previously well individuals, bacterial SEA is an important component of the differential of this presentation owing to its high morbidity and mortality. In patients presenting with cauda equina syndrome with fever, leukocytosis and elevated inflammatory markers, SEA should remain a diagnosis of exclusion to be determined postoperatively. Aggressive treatment with early surgical decompression and targeted empirical antimicrobials with adequate CNS penetration are vital to minimizing neurological sequelae. Due to the increasing prevalence of AmpC- (12) and extended-spectrum beta-lactamase- (13,14) producing coliforms in the community, we suggest using a fluoroquinolone or carbapenem in conjunction with antistaphylococcal therapy pending the identification of the causal agent in this condition.

REFERENCES

- Huang CR, Lu CH, Chien CC, Chang WN. Protean infectious types and frequent association with neurosurgical procedures in adult *Serratia marcescens* CNS infections: Report of two cases and review of the literature. *Clin Neurol Neurosurg* 2001;103:171-4.
- Yu VL. *Serratia marcescens*: Historical perspective and clinical review. *N Engl J Med* 1979;300:887-93.
- Reihsaus E, Waldbaur H, Seeling W. Spinal epidural abscess: A meta-analysis of 915 patients. *Neurosurg Rev* 2000;23:175-204; discussion 205.
- Darouiche RO, Hamill RJ, Greenberg SB, Weathers SW, Musher DM. Bacterial spinal epidural abscess. Review of 43 cases and literature survey. *Medicine (Baltimore)* 1992;71:369-85.
- Hadjipavlou AG, Gaitanis IN, Papadopoulos CA, Katonis PG, Kontakis GM. *Serratia* spondylodiscitis after elective lumbar spine surgery: A report of two cases. *Spine* 2002;27:E507-12.
- Heidemann J, Spinelli KS, Otterson MF, Binion DG. Case report: Magnetic resonance imaging in the diagnosis of epidural abscess

- complicating perirectal fistulizing Crohn's disease. *Inflamm Bowel Dis* 2003;9:122-4.
7. Bouza E, García de la Torre M, Erice A, Cercenado E, Loza E, Rodríguez-Crèixems M. *Serratia* bacteremia. *Diagn Microbiol Infect Dis* 1987;7:237-47.
 8. Civen R, Vugia DJ, Alexander R, et al. Outbreak of *Serratia marcescens* infections following injection of betamethasone compounded at a community pharmacy. *Clin Infect Dis* 2006;43:831-7.
 9. Mintz L, Mollett GH. Letter: *Serratia* vertebral osteomyelitis in narcotic addicts. *Ann Intern Med* 1975;83:668-9.
 10. Peeters A, Vandercam B, Sindic CJ, Hantson P, Mahieu P. Community-acquired *Serratia marcescens* meningitis. *J Infect* 1997;35:303-4.
 11. Prosser BJ, Horton J. A rare case of *serratia* sepsis and spontaneous abortion. *N Engl J Med* 2003;348:668-9.
 12. Pitout JD, Gregson DB, Church DL, Laupland KB. Population-based laboratory surveillance for AmpC beta-lactamase-producing *Escherichia coli*, Calgary. *Emerg Infect Dis* 2007;13:443-8.
 13. Pitout JD, Hanson ND, Church DL, Laupland KB. Population-based laboratory surveillance for *Escherichia coli*-producing extended-spectrum beta-lactamases: Importance of community isolates with blaCTX-M genes. *Clin Infect Dis* 2004;38:1736-41.
 14. Pitout JD, Nordmann P, Laupland KB, Poirel L. Emergence of Enterobacteriaceae producing extended-spectrum beta-lactamases (ESBLs) in the community. *J Antimicrob Chemother* 2005;56:52-9.
-



Hindawi
Submit your manuscripts at
<http://www.hindawi.com>

