

Case report and review of the literature: *Toxoplasma gondii* encephalitis in a 40-year-old woman with common variable immunodeficiency and a new diagnosis of large granular lymphocytic leukemia

Adam Hofmann MD CM¹, Gerasimos Zaharatos MD CM FRCPC², Mark Miller MD CM²

A Hofmann, G Zaharatos, M Miller. Case report and review of the literature: *Toxoplasma gondii* encephalitis in a 40-year-old woman with common variable immunodeficiency and a new diagnosis of large granular lymphocytic leukemia. Can J Infect Dis Med Microbiol 2008;19(4):309-310.

Toxoplasma gondii has been well-documented to cause central nervous system infections in immunodeficient patients. The present study describes a case of central nervous system toxoplasmosis in a patient with common variable immunodeficiency and newly diagnosed large granular lymphocytic leukemia, with a review of the literature for this association.

Key Words: Cerebral toxoplasmosis; Common variable immunodeficiency; Large granular lymphocytic leukemia; *Toxoplasma gondii*

Central nervous system (CNS) toxoplasmosis is the most common CNS infection in patients with advanced acquired immunodeficiency syndrome (1). *Toxoplasma* encephalitis has been documented once before in a patient with common variable immunodeficiency (CVID) and corticosteroid therapy (2), as well as in several patients with CVID and *Toxoplasma* infection in organ systems other than the CNS (3,4).

CASE PRESENTATION

A 40-year-old woman who was born in Lebanon and has been living in Canada for the past 21 years presented to SMBD-Jewish General Hospital (Montreal, Quebec), two weeks after being discharged with a presumptive diagnosis of acute thrombotic cerebrovascular accident affecting the motor function of her right upper limb. She returned with worsening motor deficits of her right upper and lower limbs, gait instability, loss of the right nasolabial fold and expressive dysphasia. Her medical history was notable for a diagnosis of CVID at 19 years of age on migration to Canada, and she was treated at the hospital with monthly infusions of intravenous immunoglobulin. She also had multiple drug allergies, antiglobet cell antibody autoimmune disease resulting in acute necrosis of the stomach and subsequent short bowel syndrome requiring prolonged admission to the intensive care unit and home total parenteral nutrition, and a recent diagnosis of large granular lymphocytic (LGL) leukemia

Rapport de cas et revue de la littérature : Encéphalite à *Toxoplasma gondii* chez une femme de 40 ans souffrant d'immunodéficience commune variable et porteuse d'un diagnostic récent de leucémie à grands lymphocytes granuleux

Le rôle causal de *Toxoplasma gondii* dans les infections du système nerveux central chez les patients immunodéficients est bien documenté. La présente étude décrit un cas de toxoplasmose du système nerveux central chez une patiente souffrant d'immunodéficience commune variable et porteuse d'un diagnostic récent de leucémie à grands lymphocytes granuleux; la présentation de cas s'accompagne d'une revue de la littérature sur le lien entre ces affections.

(natural killer [NK] subtype, CD56+) made two weeks prior, during her first admission to the hospital, in the context of a new lymphopenia. Given the indolent nature of LGL leukemia, her treating hematologist decided to forgo treatment until her neutropenia became severe. From the day she was diagnosed with necrotizing enteritis, 11 years before admission, she was on a continuous dose of prednisone 20 mg per day for suppression of her antiglobet cell antibody-related disease. She has had a cat at home for at least five years before her admission. Her physical examination was remarkable for expressive dysphasia; right hemiparesis with progressive involvement of distal-to-proximal right upper, and later right lower extremity; right-sided facial droop and right inferior quadrantanopsia.

Three weeks after admission, a repeat magnetic resonance imaging (MRI) scan was taken of her CNS, with gadolinium infusion, which demonstrated a hyperintense lesion in the basal ganglia on T2 and fluid-attenuated inversion-recovery imaging extending from the corona radiata, through the lentiform nucleus and posterior limb of the internal capsule, and down to the left cerebral peduncle (Figure 1A). Lumbar puncture demonstrated normal glucose and protein levels, 20 red blood cells/ μ L and two white blood cells/ μ L. The patient's cerebrospinal fluid was negative for routine bacterial culture, India ink microscopy, cryptococcal antigen assay and fungal cultures, viral culture and enterovirus nucleic acid detection by polymerase chain reaction. Infectious diseases

¹Department of Internal Medicine, McGill University; ²Division of Infectious Diseases, Department of Medicine, SMBD-Jewish General Hospital, Montreal, Quebec

Correspondence: Dr Adam Hofmann, Department of Internal Medicine, SMBD-Jewish General Hospital, Suite G-050, 3755 Cote Ste Catherine Road, Montreal, Quebec H3T 1E2. Telephone 514-340-8222, fax 514-340-8222 ext 4974, e-mail Adam.hofmann@mail.mcgill.ca

Received for publication September 25, 2007. Accepted April 10, 2008

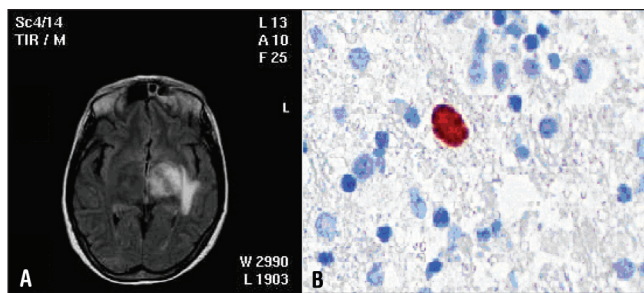


Figure 1 A T1-weighted magnetic resonance imaging with gadolinium infusion demonstrating a left-sided basal ganglia lesion of central nervous system toxoplasmosis in a 40-year-old woman with common variable immunodeficiency. B High-power view of a tachyzoite on the patient's brain biopsy, stained with antitoxoplasma antibody (original magnification 40×)

service was consulted two days after the repeat MRI scan. Because this presentation was consistent with either CNS lymphoma or opportunistic infection, the patient was initially treated presumptively with a regimen of high-dose dexamethasone and multiple antibiotics, initially including 3.1 g of intravenous ticarcillin-clavulanate given every 6 h, 1 g of valacyclovir given twice daily for chronic herpes keratitis, 250 mg of oral vancomycin given four times daily for presumed *Clostridium difficile* infection, 50 mg of pyrimethamine given once daily, 1.5 g of sulfadiazine given three times daily and 5 mg of folinic acid given daily.

Repeat imaging of the CNS one week later demonstrated no notable change in the size of the lesion, and dexamethasone was discontinued in favour of the patient's usual dose of prednisone; ticarcillin-clavulanate was also discontinued. Over the course of the admission, the patient had progressive dysphasia and developed a dense right hemiplegia. A second repeat MRI scan showed progression of the left hemispheric lesion. Given the uncertain nature of her illness, a stereotactically guided brain biopsy was performed at Montreal Neurological Institute and Hospital (Montreal, Quebec) on the sixth week of admission to the hospital, approximately three weeks after the commencement of antitoxoplasma therapy.

The pathology of the brain biopsy demonstrated several organisms consistent with *Toxoplasma gondii* (Figure 1B). The patient's hospital course was then complicated by a rise in her liver transaminase levels, which did not respond to changing her treatment regimen from sulfa-based antimicrobials to 750 mg of atovaquone given four times daily and 50 mg of pyrimethamine given once daily. Her liver biopsy revealed infiltration of her liver sinusoids with LGL leukemia cells. She was discharged three months after admission to Jewish Rehabilitation Hospital (Laval, Quebec) on her original doses of prednisone, pyrimethamine, sulfadiazine and folinic acid. Given her permanent and worsening immunocompromised state, a decision was made to treat her toxoplasma indefinitely. At nine months of follow-up, she had regained the ability to walk and minimal use of her right hand; there was significant improvement in her dysphasia.

DISCUSSION

CVID is a collection of heterogeneous and undifferentiated primary immunodeficiencies, which often become clinically apparent by the third or fourth decades of life. CVID is marked

by significantly depressed levels of immunoglobulin G and immunoglobulin A, and the lack of other primary or secondary causes of immunodeficiency (5).

Cerebral toxoplasmosis is caused by the ubiquitous parasite, *Toxoplasma gondii*. Typically, CNS toxoplasmosis is primarily seen in patients with a deficit in cell-mediated immunity. According to a recent review (6), deficits in CD8+ and CD4+ T cell-specific responses, in the production of interferon-gamma, in the function of NK cells and in dendritic cell function predispose to increased susceptibility to toxoplasma encephalitis.

Diagnosis of CNS toxoplasma in this patient was especially difficult given her specific humoral immunodeficiency and repeated therapy with intravenous immunoglobulin over many years, rendering serological diagnosis impossible. The occurrence of CNS toxoplasmosis in CVID has been described once before in the literature (2), but the patient did not have the concurrence of a major acquired deficit in cell-mediated immunity. Prior reports (2,7) hypothesize that a humoral deficiency alone could account for an increased susceptibility to toxoplasma infection. Our case features a woman with cerebral toxoplasmosis in the context of CVID, chronic corticosteroid use and a very recent diagnosis of NK-LGL leukemia. It was hypothesized that the development of toxoplasma encephalitis immediately following the diagnosis of LGL leukemia in our patient would seem to imply that her condition could be temporally ascribed to a newly-acquired deficit in cell-mediated immunity. This lends credence to prior animal models of the disease, which implicated NK-cell deficiency and cell-mediated immunity as the strongest risk factors (6,8). The nature of CVID renders it particularly challenging to diagnose diseases normally characterized by the humoral response. Toxoplasma and many other infectious agents fall into this category. In the present case, the diagnosis could only have been established by histological examination of the diseased tissue. It is also of interest to note that the patient initially presented in a fashion that closely resembled an acute thrombotic or embolic cerebrovascular accident. This implies that patients with inherited or acquired immunodeficiencies should be investigated for infectious etiologies when they present with a new neurological disease of any kind.

REFERENCES

- Porter SB, Sande MA. Toxoplasmosis of the central nervous system in the acquired immunodeficiency syndrome. *N Engl J Med* 1992;327:1643-8.
- Holtkamp M, Okuducu AF, Klingebiel R, Ploner CJ. Cerebral toxoplasmosis in a patient with common variable immunodeficiency. *Neurology* 2004;63:2192-3.
- Mrusek S, Marx A, Kummerle-Deschner J, et al. Development of granulomatous common variable immunodeficiency subsequent to infection with *Toxoplasma gondii*. *Clin Exp Immunol* 2004;137:578-83.
- Shachor J, Shneyour A, Radnay J, Steiner ZP, Bruderman I. Toxoplasmosis in a patient with common variable immunodeficiency. *Am J Med Sci* 1984;287:36-8.
- Primary immunodeficiency diseases. Report of an IUIS Scientific Committee. International Union of Immunological Societies. *Clin Exp Immunol* 1999;118(Suppl 1):1-28.
- Suzuki Y. Host resistance in the brain against *Toxoplasma gondii*. *J Infect Dis* 2002;185(Suppl 1):S58-65.
- Kang H, Remington JS, Suzuki Y. Decreased resistance of B cell-deficient mice to infection with *Toxoplasma gondii* despite unimpaired expression of IFN-gamma, TNF-alpha, and inducible nitric oxide synthase. *J Immunol* 2000;164:2629-34.
- Combe CL, Curiel TJ, Moretto MM, Khan IA. NK cells help to induce CD8(+) T-cell immunity against *Toxoplasma gondii* in the absence of CD4(+) T cells. *Infect Immun* 2005;73:4913-21.

