CASE REPORT

# A case of disseminated infection caused by *Streptococcus equi* subspecies *zooepidemicus*

Marie-France Poulin MD[1], Guy Boivin MD MSc[2]

**M-F Poulin, G Boivin. A case of disseminated infection caused by *Streptococcus equi* subspecies *zooepidemicus*. Can J Infect Dis Med Microbiol 2009;20(2):59-61.**

Human infections with *Streptococcus equi* subspecies *zooepidemicus*, a group C streptococcus, are very rare and are generally associated with contact with horses, and consumption of unpasteurized milk products, goat cheese or pork. In most cases *S zooepidemicus* leads to fulminant infections. The case of a middle-aged woman who had sporadic contact with horses is described in the present report. She developed a bacteremia with severe and extensive complications that included meningitis, mitral endocarditis and blindness due to bilateral endophthalmitis. To the authors' knowledge, this is the first reported case of an endophthalmitis due to *S zooepidemicus*. Because of a penicillin allergy, the patient was treated with ceftriaxone and rifampin over six weeks and survived. The present case report highlights the severe complications associated with *S zooepidemicus* infection.

**Key Words:** *Cerebral septic emboli; Endocarditis; Endophthalmitis; Group C streptococcus; Meningitis;* Streptococcus equi *subspecies* zooepidemicus

## Infection disséminée à *Streptococcus equi*, sous-espèce *zooepidemicus*

Les infections à *Streptococcus equi*, sous-espèce *zooepidemicus*, qui appartient aux streptocoques du groupe C, sont très rares chez l'humain et généralement consécutives à des contacts avec des chevaux ou à la consommation de produits laitiers non pasteurisés, de fromage de chèque et de porc. Dans la plupart des cas, *S. zooepidemicus* cause des infections fulminantes. On présente ici le cas d'une femme d'âge moyen ayant eu des contacts sporadiques avec des chevaux. Elle a présenté une bactériémie accompagnée de complications graves et disséminées incluant méningite, endocardite mitrale, cécité due à une endophtalmite bilatérale. À la connaissance de l'auteur, il s'agit du premier cas signalé d'endophtalmite à *S. zooepidemicus*. En raison d'une allergie à la pénicilline, la patiente a été traitée au moyen de ceftriaxone et de rifampin pendant six semaines et elle a survécu. Ce cas rappelle la gravité des complications associées à l'infection à *S. zooepidemicus*.

## CASE PRESENTATION

A 59-year-old Caucasian woman presented to the emergency department in Quebec City, Quebec, on February 3, 2008, complaining of generalized weakness and light headedness when standing up. Her symptoms had appeared three weeks earlier and had worsened over the previous three days. She reported being more dyspneic, vomiting once and having resting tremors. She also mentioned having clear rhinorrhea and a cough that had appeared in the past three days. No change in her medications had been recently made.

Her medical history included refractory hypertension, diabetes mellitus type 2 controlled by oral medication, dyslipidemia, myocardial infarction in 2000, chronic renal failure, obesity, left ophthalmic vein thrombosis, ostium primum atrial septal defect, hypothyroidism, primary hyperparathyroidism caused by an adenoma and anemia caused by vitamin $B_{12}$ deficiency. The patient was allergic to penicillin. Her medication included six antihypertensive drugs, two hypoglycemic agents, Synthroid (Abbott Laboratories, USA), acetylsalicylic acid and vitamin $B_{12}$.

Her vital signs on admission included a blood pressure of 102/57 mmHg, a heart rate of 97 beats/min, a respiratory rate of 20 breaths/min and an oral temperature of 38.5°C. Her complete physical examination was normal, except for bilateral leg edema. No heart murmur was noted at that time. Laboratory results showed a white blood cell count of $10.7\times10^9$/L with a neutrophilic predominance, hemoglobin level of 90 g/L and C-reactive protein level of 178 mg/L. An electrocardiogram that was performed on admission was normal. Urinalysis was normal except for the presence of protein; the culture results showed contamination. A chest x-ray showed atelectasis at the two pulmonary bases.

A presumptive diagnosis of severe orthostatic hypotension and undifferentiated fever was made. However, the next morning, she complained of severe decreased bilateral visual acuity. An ophthalmological examination and vitreous cultures were consistent with bilateral endophthalmitis. On the third day postadmission, the patient developed an altered mental status, and her cerebrospinal fluid (CSF) results were consistent with the diagnosis of meningitis. The CSF obtained was turbid with a white blood cell count of $2560\times10^6$/L with 89% neutrophils, a red blood cell count of $135\times10^6$/L, a glucose level of 2.3 mmol/L (normal 2.7 mmol/L to 4.4 mmol/L) and a protein level of 2.22 g/L (normal 0.09 g/L to 0.46 g/L). The CSF Gram stain and culture obtained 16 h after the patient received her first dose of antibiotic were negative. CSF antigens for *Haemophilus influenzae* type B, *Streptococcus pneumoniae*, group B streptococcus, *Neisseria meningitidis* A/C/W-135/Y and *N meningitidis* group B/*Escherichia coli* K1 were also negative.

On day 3 postadmission, anomalies on an electrocardiogram and increase in troponins led to a transesophageal echocardiogram that revealed a mobile vegetation of 7 mm × 13 mm on the posterior leaflet of the mitral valve and anteroseptal akynesia – all consistent with the diagnosis of endocarditis. Repeated transesophageal echocardiograms on the following days showed that the

[1]*Laval University;* [2]*CHUQ-CHUL; Holder of the Canada Research Chair on Emerging Viruses and Antiviral Resistance, Laval University, Quebec City, Quebec*

*Correspondence: Dr Guy Boivin, CHUL, local RC-709, 2705 boulevard Laurier, Quebec City, Quebec G1V 4G2. Telephone 418-654-2705, fax 418-654-2715, e-mail guy.boivin@crchul.ulaval.ca*

*Received for publication July 3, 2008. Accepted November 12, 2008*

  

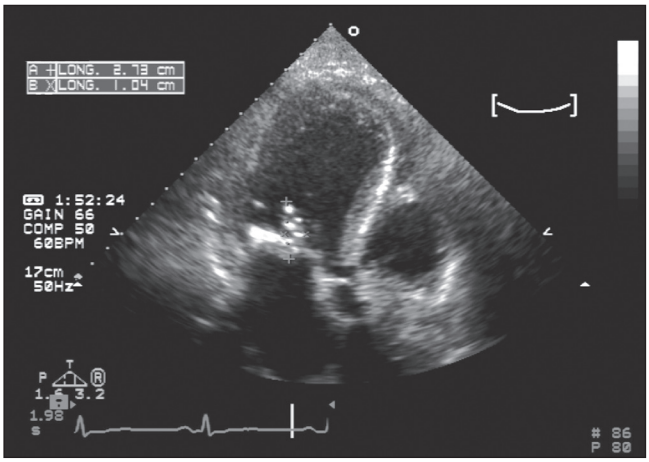


**Figure 1)** *Transesophageal echocardiogram showing a mobile vegetation on the posterior leaflet of the mitral valve measuring 10 mm × 27 mm in a patient with* Streptococcus equi *subspecies* zooepidemicus *bacteremia*

vegetation increased in size, reaching 10 mm × 27 mm on day 24 postadmission (Figure 1). Following confusion and new face numbness on day 22 postadmission, a magnetic resonance imaging examination was performed, which revealed multiple cerebral and splenic septic emboli. This led to a mitral valve replacement with a triple coronary artery bypass and closure of her atrial septal defect one month after admission. The patient also developed acute renal failure with a maximum blood creatinine value of 356 µmol/L on day 4 postadmission. A renal scan performed on day 26 of her hospitalization showed hypoperfusion with severe functional failure caused by nephrosclerosis. She also developed significant proteinuria (4.27 g/L per day), and the possibility of renal septic emboli was suspected. She was also diagnosed with neurosensorial deafness due to her meningitis.

Blood cultures drawn on the first day of admission and vitreous humor cultures performed the next day both returned positive for *Streptococcus equi* subspecies *zooepidemicus*. This pathogen was identified using the VITEK 2 system (bioMérieux sa, France). Time to positivity was 24 h for the blood culture. The pathogen was susceptible to all tested antibiotics according to the Clinical and Laboratory Standard Institute criteria. Minimal inhibitory concentrations obtained by the E-test method for the blood isolate were 0.023 mg/L for penicillin and 0.094 mg/L for ceftriaxone. For vitreous humor isolates, the minimal inhibitory concentrations for penicillin, ceftriaxone and vancomycin were 0.032 mg/L, 0.094 mg/L and 0.75 mg/L, respectively.

The patient received intravenous ceftriaxone (2 g every 12 h) and rifampin (600 mg per day) for six weeks, and her general condition gradually improved after cardiac surgery, except for her visual acuity. Despite a bilateral vitrectomy performed on day 11 after admission with intravitreous injection of antibiotics (vancomycin, ceftriaxone and dexamethasone), she was diagnosed with permanent total blindness due to retinal detachments. Control blood cultures performed after 24 h of treatment and one week after the end of the six-week antibiotic course were negative.

On detailed questioning, the patient denied consumption of unpasteurized milk products. There was a stable on her property, but she only went there occasionally. She denied close contact with horses, but her husband worked at the stable daily. None of the horses was known to be sick. To our knowledge, there were no other animals on her property, except for a dog that was known to be healthy. The patient denied use of intravenous drugs and did not remember having open wounds. She had seen her dentist one month before the onset of symptoms for an unknown procedure.

The patient was still blind when she left the hospital 40 days after admission. Her chronic renal failure had worsened and she remained anemic, which necessitated multiple blood transfusions. The patient also had left neurosensorial deafness and was diagnosed with depression. A cataract surgery was scheduled one week after her discharge from the hospital.

## DISCUSSION

*S equi* subspecies *zooepidemicus* is a Lancefield group C beta-hemolytic streptococcus. It is known to infect animals such as horses, cattle, sheep and pigs (1,2). Group C streptococci also include *S equi* subspecies *equi*, *Streptococcus dysgalactiae* subspecies *dysgalactiae* and *S dysgalactiae* subspecies *equisimilis*. All these *Streptococcus* species can infect horses except *S dysgalactiae*, which usually causes mastitis in bovines (3).

*S zooepidemicus* is commonly responsible for respiratory tract and wound infections in foals and young horses (4). It rarely infects humans and, in most cases, can be traced to an animal source (5-7). It has been associated with consumption of unpasteurized cow and goat milk products, as well as with close contacts with horses (5,8,9). A few cases were also linked to pork consumption (10). The usual entry routes of *S zooepidemicus* in humans are the respiratory or gastrointestinal tracts and skin wounds (1).

Many underlying medical conditions have been reported in patients infected with group C streptococci such as diabetes mellitus, cardiopulmonary disease, chronic dermatological conditions, immunosuppression, malignancy, alcohol abuse, use of injection drugs and renal or hepatic failure (11). The mortality rate associated with *S zooepidemicus* infections has been reported to be 33% to 66%, and fatal cases have mainly been described in the elderly, neonates and patients with one of the comorbidities mentioned above (1,12,13). When infecting humans, *S zooepidemicus* can lead to bacteremia, endocarditis, meningitis, pneumonia, poststreptococcal glomerulonephritis, arthritis, pharyngitis, lymphadenitis, osteomyelitis, aortic aneurysm and streptococcal toxic shock-like syndrome (4,5,10,11,14-17). Human infections with this pathogen are rare, but usually aggressive (1). Group C streptococcus endocarditis is uncommon as shown in a review of 4705 cases of infective endocarditis, in which it accounted for less than 1% of cases (18). Yuen et al (10) also reported that the frequency of endocarditis associated with *S zooepidemicus* bacteremia was 13%.

Bacteremia due to group C streptococci is also uncommon and is known to cause less than 1% of all bacteremias (19-21). Only 11 cases of *S zooepidemicus* meningitis have been reported in the medical literature as of 2001 (7), and very few meningeal infections have been described in Canada (4,22). There are only eight outbreaks caused by *S zooepidemicus* reported in the literature, and none of them took place in Canada (13). To the best of our knowledge, this is the first reported case of an endophthalmitis due to *S zooepidemicus*.

Penicillin G or cephalosporins are the treatment of choice for group C streptococcus infections (6). Gentamicin or rifampin

can be used with a beta-lactam antibiotic or vancomycin for synergy against this pathogen (23). A combination of penicillin and gentamicin seems to be associated with a better outcome in patients with endocarditis by decreasing the need for valve replacement (11).

Our patient was a middle-aged woman with diabetes and chronic renal failure. She presented with bacteremia and rapidly developed several complications from which she had significant sequelae, most notably permanent blindness. This bacteremic event led to subsequent endocarditis, endophthalmitis, meningitis and cerebral emboli. While this was most likely a zoonotic infection, it is also possible that the patient's recent dental procedure contributed to the bacteremia. Of note, she had only sporadic contact with horses and had been the only one in her household to develop such an infection. The patient could not receive penicillin due to her allergy; thus, she was treated with ceftriaxone and rifampin. Following initiation of treatment, her blood cultures rapidly became negative within 24 h. Despite this rapid microbial eradication, she had a disseminated infection with some permanent sequelae.

It is, therefore, important to always consider *S zooepidemicus* as a possible pathogen when contact with horses or consumption of unpasteurized cow's milk products are advocated. Similarly, it is imperative to rapidly treat such infections to prevent further dissemination.

## REFERENCES


1. Bradley SF, Gorgon JJ, Baumgartner DD, et al. Group C streptococcal bacteremia: Analysis of 88 cases. Rev Infect Dis 1991;13:270-80.
2. Berenguer J, Sampedro I, Cercenado, et al. Group C β-haemolytic streptococcal bacteremia. Diagn Microbiol Infect Dis 1992;15:151-5.
3. Wilson CD, Salt GF. Streptococci in animal disease. In: Skinner FA, Quesnel LB, eds. Streptococci. New York: Academic Press; 1978:143-56.
4. Downar J, Willey BM, Sutherland JW, et al. Streptococcal meningitis resulting from the contact with an infected horse. J Clin Microbiol 2001;39:2358-9.
5. Barnham M, Kerby J, Chandler RS, et al. Group C streptococci in human infection: A study of 308 isolates with clinical correlations. Epidemiol Infect 1989;102:379-90.
6. Johnson CC, Tunkel AR. Viridans streptococci and groups C and G streptococci. In: Mandell GL, Bennett JE, Dolin R, eds. Principles and Practice of Infectious Diseases, 4th edn. New York: Churchill Livingstone; 1995:1845-61.
7. Shah SS, Matthews RP, Cohen C. Group C streptococcal meningitis: Case report and review of the literature. Pediatr Infect Dis J 2001;20:445-8.
8. Centers for Disease Control and Prevention. Group C streptococcal infection associated with eating homemade cheese – New Mexico. MMWR Morb Mortal Wkly Rep 1983;32:510-6.
9. Kuusi M, Lahti E, Virolainen A, et al. An outbreak of *Streptococcus equi* subspecies *zooepidemicus* associated with consumption of fresh goat cheese. BMC Infect Dis 2006;6:36.
10. Yuen KY, Seto WH, Choi CH, et al. *Streptococcus zooepidemicus* (Lancefield group C) septicaemia in Hong Kong. J Infect 1990;21:241-50.
11. Salata RA, Lerner PI, Shlaes DM, et al. Infections due to Lancefield group C streptococci. Medicine 1989;68:225-39.
12. Edwards AT, Roulson M, Ironside MJ. A milk-borne outbreak of serious infection due to *Streptococcus zooepidemicus* (Lancefield group C). Epidem Infect 1988;101:43-51.
13. Bordes-Benitez A, Sanchez-Onoro M, Suarez-Bordon P, et al. Outbreak of *Streptococcus equi* subsp. *zooepidemicus* infections on the island of Gran Canaria associated with the consumption of inadequately pasteurized cheese. Eur J Clin Microbiol Infect Dis 2006;25:242-6.
14. Barnham M, Thorton TJ, Lange K. Nephritis caused by *Streptococcus zooepidemicus* (Lancefield group C). Lancet 1983;1:945-8.
15. Balter S, Benin A, Pinto SWL, et al. Epidemic nephritis in Nova Serrana, Brazil. Lancet 2000;355:1776-80.
16. Albarracin C, Rosencrance G, Boland J, et al. Bacteremia due to *Streptococcus zooepidemicus* associated with an abdominal aortic aneurysm. WV Med J 1998;94:90-2.
17. Korman TM, Boers A, Gooding TM, et al. Fatal case of toxic shock-like syndrome due to group C streptococcus associated with superantigen exotoxin. J Clin Microbiol 2004;42:2866-9.
18. Blair DC, Martin DB. B-hemolytic streptococcal endocarditis: Predominance of non-group-A organisms. Am J Med Sci 1978;276:269-77.
19. Mohr DN, Feist DJ, Washington JA II, et al. Infections due to group C streptococci in man. Am J Med 1979;66:450-6.
20. Skogberg K, Simonen H, Renkonen OV, et al. β-hemolytic group A, B, C and G streptococcal septicaemia: A clinical study. Scand J Infect Dis 1988;20:119-25.
21. Carmeli Y, Ruoff KL. Report of cases and taxonomic considerations for large-colony-forming Lancefield group C streptococcal bacteremia. J Clin Microbiol 1995;33:2114-7.
22. Elsayed S, Hammerberg O, Massey V, et al. *Streptococcus equi* subspecies *equi* (Lancefield group C) meningitis in a child. Clin Microbiol Infect 2003;9:869-72.
23. Portnoy D, Prends E, Richards GK. Penicillin tolerance of human isolates of group C streptococci. Antimicrob Agents Chemother 1981;20:235-8.