

Cladophialophora bantiana brain abscess in an immunocompetent patient

Sanjay G Revankar MD

SG Revankar. *Cladophialophora bantiana* brain abscess in an immunocompetent patient. Can J Infect Dis Med Microbiol 2011;22(4):149-150.

Cladophialophora bantiana is a dematiaceous mold with a predilection for causing central nervous system infection, particularly in normal hosts. A case involving a 79-year-old immunocompetent woman who presented with left-sided weakness and a ring-enhancing brain lesion is reported. She underwent surgical excision, which revealed a brain abscess due to *C bantiana*. The patient was treated with liposomal amphotericin B for several weeks, then switched to voriconazole and flucytosine, but eventually succumbed to the infection. Therapy is not standardized for this rare mycosis, and mortality remains high, even in immunocompetent patients. Additional studies to understand the pathogenesis of this infection and to improve outcomes are needed.

Key Words: Brain abscess; *Cladophialophora bantiana*; Flucytosine; Liposomal amphotericin B; Phaeohyphomycosis, Voriconazole

Cladophialophora bantiana is a dematiaceous mold that is a rare cause of human disease or phaeohyphomycosis. However, it is relatively unique due to its predilection to be involved in central nervous system infection, particularly in immunocompetent patients of widely varying ages (1). It has a worldwide distribution and is likely a soil organism, although its exact ecological niche is unknown. It is the most commonly isolated dematiaceous species from brain abscesses (1). For unclear reasons, most patients are male. Therapy is not standardized, and mortality rates are high (>70% in one large series [1]). We report a case of brain abscess due to *C bantiana* in an immunocompetent woman.

CASE PRESENTATION

A 79-year-old woman with a history of hypertension, diverticulitis, recent pulmonary embolus and deep venous thrombosis presented with progressive left-sided facial droop and left-sided weakness for 10 days. She denied headache, fever, nausea or vomiting. She had no allergies and was taking medications for hypertension. No recent travel, pets or unusual exposures were reported. On examination, the patient was afebrile and alert, but was occasionally confused. Neurological deficits noted were left facial weakness and mild left-sided upper and lower extremity weakness. Her laboratory studies were normal. Magnetic resonance imaging of the brain demonstrated a 2 cm × 3 cm right frontal ring-enhancing mass with a small satellite lesion (Figure 1). Malignancy was initially suspected, and she underwent surgical excision of the larger mass lesion. Pathology showed an abscess with necrotizing granulomatous inflammation with brown, irregular hyphal elements on hematoxylin-eosin staining. The cultures grew *C bantiana*. Susceptibility testing was not available. The patient was treated with liposomal amphotericin B at doses ranging from 3 mg/kg/day to 5 mg/kg/day for five weeks; follow-up imaging initially demonstrated a decrease in the size of the remaining lesion after three weeks of therapy, although an increase in enhancement was noted at five weeks. At that time, she had developed progressive nausea and vomiting, which were believed to be due to refractory

Un abcès cérébral à *Cladophialophora bantiana* chez une patiente immunocompétente

Le *Cladophialophora bantiana* est une moisissure dématiacée qui a tendance à provoquer une infection du système nerveux central, notamment chez les hôtes en santé. Les auteurs exposent le cas d'une femme immunocompétente de 79 ans qui a consulté en raison d'une faiblesse du côté droit et d'une lésion cérébrale à prise de contraste annulaire. Elle a subi une excision chirurgicale, qui a révélé un abcès cérébral causé par le *C bantiana*. La patiente a été traitée par amphotéricine B liposomale pendant plusieurs semaines, puis au voriconazole et à la flucytosine, mais a fini par succomber à l'infection. Il n'existe pas de traitement standardisé pour traiter cette mycose rare, et la mortalité demeure élevée, même chez les patients immunocompétents. Des études supplémentaires s'imposent pour comprendre la pathogenèse de cette infection et améliorer les issues.

disease or intolerance to the amphotericin B. Therapy was switched to voriconazole and flucytosine for one week, although this was also discontinued secondary to intractable nausea and vomiting. However, she continued to deteriorate and was placed in a hospice with no further antifungal therapy at the family's request. She died one month later. The cause of death was believed to be progressive fungal infection.

DISCUSSION

C bantiana brain abscess is a rare and frequently fatal infection, often seen in immunocompetent individuals. Clinical presentation may be indistinguishable from malignancy, and men are predominantly affected for unclear reasons. The first reported case of this infection was by Binford et al (2) in 1952 involving a 22-year-old American man who had no underlying immunodeficiency. Many recent cases have been reported from India including a series of 10 cases from a single institution over a 27-year period (3). All of these cases were in immunocompetent males. The mortality rate in this large series was more than 70%, despite aggressive medical and surgical therapy (1).

There are no prospective trials that help define optimal therapy; consequently, no standardized approach exists for these infections. Amphotericin B (including lipid preparations) is the most commonly used agent. Itraconazole and voriconazole have broad activity against dematiaceous fungi and are often used for these infections (4). Voriconazole has been used in a number of case reports, due to its broad activity and good cerebrospinal fluid penetration; however, failures have been reported (5). The use of an alternative agent, such as itraconazole, may be reasonable if the patient does not respond to voriconazole. While itraconazole does not achieve useful cerebrospinal fluid levels, penetration into the brain tissue appears to be good (6). Another option may be posaconazole, which was used successfully in a brain abscess case due to another dematiaceous species – *Ramichloridium mackenzii*, which is particularly difficult to treat (7). While the newer azoles are likely to have good penetration into the brain tissue (6), serum levels should be monitored in patients

Division of Infectious Diseases, Wayne State University, Detroit, Michigan, USA

Correspondence: Dr Sanjay G Revankar, Harper University Hospital, 3990 John R Street, 5 Hudson, Detroit, Michigan 48201, USA.

Telephone 313-745-8599, fax 313-993-0302, e-mail srevankar@med.wayne.edu

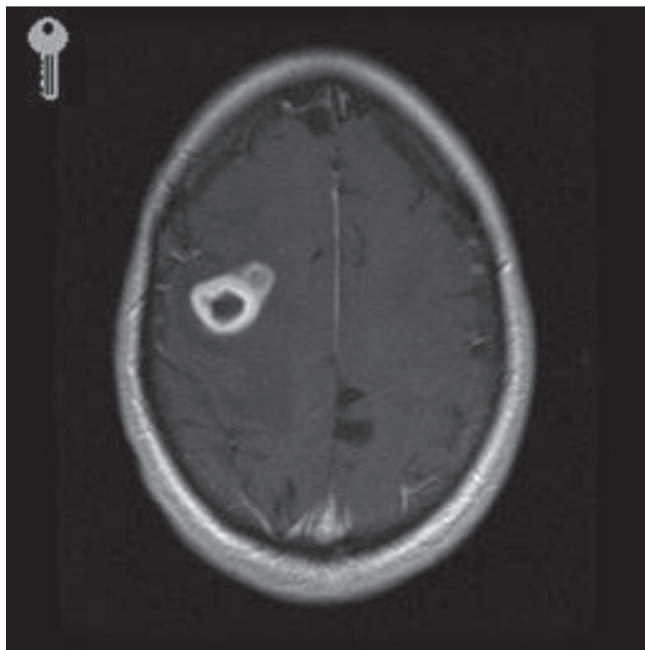


Figure 1) Magnetic resonance imaging of the brain showing right frontal abscess with ring enhancement and satellite lesion

receiving prolonged therapy, although correlation between serum and brain tissue levels is lacking. Flucytosine is another agent with good in vitro activity against *C. bantiana*; a recent study in mice showed that adding flucytosine to posaconazole improved survival (8). In reviews of phaeohyphomycosis cases involving the central nervous system, the use of flucytosine was associated with several

successfully treated cases (in addition to amphotericin B and itraconazole) (1,3). Complete resection of the abscess was also found to be associated with improved outcomes (1). In our patient, complete resection was not possible, and she did not tolerate liposomal amphotericin B or the combination of voriconazole and flucytosine, and eventually succumbed to the infection. Based on the European Organization for Research and Treatment of Cancer/Mycoses Study Group criteria for response to therapy in invasive fungal infections, our patient would be considered a clinical failure due to progressive disease at end of therapy (9). Although the use of high doses of liposomal amphotericin B (≥ 10 mg/kg/day) has been advocated in the treatment of central nervous system fungal infections (10), its use in our patient was not possible due to intolerance of standard doses of liposomal amphotericin B.

Patients with mass lesions of the brain should always have tissue sent for culture (including for fungi). Clinicians must consider fungal infection in the differential diagnosis of these patients, even if they are immunocompetent. Fungal brain abscess carries a poor prognosis, regardless of underlying disease. Based on available data and experience, complete surgical resection appears to be necessary for optimal outcomes. Therapy with amphotericin B alone (standard or lipid preparations) may not be adequate. Some successfully treated cases used itraconazole and/or flucytosine in combination with amphotericin B, although few have been documented. The newer azole antifungals, such as voriconazole and posaconazole, may also have a role in therapy, based on their good in vitro activity (11). The optimal therapeutic regimen is not known, although some combination of agents is likely better than monotherapy (8,12). Prolonged follow-up (>1 year) is essential because relapses are not uncommon.

ACKNOWLEDGEMENTS: The author thanks William Sutker for providing details of the clinical aspects of the case.

REFERENCES

- Revankar SG, Sutton DA, Rinaldi MG. Primary central nervous system phaeohyphomycosis: A review of 101 cases. *Clin Infect Dis* 2004;38:206-16.
- Binford CH, Thompson RK, Gorham ME, et al. Mycotic brain abscess due to *Cladosporium trichoides*, a new species. *Am J Clin Pathol* 1952;22:535-42.
- Garg N, Devi IB, Vajramani GV, et al. Central nervous system cladosporiosis: An account of ten culture-proven cases. *Neurol India* 2007;55:282-8.
- Revankar SG. Therapy of infections caused by dematiaceous fungi. *Expert Rev Anti-Infect Ther* 2005;3:601-12.
- Fica A, Diaz MC, Luppi M. Unsuccessful treatment with voriconazole of a brain abscess due to *Cladophialophora bantiana*. *Scand J Infect Dis* 2003;35:892-3.
- Groll AH, Piscitelli SC, Walsh TJ. Clinical pharmacology of systemic antifungal agents: A comprehensive review of agents in clinical use, current investigational compounds, and putative targets for antifungal drug development. *Adv Pharmacol* 1998;44:443-99.
- Al Abdely HM, Alkhunaizi AM, Al Tawfiq JA, Hassounah M, Rinaldi MG, Sutton DA. Successful therapy of cerebral phaeohyphomycosis due to *Ramichloridium mackenziei* with the new triazole posaconazole. *Med Mycol* 2005;43:91-5.
- Marine M, Pastor FJ, Guarro J. Combined antifungal therapy in a murine model of disseminated infection by *Cladophialophora bantiana*. *Med Mycol* 2009;47:45-9.
- Segal BH, Herbrecht R, Stevens DA, et al. Defining responses to therapy and study outcomes in clinical trials of invasive fungal diseases: Mycoses Study Group and European Organization for Research and Treatment of Cancer consensus criteria. *Clin Infect Dis* 2008;47:674-83.
- Walsh TJ, Goodman JL, Pappas P, et al. Safety, tolerance, and pharmacokinetics of high-dose liposomal amphotericin B (AmBisome) in patients infected with *Aspergillus* species and other filamentous fungi: Maximum tolerated dose study. *Antimicrob Agents Chemother* 2001;45:3487-96.
- Badali H, de Hoog GS, Curfs-Breuker I, Klaassen CH, Meis JF. Use of amplified fragment length polymorphism to identify 42 *Cladophialophora* strains related to cerebral phaeohyphomycosis with in vitro antifungal susceptibility. *J Clin Microbiol* 2010;48:2350-6.
- Li DM, de Hoog GS. Cerebral phaeohyphomycosis – a cure at what lengths? *Lancet Infect Dis* 2009;9:376-83.

