

Case Report

Singleton Merten Syndrome: A Rare Cause of Early Onset Aortic Stenosis

Harshavardhan Ghadium¹ and Sudhir Mungee²

¹Department of Medicine, University of Illinois College of Medicine at Peoria, Peoria, IL, USA

²Division of Cardiology, University of Illinois College of Medicine at Peoria, Peoria, IL, USA

Correspondence should be addressed to Harshavardhan Ghadium; gharsha@uic.edu

Received 14 November 2016; Revised 31 January 2017; Accepted 1 February 2017; Published 21 February 2017

Academic Editor: Ramazan Akdemir

Copyright © 2017 Harshavardhan Ghadium and Sudhir Mungee. This is an open access article distributed under the Creative Commons Attribution License, which permits unrestricted use, distribution, and reproduction in any medium, provided the original work is properly cited.

Singleton Merten syndrome (SMS) is a rare autosomal dominant genetic disorder with variable expression. Its characteristic features include abnormal aortic calcification, abnormal ossification of extremities, and dental anomalies. We present a young man with dyspnea who was noted to have aortic stenosis in the background of glaucoma, psoriasis, dental anomalies, hand and foot deformities, Achilles tendinitis, osteopenia, and nephrolithiasis. The conglomeration of features led to the diagnosis of SMS. His mother had a very similar phenotype.

1. Introduction

SMS is an autosomal dominant disorder with variable expression [1]. It is associated with abnormal calcification in vascular and connective tissues causing aortic calcification and aortic valve stenosis [1]. The pathophysiology of abnormal calcification is unknown but is likely linked to gain-of-function *IFIH1* mutation [2]. We had a young male patient who presented for dyspnea and palpitations and was noted to have mild aortic stenosis.

2. Case Report

A 30-year-old male with a past medical history of early onset glaucoma, multiple trabeculectomies, delayed eruption of permanent dentition, progressive hand deformities (Figure 1), psoriasis, recurrent nephrolithiasis, Achilles tendinitis, tendon rupture, foot deformities (Figure 2), and hypoplastic toe nails presented for evaluation of dyspnea on exertion and palpitations. Symptoms have been ongoing for three months with gradual worsening. His family history was significant for premature coronary artery disease in his mother and aortic

stenosis with aortic valve replacement when she was 31 years old.

Physical examination showed grade 3/6 systolic murmur in the left second intercostal space, hallux valgus deformities in the feet (Figure 2), and dysplastic dentition (Figure 3).

The patient underwent an echocardiogram which revealed moderate mitral annular calcification, mild aortic stenosis (Figure 4) with partial fusion of noncoronary and left coronary cusps, and calcified leaflets, with a peak gradient of 24.4 mm Hg and mean gradient of 13 mm Hg and peak velocity of 2.47 m/s. Thirty-day event recorder was unremarkable. Imaging revealed minimal hyperostosis at triceps insertion on the ulna. It also revealed right hallux valgus deformity and peritendinous calcification of bilateral patellar tendons. CT chest revealed minimal calcification of aortic arch and abdominal aorta, calcification of aortic valve, and ductus arteriosus remnant. Genetic testing revealed autosomal dominant *IFIH1* mutation.

Repeat echocardiogram in one year showed moderate aortic stenosis with peak velocity of 3.16 m/s, peak gradient of 40 mmHg and mean gradient of 20 mmHg, and aortic valve of 0.98 cm².



FIGURE 1: Hand deformities.

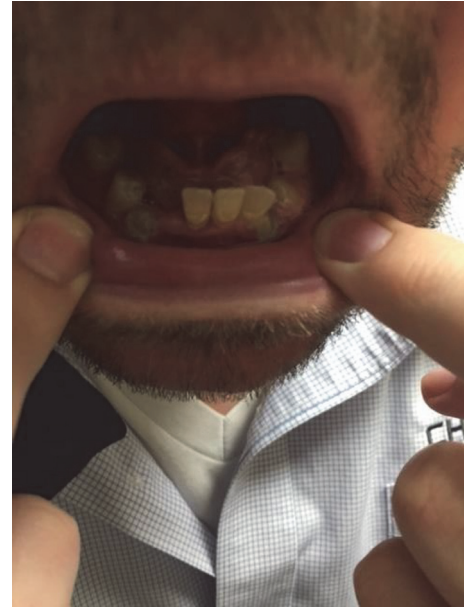


FIGURE 3: Dysplastic permanent teeth.

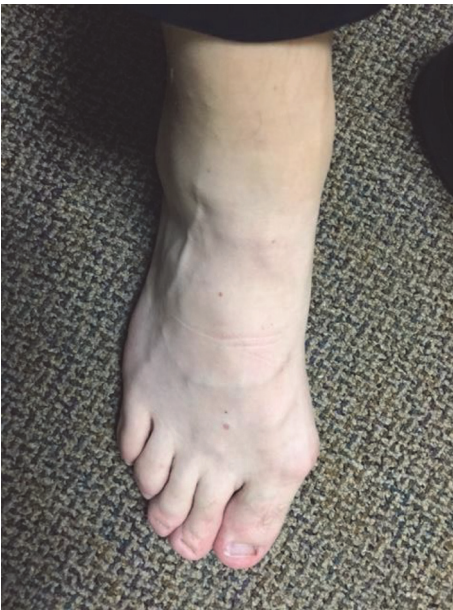

FIGURE 2: Hallux valgus.

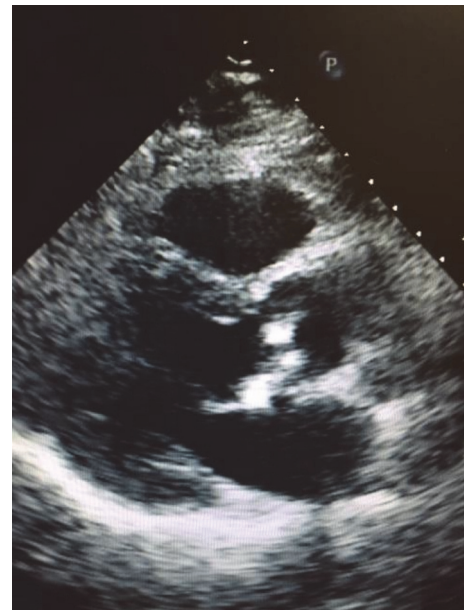

FIGURE 4: Aortic stenosis with calcified leaflets.

3. Discussion

Our patient had features similar to Singleton Merten syndrome including glaucoma, dysplastic permanent teeth, multiple tendon rupture, and extensive vascular calcification. Singleton Merten syndrome is an autosomal dominant disorder with variable expression. His mother had a similar phenotype.

SMS is a rare disease, with very few cases reported in the literature. Common features include abnormal aortic calcification, abnormal ossification of extremities, and dental

anomalies [3, 4]. Other associated features are glaucoma, psoriasis [4], tendinitis, and osteoporosis [1].

The pathophysiology of the disease is unclear in regard to the abnormal calcification of vascular and connective tissues with a possible link to abnormal calcium metabolism [1, 5]. Our patient had normal laboratory evaluation for calcium metabolism. Genetic testing in subjects with SMS has revealed a gain-of-function *IFIH1* mutation likely causing premature arterial calcification and dental inflammation [2].

The patient is currently followed up by a multidisciplinary team and is being monitored for the progression of aortic stenosis.

Although this disease is not unique, not many cases have been described before. Due to its rarity, we hope this case would help in understanding this rare and complex disease.

Competing Interests

The authors declare that there are no competing interests regarding the publication of this paper.

References

- [1] A. Feigenbaum, C. Müller, C. Yale et al., “Singleton-Merten syndrome: an autosomal dominant disorder with variable expression,” *American Journal of Medical Genetics, Part A*, vol. 161, no. 2, pp. 360–370, 2013.
- [2] F. Rutsch, M. MacDougall, C. Lu et al., “A specific IFIH1 gain-of-function mutation causes singleton-merten syndrome,” *The American Journal of Human Genetics*, vol. 96, no. 2, pp. 275–282, 2015.
- [3] A. Ozyuksel, C. Ersoy, E. Canturk, and A. Akcevin, “Progressive supra-aortic stenosis in a young adult with the findings of Singleton Merten Syndrome,” *BMJ Case Reports*, 2014.
- [4] A.-C. Bursztejn, T. A. Briggs, Y. del Toro Duany et al., “Unusual cutaneous features associated with a heterozygous gain-of-function mutation in IFIH1: overlap between Aicardi-Goutières and Singleton–Merten syndromes,” *British Journal of Dermatology*, vol. 173, no. 6, pp. 1505–1513, 2015.
- [5] M.-A. Jang, E. K. Kim, H. Now et al., “Mutations in DDX58, which encodes RIG-I, cause atypical singleton-merten syndrome,” *The American Journal of Human Genetics*, vol. 96, no. 2, pp. 266–274, 2015.



Hindawi
Submit your manuscripts at
<https://www.hindawi.com>

