



Case Report

Acute Splenic Artery Thrombosis and Infarction Associated with COVID-19 Disease

Osama Qasim Agha ^{1,2,3} and Ryan Berryman ^{1,2}

¹Department of Internal Medicine, Creighton University School of Medicine, Phoenix, Arizona, USA

²Department of Internal Medicine, St Joseph's Hospital and Medical Center, Phoenix, Arizona, USA

³Department of Internal Medicine, University of Arizona College of Medicine, Phoenix, Arizona, USA

Correspondence should be addressed to Osama Qasim Agha; osmagha@gmail.com

Received 17 July 2020; Revised 21 August 2020; Accepted 30 August 2020; Published 4 September 2020

Academic Editor: Mehmet Doganay

Copyright © 2020 Osama Qasim Agha and Ryan Berryman. This is an open access article distributed under the Creative Commons Attribution License, which permits unrestricted use, distribution, and reproduction in any medium, provided the original work is properly cited.

Coronavirus 2019 disease (COVID-19) is a viral illness caused by severe acute respiratory syndrome coronavirus 2 (SARS-CoV-2). It emerged in Wuhan, China, in December 2019 and has caused a widespread global pandemic. The symptoms of COVID-19 can vary from mild upper respiratory symptoms to severe pneumonia with hypoxemic respiratory failure. Multiple studies and reports have reported a hypercoagulable state associated with this disease, and various recommendations have emerged to guide the use of anticoagulants for prophylaxis. We are reporting a case of symptomatic acute splenic thrombosis causing splenic infarction in a patient suffering from a severe case of COVID-19 and despite the use of an intermediate dose of low-molecular-weight heparin (LMWH). The patient was treated with full-dose anticoagulation and was eventually discharged home on a direct oral anticoagulant.

1. Introduction

Approximately 21 million individuals have been diagnosed with COVID-19 worldwide, and approximately 761 thousand fatalities have been reported as of August 21, 2020 [1]. Hypercoagulability leading to venous thromboembolism (VTE) and arterial thrombosis has been reported in multiple studies, and various recommendations to prevent these events have emerged. Multiple ongoing studies are still evaluating the most appropriate dosing to prevent VTE.

2. Case Presentation

A male patient in his 60s presented to the emergency department with worsening dyspnea for two weeks. It was associated with fevers, cough, and diarrhea. He tested positive for COVID-19 one week prior to presentation, and he was started on hydroxychloroquine 400 mg daily by his primary care physician, but his symptoms continued to progress. He had a history of asthma, obstructive sleep apnea, morbid obesity, immunoglobulin G (IgG) deficiency, and hypertension.

His home medications included amlodipine, olmesartan, Hizentra, and the recently prescribed hydroxychloroquine. The patient was a nonsmoker, and he drank alcohol only occasionally. His vital signs included a temperature of 39.5°C, a respiratory rate of 20-24, an oxygen saturation of 90% on room air, and a body mass index of 54 kg/m². He was in no distress, and his lungs were clear on auscultation. The rest of the physical exam was normal. The patient was initially admitted to a telemetry unit but was then transferred to the intensive care unit due to progressive hypoxia requiring high flow oxygen. On day 7 of admission, he complained of moderate, dull, and left-sided abdominal pain that required IV morphine. His abdomen was soft, nondistended, and nontender, and he had no organomegaly on palpation.

On admission, his complete blood count (CBC) and comprehensive metabolic panel (CMP) were unremarkable. However, he had an elevated D-dimer level at 259 ng/ml, CRP level at 86.6 mg/l, ferritin level at 1,472 ng/ml, and procalcitonin level at 0.09 ng/ml. Chest X-ray showed patchy opacities in the right upper and lower lobes. On day 7, his white blood cell count was slightly elevated at 11.2

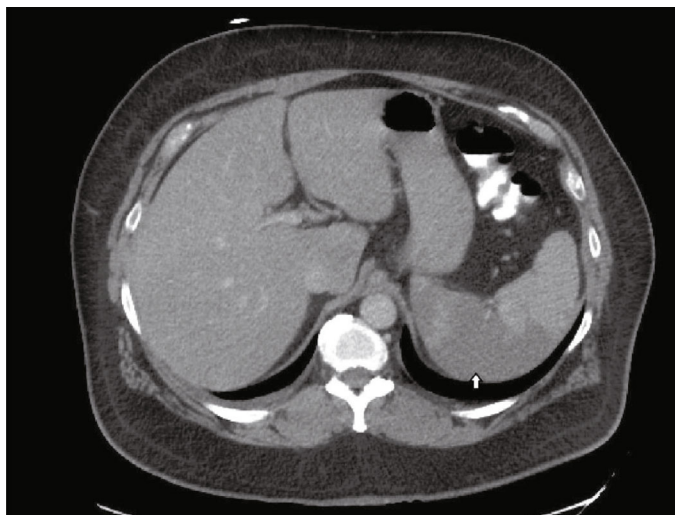


FIGURE 1: An area of hypodensity involving the right half of the spleen consistent with splenic infarction (arrow).

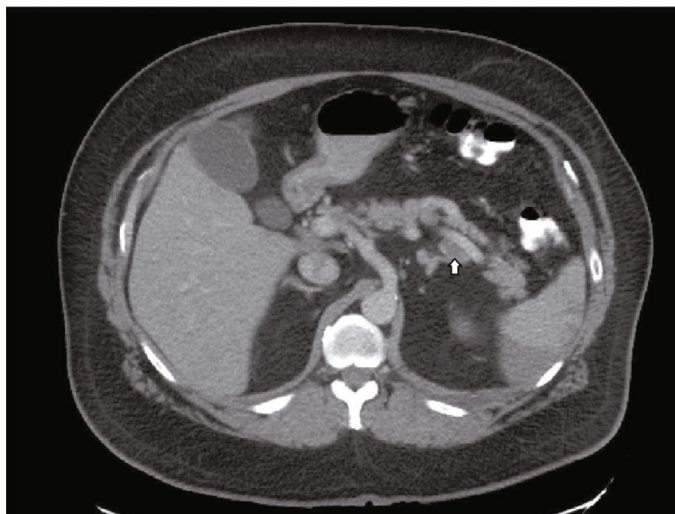


FIGURE 2: A filling defect within the mid to distal splenic artery consistent with splenic artery thrombosis, transverse view.

thousand/ μl and CMP remained unremarkable. His repeat D-dimer level was 1,088 ng/ml, and his repeat ferritin level was 3,038 ng/ml. A CT of the abdomen and pelvis with IV and PO contrast showed acute splenic artery thrombosis and infarction of greater than 50% of the splenic volume (Figures 1–3).

The patient was receiving enoxaparin 40 mg twice daily prior to making the diagnosis of splenic infarction. He was then switched to heparin drip for 24 hours and then to enoxaparin 1 mg/kg twice daily. The patient's respiratory status improved, and he was weaned off oxygen. His abdominal pain also improved gradually, and he required less opiates. On day 21, the patient was discharged home on oral rivaroxaban.

3. Discussion

Hypercoagulability is defined as an increased risk of thrombosis in veins, arteries, or both due to an acquired or a hered-

itary disorder [2]. Splenic infarction is a rare disorder that can present with left-sided abdominal pain and can be secondary to a hypercoagulable state [2]. COVID-19 has been reported in multiple studies to be associated with hypercoagulability and an increased risk for venous and arterial thromboembolism. The reported abnormal coagulation parameters include elevated D-dimer, fibrin degradation products (FDP), and platelet count with low antithrombin values [3–5]. Abnormal thromboelastography (TEG) values, including decreased R and K values and increased values of K angle and MA, are also consistent with hypercoagulability [6]. While earlier studies reported that some patients had prolonged activated partial-thromboplastin time (aPTT) and expressed concern for increased bleeding risk, a recent study found that the majority had positive lupus anticoagulant which can prolong aPTT and is associated with an increased risk of thrombosis [7]. Elevated D-dimer and FDP have also been associated with more severe disease and poorer prognosis [5, 8].

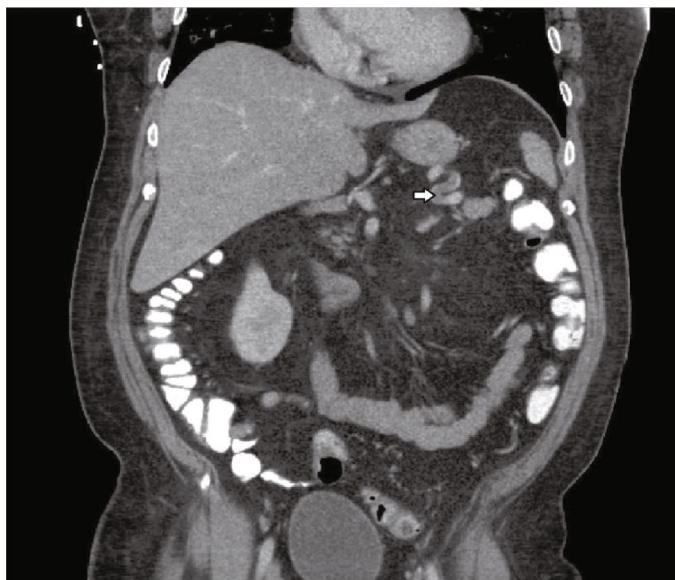


FIGURE 3: A filling defect within the mid to distal splenic artery consistent with splenic artery thrombosis, coronal view.

Pulmonary embolism has been the most common thrombotic event associated with COVID-19 and sometimes despite the use of prophylactic or therapeutic-dose anticoagulation [9, 10]. Large-vessel ischemic stroke and acute upper or lower limb ischemia have also been reported [11–13]. More recently, abdominal visceral infarctions including renal infarction, splenic infarction, and small bowel infarction have been reported [14, 15].

The use of prophylactic-dose low-molecular-weight heparin (LMWH) has been shown to be associated with lower mortality in patients with severe COVID-19 or D-dimer levels more than 6 times the upper normal limit [16]. Current society guidelines support the use of standard prophylactic-dose anticoagulants in all hospitalized patients with COVID-19 in the absence of a clear contraindication [17–19]. The routine use of intermediate- or full-therapeutic doses of anticoagulation is not strongly supported by current guidelines [19]. In our case, the patient developed splenic infarction despite the use of intermediate-dose LMWH. Our patient had a severe case of COVID-19 and was morbidly obese. Evolving evidence from recent trials and expert opinions supports the use of either an intermediate dose or a weight-based dose of anticoagulants to prevent VTE in obese or morbidly obese patients [20–24]. We suggest that the patient's weight and the severity of COVID-19 should be considered in addition to the most recent guidelines when deciding about anticoagulant dosing. While the definition of severe COVID-19 varies from one report to another, we suggest using the presence of hypoxemic respiratory failure, acute respiratory distress syndrome, multiorgan failure, or shock as clinical indicators of severe COVID-19 [25].

4. Conclusion

COVID-19 disease can be associated with thrombosis in unusual sites including the splenic artery. Splenic artery thrombosis and splenic infarction should be considered in

patients with COVID-19 who are suffering from left-sided abdominal pain. Low- or intermediate-dose LMWH might not prevent thrombotic events in patients with severe COVID-19 and morbid obesity. Therefore, full-dose or weight-based anticoagulation should be considered in patients with severe COVID-19 and morbid obesity. Following up on most recent clinical guidelines and the results of ongoing trials is highly recommended.

Data Availability

The data supporting this case report are from previously reported studies and datasets, which have been cited. These studies are available upon request from the corresponding author at osmagha@gmail.com.

Consent

The patient signed a consent form allowing us to use his health information to publish this case report.

Conflicts of Interest

We report no conflict of interest related to this article.

Authors' Contributions

Both Dr. Osama Qasim Agha and Dr. Ryan Berryman wrote the initial draft of the manuscript. Both authors reviewed and participated in the final version of the manuscript.

Acknowledgments

We would like to thank Zulfa Alaaf for her help in finding some of the cited articles and also for participating in the language review of the manuscript.

References

- [1] “Coronavirus disease (COVID-19) Situation report—209 Situation in numbers (by WHO Region),” August 2020, https://www.who.int/docs/default-source/coronaviruse/situation-reports/20200816-covid-19-sitrep-209.pdf?sfvrsn=5dde1ca2_2.
- [2] M. O’Donnell, J. J. Shatzel, S. R. Olson et al., “Arterial thrombosis in unusual sites: a practical review,” *European Journal of Haematology*, vol. 101, no. 6, pp. 728–736, 2018.
- [3] S. Yin, M. Huang, D. Li, and N. Tang, “Difference of coagulation features between severe pneumonia induced by SARS-CoV2 and non-SARS-CoV2,” *Journal of Thrombosis and Thrombolysis*, pp. 3–6, 2020.
- [4] M. Ranucci, A. Ballotta, U. Di Dedda et al., “The procoagulant pattern of patients with COVID-19 acute respiratory distress syndrome,” *Journal of Thrombosis and Haemostasis*, vol. 18, no. 7, pp. 1747–1751, 2020.
- [5] H. Han, L. Yang, R. Liu et al., “Prominent changes in blood coagulation of patients with SARS-CoV-2 infection,” *Clinical Chemistry and Laboratory Medicine (CCLM)*, vol. 58, no. 7, pp. 1116–1120, 2020.
- [6] M. Panigada, N. Bottino, P. Tagliabue et al., “Hypercoagulability of COVID-19 patients in intensive care unit. A report of thromboelastography findings and other parameters of hemostasis,” *Journal of Thrombosis and Haemostasis*, vol. 18, no. 7, pp. 1738–1742, 2020.
- [7] L. Bowles, S. Platten, N. Yartey et al., “Lupus anticoagulant and abnormal coagulation tests in patients with Covid-19,” *New England Journal of Medicine*, vol. 383, no. 3, pp. 288–290, 2020.
- [8] N. Tang, D. Li, X. Wang, and Z. Sun, “Abnormal coagulation parameters are associated with poor prognosis in patients with novel coronavirus pneumonia,” *Journal of Thrombosis and Haemostasis*, vol. 18, no. 4, pp. 844–847, 2020.
- [9] J. Helms, CRICS TRIGGERSEP Group (Clinical Research in Intensive Care and Sepsis Trial Group for Global Evaluation and Research in Sepsis), C. Tacquard et al., “High risk of thrombosis in patients with severe SARS-CoV-2 infection: a multicenter prospective cohort study,” *Intensive Care Medicine*, vol. 46, no. 6, pp. 1089–1098, 2020.
- [10] F. A. Klok, M. J. H. A. Kruip, N. J. M. van der Meer et al., “Incidence of thrombotic complications in critically ill ICU patients with COVID-19,” *Thrombosis Research*, vol. 191, pp. 145–147, 2020.
- [11] T. J. Oxley, J. Mocco, S. Majidi et al., “Large-vessel stroke as a presenting feature of Covid-19 in the young,” *New England Journal of Medicine*, vol. 382, no. 20, p. e60, 2020.
- [12] P. Perini, B. Nabulsi, C. B. Massoni, M. Azzarone, and A. Freyrie, “Acute limb ischaemia in two young, non-atherosclerotic patients with COVID-19,” *The Lancet*, vol. 395, no. 10236, p. 1546, 2020.
- [13] R. Bellosta, L. Luzzani, G. Natalini et al., “Acute limb ischemia in patients with COVID-19 pneumonia,” *Journal of Vascular Surgery*, 2020.
- [14] M. S. L. Pessoa, C. F. C. Lima, A. C. F. Pimentel, J. C. G. Costa Júnior, and J. L. B. Holanda, “Multisystemic infarctions in COVID-19: focus on the spleen,” *European Journal of Case Reports in Internal Medicine*, vol. 7, 2020.
- [15] G. Besutti, R. Bonacini, V. Iotti et al., “Abdominal visceral infarction in 3 patients with COVID-19,” *Emerging Infectious Diseases*, vol. 26, no. 8, pp. 1926–1928, 2020.
- [16] N. Tang, H. Bai, X. Chen, J. Gong, D. Li, and Z. Sun, “Anticoagulant treatment is associated with decreased mortality in severe coronavirus disease 2019 patients with coagulopathy,” *Journal of Thrombosis and Haemostasis*, vol. 18, no. 5, pp. 1094–1099, 2020.
- [17] “Feature | thrombosis and COVID-19: FAQs for current practice - American College of Cardiology,” April 2020, <https://www.acc.org/latest-in-cardiology/articles/2020/04/17/14/42/thrombosis-and-coronavirus-disease-2019-covid-19-faqs-for-current-practice>.
- [18] L. B. Kreuziger, A. Lee, D. Garcia, A. Cuker, and M. C. JMC, “COVID-19 and VTE-anticoagulation - Hematology.org,” 2020, April 2020, <https://www.hematology.org/covid-19/covid-19-and-vte-anticoagulation>.
- [19] L. K. Moores, T. Tritschler, S. Brosnahan et al., “Prevention, Diagnosis, and treatment of VTE in patients with Coronavirus Disease 2019,” *Chest*, 2020.
- [20] R. Ihaddadene and M. Carrier, “The use of anticoagulants for the treatment and prevention of venous thromboembolism in obese patients: implications for safety,” *Expert Opinion on Drug Safety*, vol. 15, no. 1, pp. 65–74, 2015.
- [21] L. Venclauskas, A. Maleckas, and J. I. Arcelus, “European guidelines on perioperative venous thromboembolism prophylaxis,” *European Journal of Anaesthesiology*, vol. 35, no. 2, pp. 147–153, 2018.
- [22] T. F. Wang, P. E. Milligan, C. A. Wong, E. N. Deal, M. S. Thielke, and B. F. Gage, “Efficacy and safety of high-dose thromboprophylaxis in morbidly obese inpatients,” *Thrombosis and Haemostasis*, vol. 111, no. 1, pp. 88–93, 2017.
- [23] B. Brenner, R. Arya, J. Beyer-Westendorf et al., “Evaluation of unmet clinical needs in prophylaxis and treatment of venous thromboembolism in at-risk patient groups: pregnancy, elderly and obese patients,” *Thrombosis Journal*, vol. 17, no. 1, 2019.
- [24] J. Sebaaly and K. Covert, “Enoxaparin dosing at extremes of weight: literature review and dosing recommendations,” *The Annals of Pharmacotherapy*, vol. 52, no. 9, pp. 898–909, 2018.
- [25] D. A. Berlin, R. M. Gulick, and F. J. Martinez, “Severe Covid-19,” *New England Journal of Medicine*, 2020.