

Case Report

Isolated Langerhans Cell Histiocytosis of the Vulva in a 28-Year-Old Lady: A Report of a Case and Brief Review of the Literature

Maryam Sadat Sadati ^{1,2}, Nafiseh Todarbary ³, Fatemeh Sari Aslani ^{1,4},
and Maryam Hadibarhaghtalab ^{1,2}

¹Molecular Dermatology Research Center, Shiraz University of Medical Sciences, Shiraz, Iran

²Dermatology Department, Shiraz University of Medical Sciences, Shiraz, Iran

³Student Research Committee, Shiraz University of Medical Sciences, Shiraz, Iran

⁴Pathology Department, Shiraz University of Medical Sciences, Shiraz, Iran

Correspondence should be addressed to Maryam Hadibarhaghtalab; maryam_hadibarhaghtalab@yahoo.com

Received 10 November 2021; Revised 14 March 2022; Accepted 12 June 2022; Published 28 June 2022

Academic Editor: Alireza Firooz

Copyright © 2022 Maryam Sadat Sadati et al. This is an open access article distributed under the Creative Commons Attribution License, which permits unrestricted use, distribution, and reproduction in any medium, provided the original work is properly cited.

Langerhans cell histiocytosis (LCH) is a rare, proliferative disorder of Langerhans' cells. The presentation can vary from single organ involvement to multisystem and disseminated in severe cases, affecting children more than adults. Isolated vulvar involvement of LCH in a 28-year-old woman has rarely been described and also there are limited data for diagnosis and treatment. Herein, we report the case of a 28-year-old woman with isolated vulvar LCH, misdiagnosed with herpes simplex infection, successfully treated with thalidomide.

1. Introduction

According to the latest version of the National Comprehensive Cancer Network (NCCN), LCH is categorized to unifocal and multisystem (multifocal single-system or unifocal LCH involving critical organs). Unifocal LCH consists of isolated bone involvement, isolated skin disease, and involvement of other systems, except for critical organs. Multisystem LCH includes asymptomatic with no impending organ dysfunction, symptomatic or impending organ dysfunction, and pulmonary LCH [1].

In medical pieces of literature, only a few cases have been previously reported with vulvar LCH [2]. Primary isolated LCH of the female genital tract is rare, and less than 40 cases have already been reported worldwide [3]. This report presents the clinical and histopathologic features, diagnostic workup, and treatment of a 28-year-old woman as a vulvar LCH case from the Dermatology Department of Faghihi Hospital in Shiraz, Iran.

2. Case Presentation

The patient was a 28-year-old lady admitted to the Dermatology Department of Faghihi Hospital with a chief complaint of small punched-out ulcers located in the genitalia area concomitant with pruritus and posturination dysuria since two years before. Her physical examination was normal except for mild pinkish erosions and two punched-out ulcers in the genital area (Figure 1).

Firstly, the clinical diagnosis was genital herpes simplex and the patient had received several courses of acyclovir and cryotherapy, but she was not cured. Lesion biopsy and immunohistochemistry were done after no improvement in the clinical practice.

Pathology results showed that the collected biopsy was 0.3 × 0.3 × 0.3 cm creamy-gray color skin favoring erosive lichen planus (LP) and lichen simplex atrophicus (LSA). Pathological findings were parakeratosis with some neutrophils and moderate acanthosis with multifocal aggregates

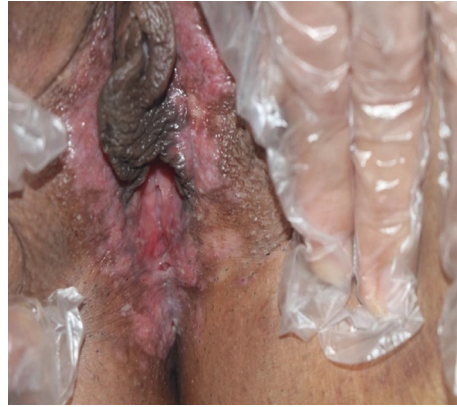

FIGURE 1: Pinkish mild erosions and small punched-out ulcers in genital area.

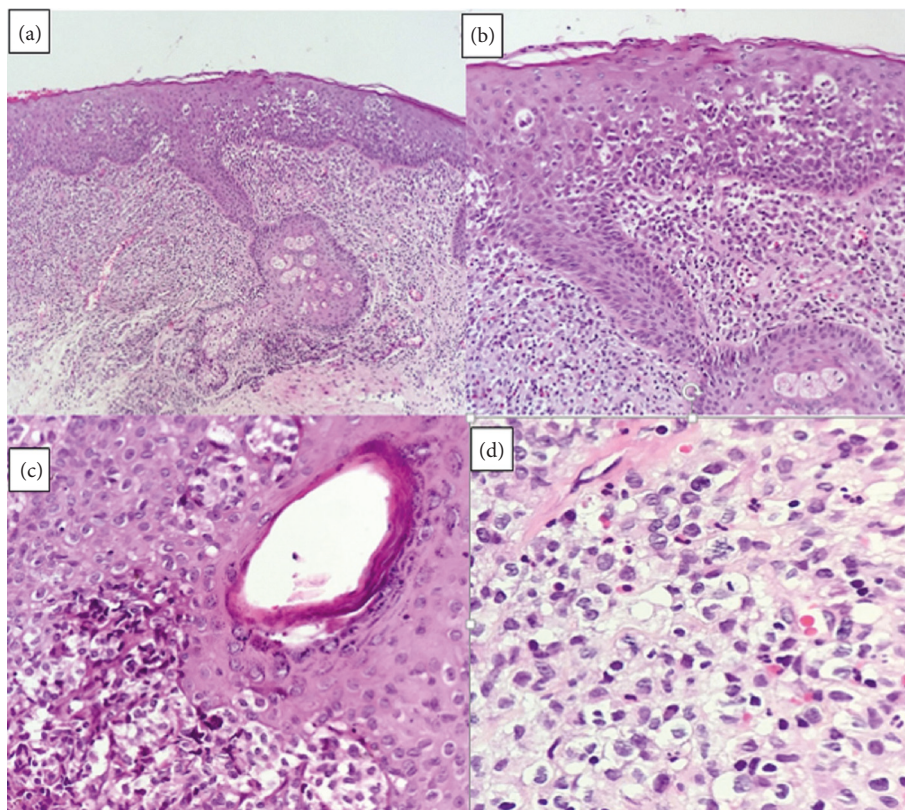


FIGURE 2: (a). There are some aggregates of Langerhans cells in the epidermal layer and diffuse upper and mid-dermal predominantly Langerhans cell infiltration (H&E $\times 100$) (b). There are some aggregates of Langerhans cells in the epidermal layer and diffuse dermal predominantly Langerhans cell infiltration admixed with some eosinophils and few lymphocytes (H&E $\times 200$) (c). Follicular epithelium involved by Langerhans cells (H&E $\times 400$) (d). There is diffuse upper dermal predominantly Langerhans cell infiltration with mitotic figures admixed with some eosinophils and neutrophils and a few lymphocytes (H&E $\times 400$).

of Langerhans cells. The upper and mid-dermis showed sheets of uniform ovoid cells with eosinophilic cytoplasm with a coffee bean or reniform nuclei and eosinophil and lymphocyte infiltration. The follicular epithelium was involved by some aggregates of Langerhans cells (Figure 2).

Based on oncology consultation, brain MRI, PET scan, bone marrow biopsy, skull, and chest X-ray were performed, all of which were normal.

Immunohistochemistry profile on formalin-fixed and paraffin-embedded lesion of genitalia biopsy was CD1a

positive, CD68 positive, and S100 positive, and the Langerin marker (CD207) was not available. Finally, the probable diagnosis was LCH (Figure 3).

Treatment was started with the administration of nitrogen mustard and fluocinolone, but she was not cured. Then, thalidomide, 100 milligrams once a day, was prescribed. The patient did not have a pregnancy plan by taking OCP pills and using condoms. Adverse effects and prohibition of pregnancy were explained to her in detail. Finally, the patient's lesions disappeared after one year (Figure 4).

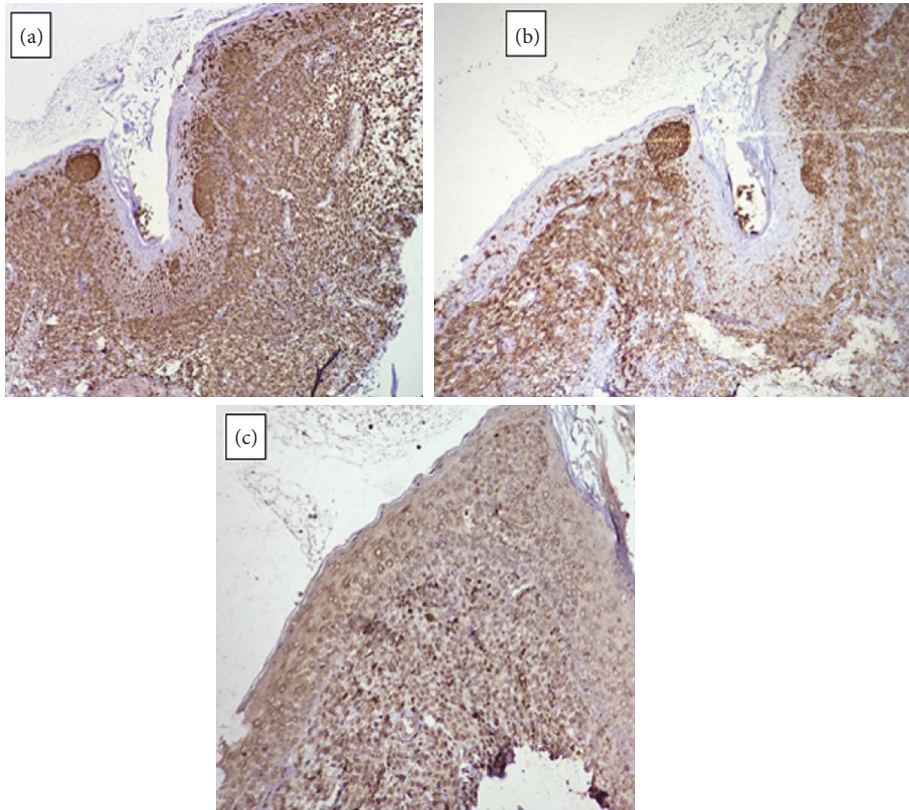


FIGURE 3: (a). S100 immunostaining shows strong diffuse positivity in upper dermis and scattered single as well as aggregates of Langerhans cells in the *epidermis* ($\times 100$) (b). CD1a immunostaining of Langerhans cells shows strong diffuse positivity in the upper dermis and scattered single as well as aggregates in the *epidermis* ($\times 100$) (c). CD68 immunostaining shows scattered weak positivity upper dermis ($\times 100$).

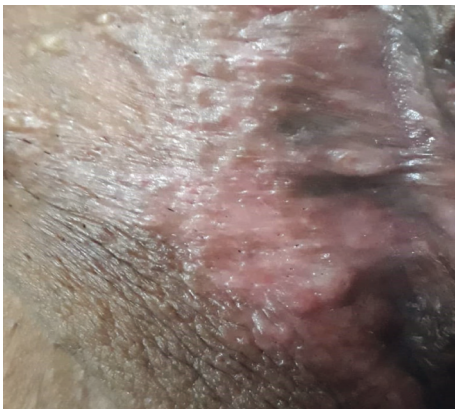

FIGURE 4: Remission after treatment by thalidomide.

The patient was visited every three months for physical examination and checking lab data such as complete blood tests, pregnancy tests, and kidney and liver function tests until the end of treatment; then, she was visited annually.

3. Discussion

LCH is a rare disease, especially among adults, and it can occur at any age [4]. The most common sites of involvement consist of skin, bones, lymph nodes, bone marrow, hypothalamic-pituitary axis, lungs, spleen, liver, bowel, and orbit.

In addition, LCH can involve different sites of the female genital tract, including the vulva, vagina, cervix, uterus, and ovaries [5].

In the case of LCH, workups such as full blood count and chemistry, thyroid function tests, urine analysis, and coagulation studies are usually requested. Additionally, radiographic examinations such as skull series and chest radiography should be done depending on the basic diagnostic tests and the patient's symptoms [6].

In 1939, Lane and Smith reported the first case of lower female genital tract LCH in a six-year-old child [5]. Herein, we reported a case of adult vulvar LCH with a mimic of herpes simplex lesions which can easily be misdiagnosed; therefore, having this clinical presentation with no response to routine treatment and no risk factor of LCH cannot put LCH off your mind.

Several neoplastic diseases can be mistaken for LCH, such as malignant melanoma, squamous cell carcinoma, sarcoma, and 'Paget's disease of the vulva. Systemic diseases in any patient suspected of vulvar LCH should be evaluated [5].

Although this condition is rare, taking a detailed and accurate medical history, accurate physical examination, and necessary workups like tissue biopsy are strongly recommended to prevent misdiagnosis of the disease and delay in beginning the proper treatment.

Vulvar involvement of LCH can be treated by topical and oral steroids, chemotherapy (vinblastine, vincristine, or 2-

chlorodeoxyadenosine), immune modulators (methotrexate or tacrolimus), radiation, partial or radical vulvectomy with or without lymph node resection, thalidomide, and radiation therapy [7].

Considerably, treatment of isolated vulvar LCH necessitates more investigation, and there is a lack of evidence for standard therapy in patients with pure genital involvement. Santillan et al. reported the first successful administration of thalidomide for genital LCH treatment [5]; it is a successful treatment for localized LCH such as genital, perianal, and disseminated skin lesions [8–10].

The exact mechanism of thalidomide in treating isolated vulvar LCH is not completely recognized. However, recent studies demonstrated anti-inflammatory and antineoplastic features by inhibiting the production of IL-6 and TNF-alpha. These cytokines had expressed extensively within the biopsy of LCH lesions; therefore, they may play a vital role in the tumor cells' relapse, viability, and irregular maturation. In addition, the beneficial effect of thalidomide is possibly due to balancing the expression of pathological cytokines in LCH [11].

Thalidomide is a safe and well-tolerated drug for isolated genital LCH that can cure mucocutaneous LCH and prevent relapse. In our case, our patient's administration of thalidomide, 100 milligrams daily, was effective, easy to administer, and well-tolerated, and lesions were cured.

However, thalidomide is beneficial in vulvar LCH. Due to teratogenic side effects, the patient must have close follow-ups [9]. It could also have a poor response in high-risk multisystem diseases. Generally, thalidomide, 100 mg per day, is used in adults, but monitoring for toxicity with peripheral neuropathy is necessary [12].

Data Availability

Data are available on request by contacting the corresponding author: maryam_hadibarhaghtalab@yahoo.com.

Conflicts of Interest

The authors declare that there are no conflicts of interest regarding the publication of this article.

References

- [1] National Comprehensive Cancer Network (NCCN), "NCCN clinical practice guidelines in oncology," 2021, https://www.nccn.org/professionals/physician_gls/pdf/histiocytic_neoplasms.pdf.
- [2] H. Mottl, L. Rob, J. Stary, R. Kodet, and E. Drahokoupilova, "Langerhans cell histiocytosis of vulva in adolescent," *International Journal of Gynecological Cancer*, vol. 17, no. 2, pp. 520–524, 2007.
- [3] N. I. Gwacham, D. Ward, and N. D. McKenzie, "Isolated vulvar langerhans cell histiocytosis," *Gynecologic Oncology Reports*, vol. 36, Article ID 100785, 2021.
- [4] I. Gurung, Y. Gao, K. Han, and X.-B. Peng, "Adult onset langerhans cell histiocytosis limited to the skin," *Indian Journal of Dermatology*, vol. 64, no. 5, p. 414, 2019.
- [5] A. Santillan, A. J. Montero, J. J. Kavanagh, J. Liu, and P. T. Ramirez, "Vulvar langerhans cell histiocytosis: a case report and review of the literature," *Gynecologic Oncology*, vol. 91, no. 1, pp. 241–246, 2003.
- [6] R. Subramanian, R. Ramachandran, G. Rajangam, and N. Donaparthy, "Purely cutaneous langerhans cell histiocytosis presenting as an ulcer on the chin in an elderly man successfully treated with thalidomide," *Indian Dermatology Online Journal*, vol. 6, no. 6, p. 407, 2015.
- [7] R. Wieland, J. Flanagan, E. Everett, and S. Mount, "Langerhans cell histiocytosis limited to the female genital tract: a review of literature with three additional cases," *Gynecologic Oncology Reports*, vol. 22, pp. 4–8, 2017.
- [8] M. Shahidi-Dadras, M. Saeedi, S. Shakoei, and A. Ayatollahi, "Langerhans cell histiocytosis: an uncommon presentation, successfully treated by thalidomide," *Indian Journal of Dermatology Venereology and Leprology*, vol. 77, no. 5, p. 587, 2011.
- [9] K. L. McClain and C. A. Kozinetz, "A phase II trial using thalidomide for langerhans cell histiocytosis," *Pediatric Blood and Cancer*, vol. 48, no. 1, pp. 44–49, 2007.
- [10] S. Saniee, N. Afshari, and S. Kashefi, "Pulmonary langerhans cell histiocytosis with skin involvement; an amazing case report," *Journal of Analytical Research in Clinical Medicine*, vol. 7, no. 1, pp. 32–36, 2019.
- [11] C. S. Sander, M. Kaatz, and P. Elsner, "Successful treatment of cutaneous langerhans cell histiocytosis with thalidomide," *Dermatology*, vol. 208, no. 2, pp. 149–152, 2004.
- [12] M. Girschikofsky, M. Arico, D. Castillo et al., "Management of adult patients with langerhans cell histiocytosis: recommendations from an expert panel on behalf of Euro-histio-net," *Orphanet Journal of Rare Diseases*, vol. 8, no. 1, p. 72, 2013.