

Image 1.

Image 1: Bone marrow aspirate showing lymphocytes with abundant cytoplasm.

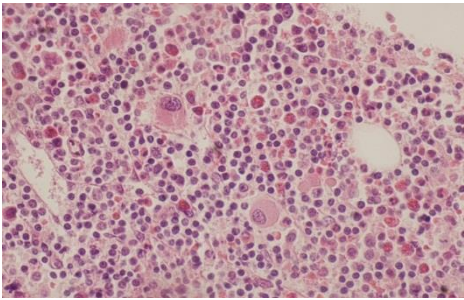


Image 2.

Image 2: Bone marrow biopsy showing a hypercellular marrow primarily occupied by the extensive lymphoid infiltrate composed mostly of small mature lymphocytes.