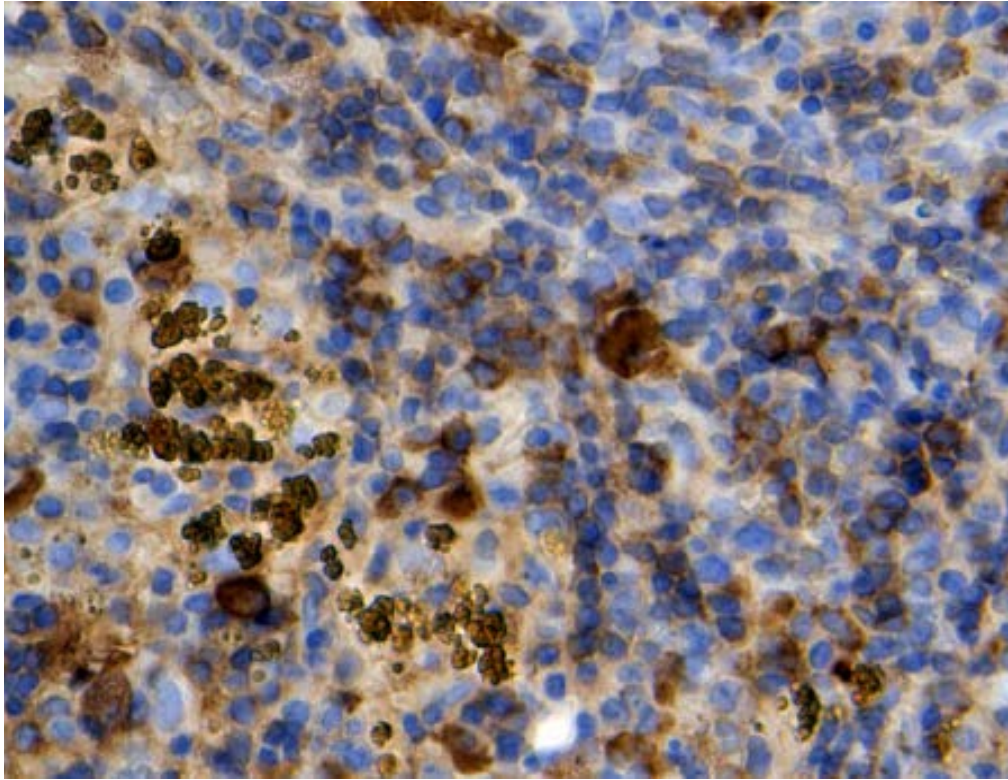
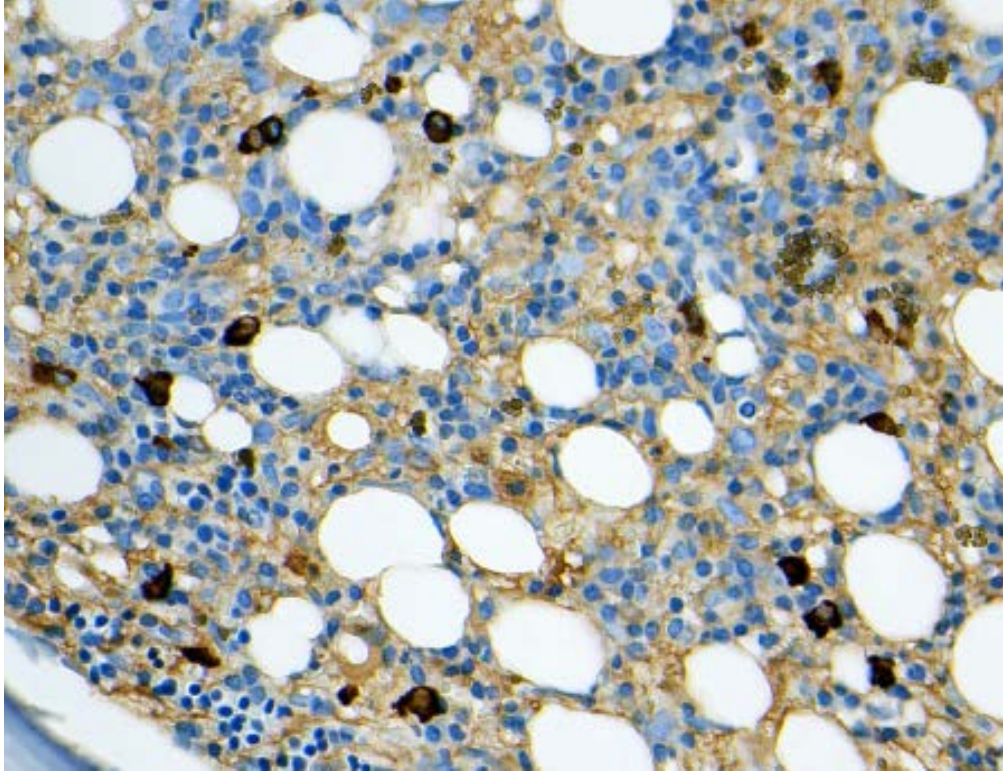


SUPPLEMENTARY MATERIAL

Case 2: Bone Marrow



kappa stain - hint of expression on lymphocytes, a few plasma cells strongly positive



lambda stain – some plasma cells strongly positive but lymphocytes appear negative