





Case Report

Spontaneous Regression of Plasmablastic Lymphoma in an Immunocompetent Patient: Case Report and Review of the Literature

Kee Tat Lee ¹, Nurul Akmar Misron ², Norasmidar Abdul Aziz ¹, Chin Hau Wong,¹ and Hong Keng Liew ¹

¹Department of Medicine, Hospital Sultanah Bahiyah, Langgar, Kedah, Malaysia

²Department of Pathology, Hospital Sultanah Bahiyah, Langgar, Kedah, Malaysia

Correspondence should be addressed to Kee Tat Lee; keetat.lee@gmail.com

Received 2 January 2022; Accepted 12 May 2022; Published 30 May 2022

Academic Editor: Pier Paolo Piccaluga

Copyright © 2022 Kee Tat Lee et al. This is an open access article distributed under the Creative Commons Attribution License, which permits unrestricted use, distribution, and reproduction in any medium, provided the original work is properly cited.

Plasmablastic lymphoma (PBL) is a rare and highly aggressive type of lymphoma, which is commonly associated with human immunodeficiency virus (HIV) infection. Spontaneous regression of aggressive lymphomas is rare as they typically require administration of chemotherapy and radiotherapy for treatment. Here, we describe a case of a spontaneous regression of PBL after nasal biopsy and computed tomography (CT) guided biopsy of paravertebral mass in an immunocompetent patient. We postulate that the patient's immune system may be activated as a result of the stress and physical trauma brought on by nasal and paravertebral mass biopsy. Our case highlights the rare phenomenon of spontaneous regression of lymphoma which needs to be further studied on to establish its underlying pathophysiology.

1. Introduction

Plasmablastic lymphoma is a rare and aggressive B cell lymphoproliferative disorder. Delecluse et al. first described this rare disease in the oral cavity of patients with HIV in 1997 [1]. Since the original report, PBL has been more widely recognized and has been incorporated as a new entity in the latest World Health Organization (WHO) classification of lymphoma [2].

However, the diagnosis of PBL remains a diagnostic challenge due to its overlapping features between lymphoma and myeloma. PBL is a high-grade B cell lymphoma that expresses plasma cell markers (CD38, CD138, CD79a, and MUM-1), but typically tests negative for B cell markers (CD19, CD20, and PAX-5). The Ki-67 proliferation index of these tumours is usually high [3].

Despite the advancement in the therapy of aggressive lymphoma, the prognosis of patients with PBL remains dismal with short overall survival. Due to its rarity, it is difficult to establish a standard of care for this disease.

Several case reports and case studies show that spontaneous regression can sometimes occur in low-grade lymphomas, but rarely in cases of aggressive lymphomas. Here, we report a case of a 61-year-old gentleman with PBL that spontaneously regressed after CT-guided biopsy of paravertebral mass. Relevant literature is reviewed.

2. Case Report

A 61-year-old gentleman with no significant medical history presented with the three weeks history of intermittent epistaxis, nasal block, and loss of weight. Physical examination was unremarkable, and he did not have lymphadenopathy or hepatosplenomegaly. Rigid nasal endoscopy revealed a smooth surface mass covering the entire left nasal cavity, pushing the nasal septum to the right and bleeds easily on contact. Subsequently, a CT scan of the paranasal sinus, neck, and thorax revealed a mass over left frontal and ethmoid sinuses which occupied almost the entire left nasal

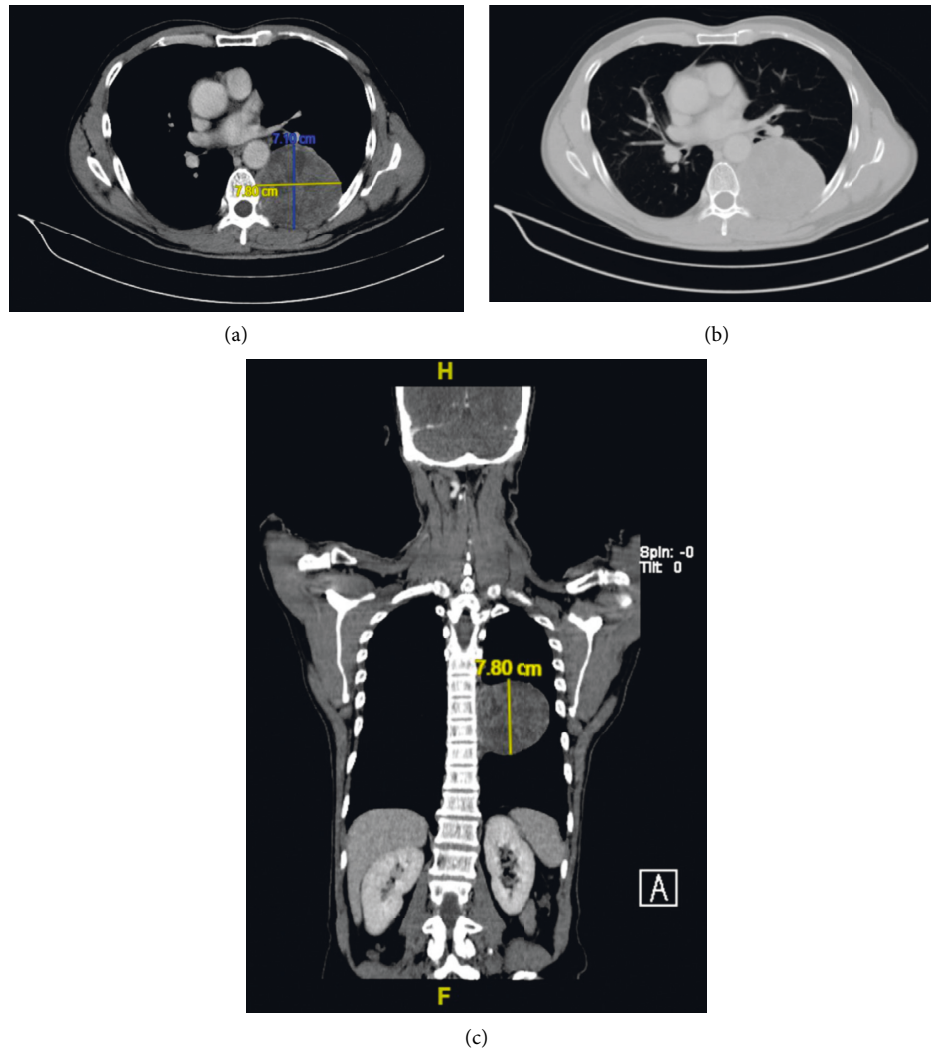


FIGURE 1: CT showing a well-defined heterogeneously enhancing mass at the left paravertebral region with extension into left T7/8 neural foramina. (a)-(b) Axial view; (c) coronal view.

cavity. Incidentally, there was a well-defined heterogeneously enhancing mass at the left paravertebral region (7.1 × 7.8 × 7.8 cm) with extension into left T7/8 neural foramina (Figure 1). Initial laboratory investigation showed white blood cell (WBC) count of $14.2 \times 10^3/\mu\text{L}$, hemoglobin (Hb) of 13.8 g/dL, and platelet count of $377 \times 10^3/\mu\text{L}$, with normal renal and hepatic function. His lactate dehydrogenase (LDH) was 141 U/L (upper limit of normal: 246). Hepatitis B, hepatitis C, and HIV serologies were non-reactive. Nasopharyngeal mass biopsy was performed, and histological examination highlighted diffuse infiltration by the atypical medium to large lymphoid cells and exhibited multiple membrane bound nucleoli. Immunohistochemistry (IHC) showed that the neoplastic cells were diffusely positive for CD79a, MUM-1, and CD56 and focally positive for PAX-5 (Figure 2). These cells were negative for CD20, CD30, ALK-1, CD3, CD5, CD10, Bcl-2, Bcl-6, CD138, HMB45, and S-100. Nuclear proliferation as assessed by Ki-67 was almost 100%. Unfortunately, Epstein-Barr virus (EBV) encoded RNA by IHC was not performed. Based on the

morphological and IHC characteristics, diagnosis of PBL was made. Bone marrow biopsy did not show any marrow infiltration. CT-guided biopsy of the paravertebral mass was done to rule out possible neurogenic tumour as PBL has rarely been associated with a paravertebral mass. However, the results were inconclusive due to the inadequate sample. He was scheduled for a repeated CT-guided biopsy of the paravertebral mass, and his histopathological examination results came back later which revealed ancient schwannoma. Surprisingly, he reported resolution of his symptoms after the first biopsy of the paravertebral mass, and hence, treatment for PBL was not initiated. Spontaneous regression of his PBL was further confirmed by a repeat rigid nasal endoscopy, which showed good patency of both nasal cavities, and a repeat CT scan of the paranasal sinuses, which revealed spontaneous regression of his left nasal mass (Figure 3). A watch-and-wait approach was employed, and he was followed up closely to look for any evidence of recurrence. He remained in remission during his last follow up after 4 years from diagnosis.

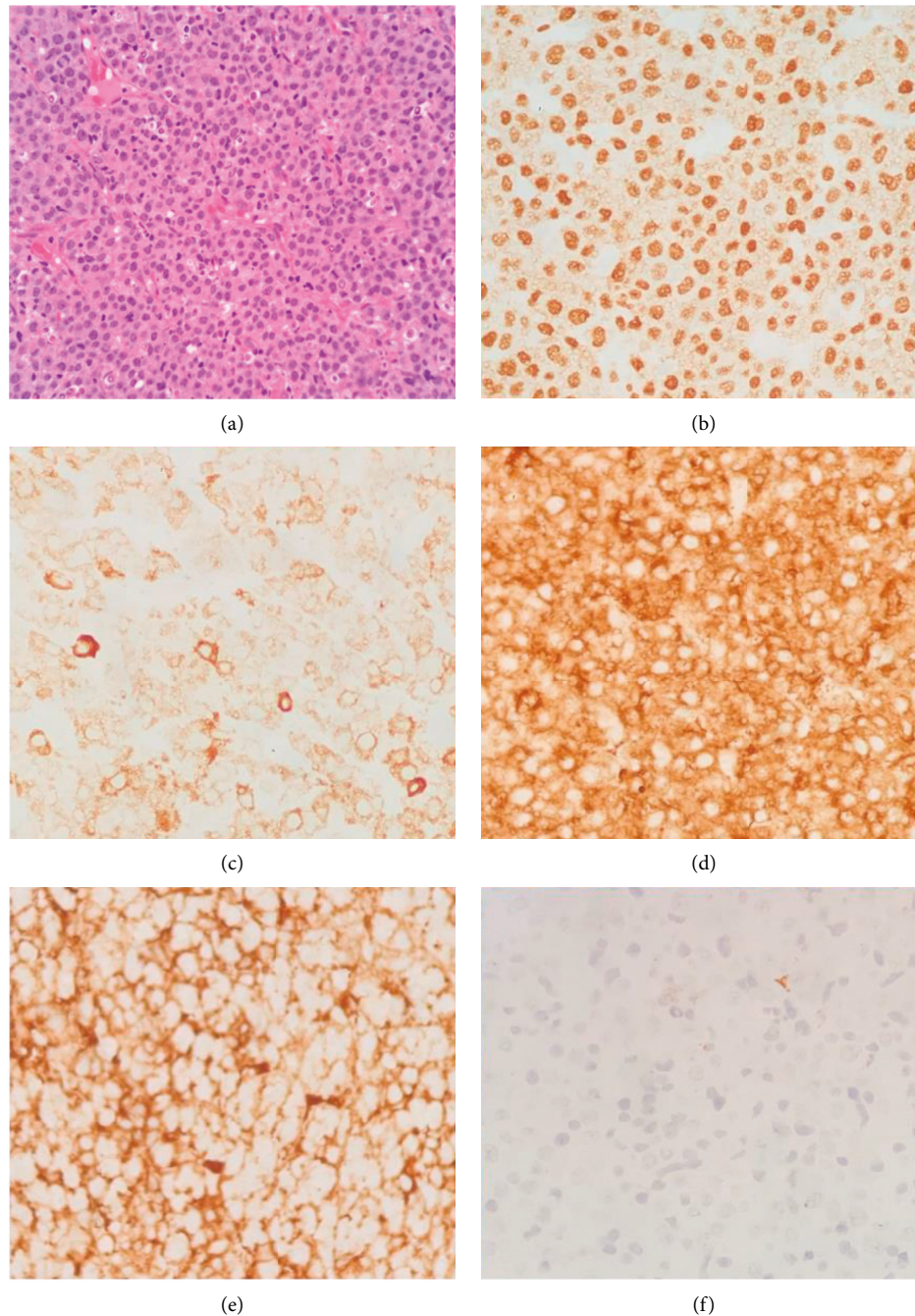


FIGURE 2: Nasopharyngeal mass biopsy. Hematoxylin and eosin staining ((a) original magnification $\times 40$) and immunohistochemical staining were positive for MUM-1 ((b) original magnification $\times 40$), CD79a ((c) original magnification $\times 40$), kappa ((d) original magnification $\times 40$), and lambda ((e) original magnification $\times 40$) and negative for CD20 ((f) original magnification $\times 40$).

3. Discussion

PBL is an aggressive lymphoma which is strongly associated with immunosuppression. In the past decade, there are increasing numbers of PBL case report or series being published worldwide. Some of the reported cases include immunocompetent patients and involve extraoral sites [4–9]. PBL is found predominantly in males (75%), and median age of diagnosis is 50 years old [10]. HIV-negative PBL affects relatively older patients with median age of 71

years as compared to 46 years old in HIV-positive patients [5].

The prognosis of patients with PBL is poor with median overall survival (OS) of 8–15 months [3, 4]. There is no clear consensus on the optimal treatment of PBL. However, chemotherapy such as CHOP (cyclophosphamide, hydroxydaunorubicin, vincristine, and prednisone) or more aggressive chemotherapy regimens such as DA-EPOCH (dose-adjusted etoposide, prednisone, vincristine, cyclophosphamide, and doxorubicin), CODOX-M/IVAC

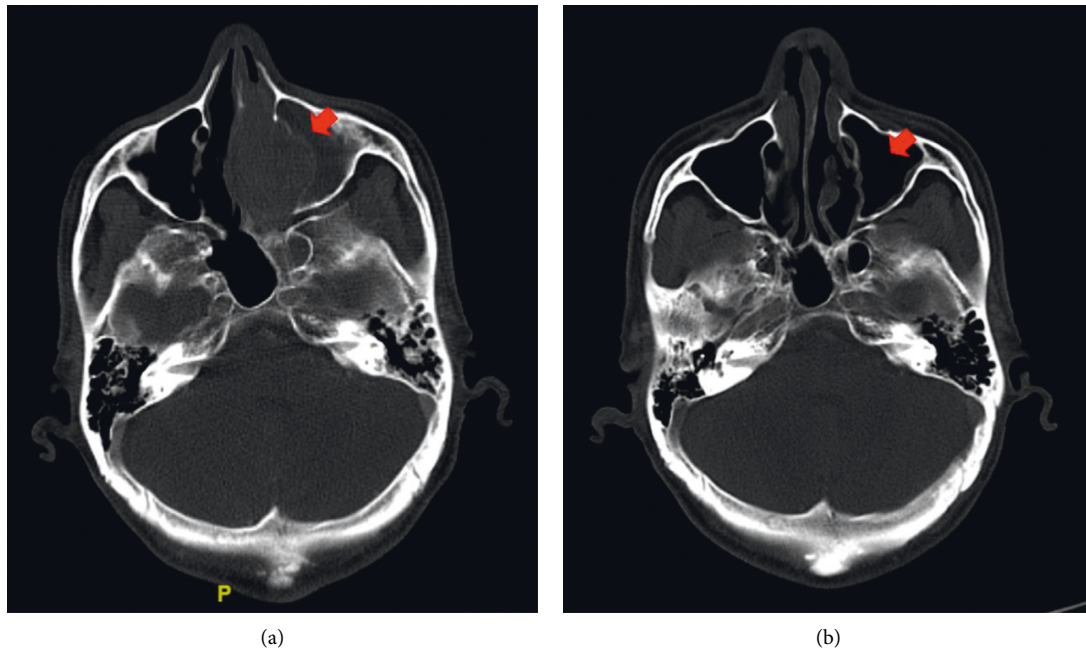


FIGURE 3: Initial CT showing a mass over left frontal and ethmoid sinuses which occupied almost the entire left nasal cavity (a). Repeated CT showing regression of left nasal mass (b).

TABLE 1: Summary of clinical characteristic of spontaneous regression of PBL cases without antineoplastic therapy.

No.	Age/sex	Immune status	B symptom	Stage ^a	Primary site	Nodal	Therapy	Follow up	Recurrence
1 [16]	35/male	Yes/HIV	No	I	Maxilla	No	HAART	1 month	No
2 [17]	55/ female	Yes/HIV	N/A	N/A	Oral cavity	N/A	HAART	10 months	No
3 [18]	78/ female	Yes/MTX treatment	N/A	II	Buccal mucosa	Yes (cervical)	Decrease dose of MTX	2 years	No
4 [19]	80/male	No	No	I	Maxilla	No	No	5 months	No
5 [20]	80/male	No	No	I	Gingiva	No	No	N/A	No
6 [21]	66/ female	Yes/HIV	No	I	Maxilla	No	HAART	12 months	No
7 [22]	69/male	Yes/MTX ^b treatment	No	IV	N/A ^c	No	Stop MTX	12 weeks	No
8 [23]	69/male	No	No	I	Gingiva	N/A	No	2 years	No
9	61/male	No	No	I	Nasal	No	No	4 years	No

^aAssessed using Ann Arbor staging. ^bMTX, methotrexate. ^cN/A, not available.

(cyclophosphamide, vincristine, doxorubicin, high-dose methotrexate/ifosfamide, etoposide, and high-dose cytarabine), or hyper-CVAD (hyperfractionated cyclophosphamide, vincristine, doxorubicin, and dexamethasone alternating with methotrexate and cytarabine) have been used with various success rates. Currently, there is no evidence of significant survival benefits with intensive chemotherapy over CHOP regimes [3, 4, 10].

Spontaneous regression of aggressive lymphoma is very uncommon and has rarely been reported in literature. Here, we report a case of sinonasal PBL that spontaneously regressed without chemotherapy. The exact mechanism of spontaneous regression remains unknown, but several hypotheses have been proposed previously. Immune stimulation secondary to active infection is one of the proposed mechanisms that can lead to tumour regression.

This was first described by Dr. William Coley 100 years ago, where he reported spontaneous regression of inoperable sarcoma after being infected with *Streptococcus pyogenes* erysipelas [11]. Other proposed hypotheses include the augmented host immune response via humoral and cellular effector mechanisms, which can lead to tumour regression [12].

In this case, our patient reported resolution of his symptoms after biopsy of the paravertebral mass. We postulate that the patient's immune system may be activated as a result of the stress and physical trauma brought on by nasal and paravertebral mass biopsy. This was consistent with findings of several case reports where aggressive lymphomas undergo spontaneous remission after tumour biopsy, suggesting that biopsy might stimulate an antitumour immunity [13–15].

In addition to our present case, we identified and reviewed another eight similar cases of PBL with spontaneous regression (Table 1) [16–23]. The median age of the study cohort was 69 years old (range 35–80). Most of the patients were in Ann Arbor stage I (89%), and only one of them had nodal involvement. Three of them were HIV positive, and PBL regressed after highly active antiretroviral therapy (HAART), which may be related to immune restoration secondary to HAART. In particular, three of the previously reported cases (cases 4, 5, and 8) of PBL were similar to our case, all of them were above 60 years old without significant medical illness, and PBL regressed without chemotherapy or specific treatment.

4. Conclusion

Our case highlights the rare phenomenon of spontaneous regression of PBL in an elderly patient. The exact mechanism of this phenomenon remains unknown. However, we postulate that this could be triggered by activation of his immune system after nasal and paravertebral biopsy. Further research is needed to help better understand the pathophysiology behind this phenomenon as this could potentially have major therapeutic implications.

Consent

Written consent has been obtained from patient.

Conflicts of Interest

The authors declare that they have no conflicts of interest.

Acknowledgments

The authors thank the Director General of Health Malaysia for the permission to present these findings.

References

- [1] H. J. Delecluse, I. Anagnostopoulos, F. Dallenbach et al., "Plasmablastic lymphomas of the oral cavity: a new entity associated with the human immunodeficiency virus infection," *Blood*, vol. 89, no. 4, pp. 1413–1420, 1997.
- [2] S. H. Swerdlow, E. Campo, S. A. Pileri et al., "The 2016 revision of the world health organization classification of lymphoid neoplasms," *Blood*, vol. 127, no. 20, pp. 2375–2390, 2016.
- [3] J. J. Castillo, M. Bibas, and R. N. Miranda, "The biology and treatment of plasmablastic lymphoma," *Blood*, vol. 125, no. 15, pp. 2323–2330, 2015.
- [4] J. Morscio, D. Dierickx, J. Nijs et al., "Clinicopathologic comparison of plasmablastic lymphoma in HIV-positive, immunocompetent, and posttransplant patients: single-center series of 25 cases and meta-analysis of 277 reported cases," *American Journal of Surgical Pathology*, vol. 38, no. 7, pp. 875–886, 2014.
- [5] E. Tchernonog, P. Faurie, P. Coppo et al., "Clinical characteristics and prognostic factors of plasmablastic lymphoma patients: analysis of 135 patients from the LYSA group," *Annals of Oncology*, vol. 28, no. 4, pp. 843–848, 2017.
- [6] Y. J. Li, J. W. Li, K. L. Chen et al., "HIV-negative plasmablastic lymphoma: report of 8 cases and a comprehensive review of 394 published cases," *Blood Research*, vol. 55, no. 1, pp. 49–56, 2020.
- [7] H. W. Wang, W. Yang, J. Z. Sun, J. Y. Lu, M. Li, and L. Sun, "Plasmablastic lymphoma of the small intestine: case report and literature review," *World Journal of Gastroenterology*, vol. 18, no. 45, pp. 6677–6681, 2012.
- [8] F. Tavora, L. F. Gonzalez-Cuyar, C. C. J. Sun, A. Burke, and X. F. Zhao, "Extra-oral plasmablastic lymphoma: report of a case and review of literature," *Human Pathology*, vol. 37, no. 9, pp. 1233–1236, 2006.
- [9] A. Matikas, G. Kanellis, C. Papadimitriou et al., "Plasmablastic lymphoma of the breast in an immunocompetent patient: long-lasting complete response induced by chemotherapy and autologous stem cell transplantation," *Anticancer Research*, vol. 34, no. 9, pp. 5111–5115, 2014.
- [10] J. J. Castillo, E. S. Winer, D. Stachurski et al., "Clinical and pathological differences between human immunodeficiency virus-positive and human immunodeficiency virus-negative patients with plasmablastic lymphoma," *Leukemia and Lymphoma*, vol. 51, no. 11, pp. 2047–2053, 2010.
- [11] S. A. Hopton Cann, J. P. van Netten, and C. van Netten, "Dr William Coley and tumour regression: a place in history or in the future," *Postgraduate Medical Journal*, vol. 79, no. 938, pp. 672–680, 2003.
- [12] W. R. Drobyski and R. Qazi, "Spontaneous regression in non-hodgkin's lymphoma: clinical and pathogenetic considerations," *American Journal of Hematology*, vol. 31, no. 2, pp. 138–141, 1989.
- [13] M. Kumamoto, H. Nakamine, T. Hara et al., "Spontaneous complete regression of high grade non-hodgkin's lymphoma. Morphologic, immunohistochemical, and gene amplification analyses," *Cancer*, vol. 74, no. 11, pp. 3023–3028, 1994.
- [14] M. Koga, J. Kusukawa, and N. Hayabuchi, "Spontaneous regression of extranodal malignant lymphoma occurred in the gingiva," *Oral Oncology*, vol. 39, no. 3, pp. 323–324, 2003.
- [15] R. Abe, K. Ogawa, Y. Maruyama, N. Nakamura, and M. Abe, "Spontaneous regression of diffuse large B-cell lymphoma harbouring epstein-barr virus: a case report and review of the literature," *Journal of Clinical and Experimental Hematopathology*, vol. 47, no. 1, pp. 23–26, 2007.
- [16] R. Armstrong, J. Bradrick, and Y. C. Liu, "Spontaneous regression of an HIV-associated plasmablastic lymphoma in the oral cavity: a case report," *Journal of Oral and Maxillofacial Surgery*, vol. 65, no. 7, pp. 1361–1364, 2007.
- [17] M. Corti, L. De Carolis, A. Campitelli, M. Narbaitz, and P. Baré, "Response of human immunodeficiency virus-associated oral plasmablastic lymphoma to highly active antiretroviral therapy without chemotherapy," *Infectious Diseases in Clinical Practice*, vol. 20, no. 1, pp. 79–81, 2012.
- [18] A. García-Noblejas, A. Velasco, J. Cannata-Ortiz, and R. Arranz, "Spontaneous regression of immunodeficiency associated plasmablastic lymphoma related to methotrexate after decrease of dosage," *Medical Clinics of North America*, vol. 140, no. 12, pp. 569–570, 2013.
- [19] T. Igawa, Y. Sato, H. Kawai et al., "Spontaneous regression of plasmablastic lymphoma in an elderly human immunodeficiency virus (HIV)-negative patient," *Diagnostic Pathology*, vol. 10, no. 1, p. 183, 2015.
- [20] M. Yao, N. Yoshioka, K. Hasegawa, T. Shimo, and A. Sasaki, "A case of spontaneous regression of plasmablastic lymphoma in the upper gingiva," *International Journal of Oral and Maxillofacial Surgery*, vol. 46, no. 1, p. 315, 2017.
- [21] N. B. Daroit, V. Silva, B. J. Maraschin et al., "Spontaneous regression of an oral manifestation of plasmablastic

lymphoma: literature review and commentary about the phenomena,” *British Journal of Medicine and Medical Research*, vol. 21, no. 11, pp. 1–7, 2017.

- [22] K. Yordanova, S. Stilgenbauer, R. M. Bohle et al., “Spontaneous regression of a plasmablastic lymphoma with MYC rearrangement,” *British Journal of Haematology*, vol. 186, no. 6, pp. e203–e207, 2019.
- [23] K. Ono, T. Okui, S. Ibaragi et al., “A case of intraoral plasmablastic lymphoma spontaneously regressed after biopsy in HIV-negative patient,” *Journal of Oral and Maxillofacial Surgery, Medicine, and Pathology*, vol. 31, no. 4, pp. 280–283, 2019.