

Case Report

An Unusual Case of Asystole Occurring during Deep Brain Stimulation Surgery

Ha Son Nguyen,¹ Harvey Woehlk,² and Peter Pahapill^{1,3}

¹Neurosurgery, Medical College of Wisconsin, Milwaukee, WI 53226, USA

²Anesthesiology, Medical College of Wisconsin, Milwaukee, WI 53226, USA

³Neurosurgery, Clement J. Zablocki VA Medical Center, Milwaukee, WI 53295, USA

Correspondence should be addressed to Ha Son Nguyen; hsnguyen@mcw.edu

Received 25 February 2016; Revised 6 April 2016; Accepted 7 April 2016

Academic Editor: Abbass Amirjamshidi

Copyright © 2016 Ha Son Nguyen et al. This is an open access article distributed under the Creative Commons Attribution License, which permits unrestricted use, distribution, and reproduction in any medium, provided the original work is properly cited.

Background. Symptomatic bradycardia and hypotension in neurosurgery can produce severe consequences if not managed appropriately. The literature is scarce regarding its occurrence during deep brain stimulation (DBS) surgery. **Case Presentation.** A 67-year-old female presented for left DBS lead placement for essential tremors. During lead implantation, heart rate and blood pressure dropped rapidly; the patient became unresponsive and asystolic. Chest compressions were initiated and epinephrine was given. Within 30 seconds, the patient became hemodynamically stable and conscious. A head CT demonstrated no acute findings. After deliberation, a decision was made to complete the procedure. Assuming the etiology of the episode was the Bezold-Jarisch reflex (BJR), appropriate accommodations were made. The procedure was completed uneventfully. **Conclusion.** The episode was consistent with a manifestation of the BJR. The patient had a history of neurocardiogenic syncope and a relatively low-volume state, factors prone to the BJR. Overall, lead implantation can still occur safely if preventive measures are employed.

1. Background

Deep brain stimulation (DBS) has become a widely accepted therapy for adjustable, reversible modulation of brain function. Rare, but notable, intraoperative complications include critical hemodynamic instability, particularly symptomatic bradycardia and hypotension, which has been associated with venous air embolism [1]. To the authors' knowledge, there has been no occurrence linked to the Bezold-Jarisch reflex (BJR), a cardioinhibitory reflex that has been associated with states of hypovolemia. Herein, the authors describe a patient who exhibited acute, dramatic asystole during DBS surgery. The episode was consistent with the BJR. After appropriate measures were pursued, the patient underwent an uneventful implantation of her electrode.

2. Case Report

2.1. Initial Presentation. A 67-year-old right-handed female with a history of neurocardiogenic syncope, irritable bowel syndrome, and hypothyroidism had been suffering from

essential tremors for 25 years. Notably, she also had an extensive family history of neurocardiogenic syncope. Exam revealed bilateral upper extremity grade 2/4 intention tremors. Baseline vital signs included height 167 cm, weight 46 kg, blood pressure 90–100s/50–60s, and heart rate 60–90s.

2.2. Initial DBS Implantation. She underwent a Leksell frame-based placement of a left VIM DBS with microrecording, resulting in a significant lesion effect and intraoperative tremor arrest with macrostimulation. Immediately, postoperatively, the patient demonstrated mild difficulty with coordination and speech production, as well as an odd sensation in the right hand. A CT head demonstrated a small hemorrhage at the tip of the lead (Figure 1). At the first programming session, her initial postoperative symptoms, including her lesion effect, had resolved and she demonstrated no benefits from stimulation. An MRI brain confirmed a small resolving hematoma at the tip of the lead (Figures 2(a) and 2(b)); consequently, further programming was held off until the hematoma resolved. A month later, DBS programming again

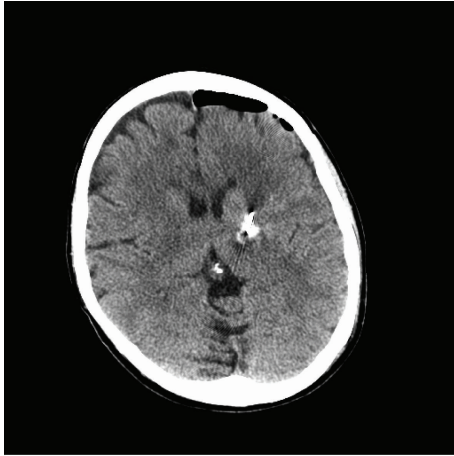

FIGURE 1: CT head demonstrated a small hemorrhage at the tip of the lead.

demonstrated no benefits. Revision surgery was recommended.

2.3. Initial Revision Attempt. During application of the Leksell stereotactic frame, the patient felt nauseated and promptly became unresponsive. Vital signs were stable. The frame was removed and the patient was placed supinely. Within minutes, she was back to neurologic baseline. A CT head demonstrated no acute findings. The case was cancelled, and the patient was admitted for further evaluation. Work-up included medicine, neurology, psychiatry, and cardiology consultations. No structural heart disease or malignant arrhythmias were identified. Further history revealed several recent fainting episodes. The present episode was attributed to neurocardiogenic syncope. She was also evaluated for a potential psychiatric component given the fact that this occurred a few days away from what would have been her late husband's birthday and a few weeks from the one-year anniversary of his death. A diagnosis of major depressive disorder related to grief was made and a trial of mirtazapine was started. She reported improvement in mood, appetite, and sleep.

2.4. Revision Surgery. Three months later, frame placement ensued without issues. The previous burr hole was exposed. After microelectrode mapping, the DBS electrode was placed. Prior to test macrostimulation through the DBS lead, the patient complained of severe nausea. HR decreased quickly from 80–90s to 20–30s and blood pressure from 120s/60s to 60s/30s. The patient became unresponsive and asystolic; respiratory rate remained stable at 10–16. Chest compressions were initiated immediately by the movement disorder neurologist and administration of epinephrine 0.1 mg IV occurred. Subsequently, within 30 seconds, the patient demonstrated return of hemodynamic stability and became responsive, answering simple questions. HR was in the 90s to 100s, and BP was 90s/50s. The procedure was stopped. The DBS electrode and stereotactic arc, but not frame, were removed and

the incision was closed. A stat CT head did not demonstrate any abnormality.

Extensive discussions occurred with the patient, the anesthesia team, the neurology team, and the patient's family. The decision was made to bring her immediately back to the operating room and complete the procedure by implanting the DBS electrode as planned. Believing the episode was due to the BJR, the patient was treated with glycopyrrolate and a 20 mL/kg normal saline bolus. There was no recurrence of bradycardia, hypotension, or asystole. Test stimulation through the implanted DBS electrode revealed tremor arrest. There were no postoperative concerns and the patient was discharged the following morning. The patient was seen at 2 weeks' follow-up for adjustment of her DBS settings, which was left at C(+)-0(-), 2.2 v, 60 uS, and 150 Hz with tremor arrest and no side effects. At 14 months, she continued to do well and was considering placement of a right DBS electrode to control her remaining left-sided tremors.

3. Discussion

We believe the described episode was consistent with the BJR reflex. This reflex is a cardioinhibitory reflex that has been associated with states of hypovolemia [2]. Its afferent limb is facilitated by cardiac receptors via nonmyelinated type C vagal fibers [3]. An initial response to hypovolemia is sensed in the carotid sinus baroreceptors, causing a compensatory phase with increased heart rate, vasoconstriction, and contractility [3]. However, with an empty hypercontractile ventricle, stimulation of the intramyocardial C fibers can potentiate a sudden withdrawal of sympathetic outflow, increasing vagal tone, which can trigger bradycardia and hypotension [3]. The reflex has been described during spinal anesthesia, due to the decrease in preload, and during shoulder arthroscopic surgery interscalene brachial plexus block, due to venous blood pooling associated with the sitting position. A debatable predisposing factor has been the use of exogenous epinephrine (as a local anesthetic), which may prompt beta-adrenergic effects that increase cardiac contractility, triggering reflex arterial vasodilation and bradycardia [4, 5]. Treatment options include immediate fluid resuscitation, vagolytics (atropine and glycopyrrolate) [6, 7], and early use of IV epinephrine [2]. Other reported therapeutic medications include ondansetron [7], metoprolol [8], and ephedrine [6]. Altering the patient's position to a supine position can also help hemodynamics [9].

Our patient was predisposed to the BJR: (1) she had a history of vasovagal (neurocardiogenic?) syncope, (2) she possessed a thin body frame, which likely put her in a sensitive volume state, (3) she received limited intravenous fluids perioperatively to avoid hypertension, and (4) she was in a beach chair position for surgery, causing venous pooling. Hypovolemia (relative or absolute) could increase the risk of vasodepressor and bradycardic responses [2]. Likewise, short- and long-acting local anesthetic with epinephrine were utilized for the procedure.

Other etiologies of symptomatic bradycardia and hypotension in cranial neurosurgery include venous air embolism and the trigeminal cardiac reflex (TCR) (Table 1). Air

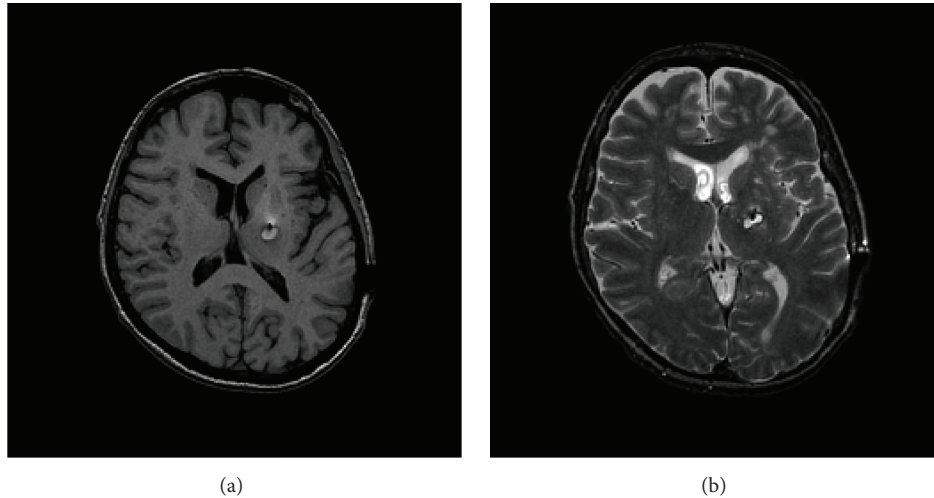


FIGURE 2: (a) An MRI brain confirmed a small resolving hematoma at the tip of the lead. (b) An MRI brain confirmed a small resolving hematoma at the tip of the lead.

TABLE 1: Comparison of various etiologies of symptomatic bradycardia and hypotension.

	Venous air embolism	Trigeminal cardiac reflex	Bezold-Jarisch reflex
Incidence	Up to 4.5% in DBS surgeries [10]	Up to 18% in neurosurgery series [11]. No known prior reports in DBS surgery	No known prior reports in neurosurgery
Triggers	Trephination	Irritation of trigeminal nerve or sensory branches	Hypovolemia, spinal anesthesia leading to decrease preload
Mechanism	Entrance of air into venous system	Afferent limb, stimulation of the trigeminal nerve or sensory branches Efferent limb, activation of vagal motor nucleus and inhibition of heart and systemic vascular system	Afferent limb, cardiac receptors via nonmyelinated type C vagal fibers Efferent limb, intramyocardial C fibers can potentiate a sudden withdrawal of sympathetic outflow, increasing vagal tone
Presentation	ST-T changes, right heart strain, oxygen desaturation, low end tidal CO ₂ , coughing, wheezing, chest pain, “swoon,” and so forth	Bradycardia, hypotension, apnea, and gastric hypermotility	Bradycardia, hypotension
Predisposing factors	Sitting position, semisitting position	Use of medications (beta blockers, calcium channel blockers, sufentanil, and alfentanil), history of vagal episodes, presence of hypercapnea or hypoxemia, and light anesthesia	History of neurocardiogenic syncope, hypovolemia, medications (local anesthetic with epinephrine), sitting position, decreasing preload, and venous blood pooling
Treatment	Obtaining hemostasis, irrigation of surgical field, leveling patient’s head to right atrium in left lateral decubitus, and use of central venous catheter for aspiration of air	Increased depth of anesthesia (i.e., propofol bolus)	Immediate fluid resuscitation, vagolytics (atropine and glycopyrrolate), ondansetron, metoprolol, and ephedrine

embolism typically occurs during trephination, with an episode of coughing followed by a “swoon” in blood pressure [12, 13]. However, in the case presented here, the episode occurred 90 minutes after her previous burr hole was exposed. There was no new trephination, coughing episode, or elevation in respiratory rate to suggest that venous air embolism was the underlying etiology. Moreover, symptoms

from venous air embolism would be gradually progressive and improve only after appropriate therapeutic maneuvers were performed. Our patient had a rapid clinical course, which was inconsistent with a venous air embolism.

The TCR involves stimulation of the trigeminal nerve or sensory branches, which leads to activation of the vagal motor nucleus and inhibition of the heart and systemic vascular

system [1, 14]. Placement of a stereotactic frame can elicit the TCR if a pin was erroneously placed on the supraorbital nerve [15]. Irritation of the dura mater (i.e., cauterization of the cerebellar tentorium [16], evacuation of a subdural empyema [17], embolization of dural-based vascular pathologies [14, 18], and resection of a falcine meningioma [19]) may also elicit the reflex. Predisposing factors include the use of certain perioperative medications (beta blockers, calcium channel blockers, sufentanil, and alfentanil), a history of high vagal tone, and the presence of hypercapnea or hypoxemia [16, 20–22]. On the other hand, the depth of sedation and anesthesia may play a role in blocking the reflex [22, 23]. Although the patient was not sedated during implantation of the DBS macroelectrode, irritation of the dura was likely minimal during implantation. Table 1 summarizes the key differences between venous air embolism, TCR, and BJR.

4. Conclusions

With neurosurgery, intraoperative symptomatic bradycardia and hypotension can produce severe consequences if not managed appropriately. The hemodynamic instability may be explained by venous air embolism, the TCR, or the BJR. Previous instances during DBS surgery have been ascribed to venous air embolism during trephination. This report describes a precipitous episode with eventual asystole that was likely mediated by the BJR. This has not been documented previously with DBS surgery. The patient's threshold for the BJR was lowered due to her underlying history, coupled with hypovolemia (based on fluid management, body habitus, and beach chair positioning) and the use of epinephrine as a local anesthetic. After appropriate preventive interventions, the surgery was performed uneventfully.

Competing Interests

The authors declare no competing interests.

References

- [1] T. Chowdhury, A. Petropolis, and R. B. Cappellani, "Cardiac emergencies in neurosurgical patients," *BioMed Research International*, vol. 2015, Article ID 751320, 14 pages, 2015.
- [2] S. M. Kinsella and J. P. Tuckey, "Perioperative bradycardia and asystole: relationship to vasovagal syncope and the Bezold-Jarisch reflex," *British Journal of Anaesthesia*, vol. 86, no. 6, pp. 859–868, 2001.
- [3] J. A. Campagna and C. Carter, "Clinical relevance of the Bezold-Jarisch reflex," *Anesthesiology*, vol. 98, no. 5, pp. 1250–1260, 2003.
- [4] K. C. Seo, J. S. Park, and W. S. Roh, "Factors contributing to episodes of bradycardia hypotension during shoulder arthroscopic surgery in the sitting position after interscalene block," *Korean Journal of Anesthesiology*, vol. 58, no. 1, pp. 38–44, 2010.
- [5] S. Sia, F. Sarro, A. Lepri, and M. Bartoli, "The effect of exogenous epinephrine on the incidence of hypotensive/bradycardic events during shoulder surgery in the sitting position during interscalene block," *Anesthesia and Analgesia*, vol. 97, no. 2, pp. 583–588, 2003.
- [6] J. G. D'Alessio, R. S. Weller, and M. Rosenblum, "Activation of the Bezold-Jarisch reflex in the sitting position for shoulder arthroscopy using interscalene block," *Anesthesia and Analgesia*, vol. 80, no. 6, pp. 1158–1162, 1995.
- [7] R. M. Martinek, "Witnessed asystole during spinal anesthesia treated with atropine and ondansetron: a case report," *Canadian Journal of Anesthesia*, vol. 51, no. 3, pp. 226–230, 2004.
- [8] G. A. Liguori, R. L. Kahn, J. Gordon, M. A. Gordon, and M. K. Urban, "The use of metoprolol and glycopyrrolate to prevent hypotensive/bradycardic events during shoulder arthroscopy in the sitting position under interscalene block," *Anesthesia and Analgesia*, vol. 87, no. 6, pp. 1320–1325, 1998.
- [9] Y. H. Kim, D. J. Kim, and W. Y. Kim, "Bezold-Jarisch reflex caused by postural change," *Journal of Anesthesia*, vol. 29, no. 1, p. 158, 2014.
- [10] A. K. Hooper, M. S. Okun, K. D. Foote et al., "Venous air embolism in deep brain stimulation," *Stereotactic and Functional Neurosurgery*, vol. 87, no. 1, pp. 25–30, 2009.
- [11] F. Lemaitre, T. Chowdhury, and B. Schaller, "The trigeminocardiac reflex—a comparison with the diving reflex in humans," *Archives of Medical Science*, vol. 11, no. 2, pp. 419–426, 2015.
- [12] A. J. Fenoy and R. K. Simpson Jr., "Risks of common complications in deep brain stimulation surgery: management and avoidance-clinical article," *Journal of Neurosurgery*, vol. 120, no. 1, pp. 132–139, 2014.
- [13] C. Kenney, R. Simpson, C. Hunter et al., "Short-term and long-term safety of deep brain stimulation in the treatment of movement disorders," *Journal of Neurosurgery*, vol. 106, no. 4, pp. 621–625, 2007.
- [14] B. Schaller, A. Filis, and M. Buchfelder, "Trigeminocardiac reflex in embolization of intracranial dural arteriovenous fistula," *American Journal of Neuroradiology*, vol. 29, no. 7, article E55, 2008.
- [15] P. Stavrinou, N. Foroglou, I. Patsalas, and P. Selviaridis, "Trigeminocardiac reflex and ipsilateral mydriasis during stereotactic brain tumor biopsy: an insight into the anatomical and physiological pathways involved," *Acta Neurochirurgica*, vol. 152, no. 4, pp. 727–728, 2010.
- [16] K. Usami, K. Kamada, N. Kunii, H. Tsujihara, Y. Yamada, and N. Saito, "Transient asystole during surgery for posterior fossa meningioma caused by activation of the trigeminocardiac reflex: three case reports," *Neurologia Medico-Chirurgica*, vol. 50, no. 4, pp. 339–342, 2010.
- [17] T. Spiriev, N. Sandu, B. Arasho, S. Kondoff, C. Tzekov, and B. Schaller, "A new predisposing factor for trigemino-cardiac reflex during subdural empyema drainage: a case report," *Journal of Medical Case Reports*, vol. 4, article 391, 2010.
- [18] X. Lv, Y. Li, C. Jiang, and Z. Wu, "The incidence of trigeminocardiac reflex in endovascular treatment of dural arteriovenous fistula with onyx," *Interventional Neuroradiology*, vol. 16, no. 1, pp. 59–63, 2010.
- [19] D. F. Bauer, A. Youkilis, C. Schenck, C. R. Turner, and B. G. Thompson, "The falcine trigeminocardiac reflex: case report and review of the literature," *Surgical Neurology*, vol. 63, no. 2, pp. 143–148, 2005.
- [20] A. Amirjamshidi, K. Abbasioun, F. Etezadi, and S. B. Ghasemi, "Trigeminocardiac reflex in neurosurgical practice: report of two new cases," *Surgical Neurology International*, vol. 4, article 126, 2013.
- [21] L. M. Cavallo, D. Solari, and F. Esposito, "Trigeminocardiac reflex: a predictable event with unpredictable aspects," *World Neurosurgery*, vol. 76, no. 5, pp. 407–408, 2011.

- [22] F. Etezadi, A. A. Orandi, A. H. Orandi et al., "Trigemino-cardiac reflex in neurosurgical practice: an observational prospective study," *Surgical Neurology International*, vol. 4, article 116, 2013.
- [23] C. Yi and D. Jee, "Influence of the anaesthetic depth on the inhibition of the oculocardiac reflex during sevoflurane anaesthesia for paediatric strabismus surgery," *British Journal of Anaesthesia*, vol. 101, no. 2, pp. 234–238, 2008.



Hindawi
Submit your manuscripts at
<http://www.hindawi.com>

