

SUPPLEMENTARY FIGURES:

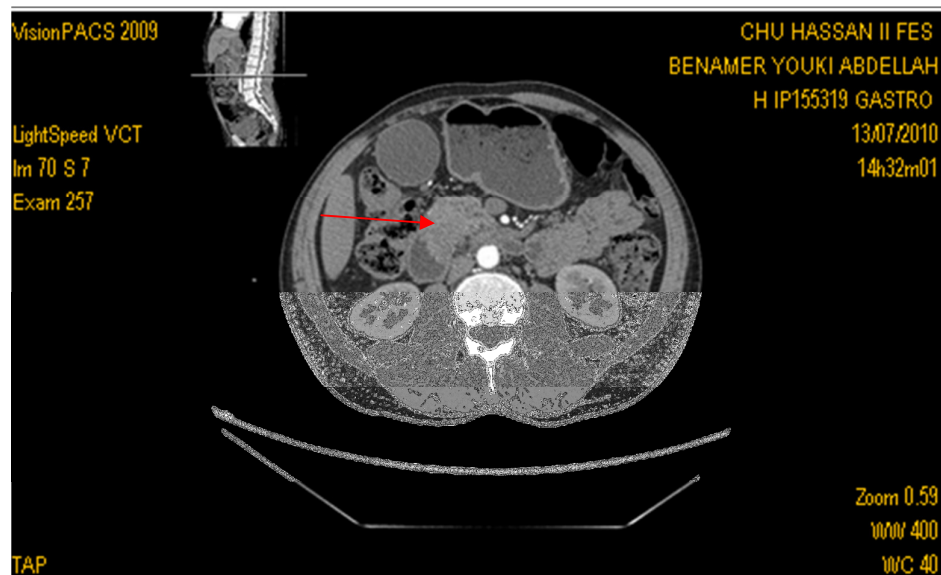


Figure 1: CT scan of the abdomen cut showed a process in the ampulla of Vater

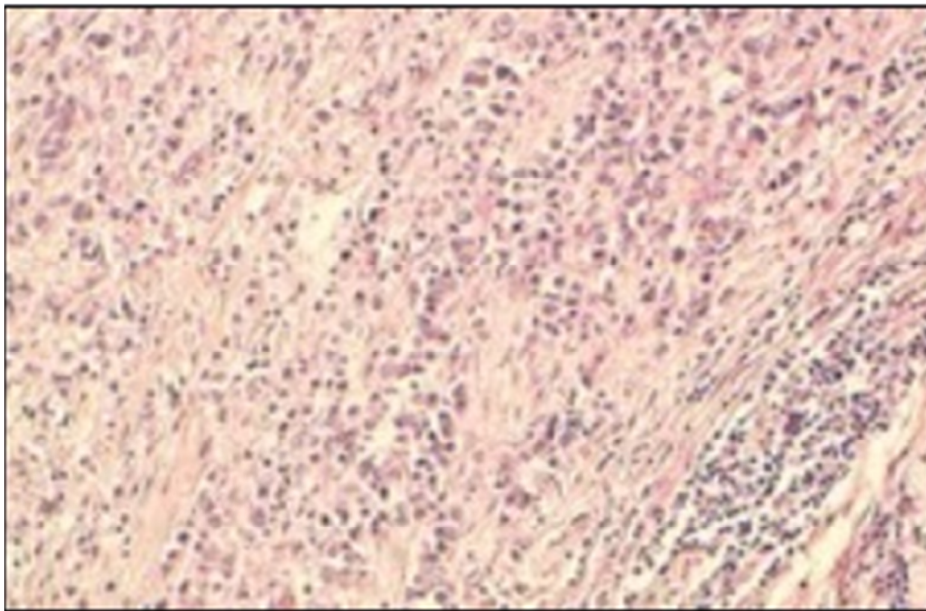


Figure 2: The tumor was solely formed by signet ring cell carcinoma