

Case Report

A Case of Calcified Metastatic Colorectal Adenocarcinoma Mimicking a Benign Lesion: Pitfalls in Diagnosis

Peter Michail,¹ Iftah Amith,² Sanila George,³ and Mathew K. George⁴

¹School of Medicine and Public Health, University of Newcastle, University Drive, Callaghan, NSW 2308, Australia

²University of New England, Elm Avenue, Armidale, NSW 2351, Australia

³Hunter Imaging, 7 Bligh Street, Tamworth, NSW 2348, Australia

⁴Department of Medical Oncology, North West Cancer Centre, 31 Dean Street, Tamworth, NSW 2340, Australia

Correspondence should be addressed to Peter Michail; petermichail90@gmail.com

Received 8 November 2014; Revised 24 January 2015; Accepted 26 January 2015

Academic Editor: Francesco A. Mauri

Copyright © 2015 Peter Michail et al. This is an open access article distributed under the Creative Commons Attribution License, which permits unrestricted use, distribution, and reproduction in any medium, provided the original work is properly cited.

The radiological finding of a calcified intracranial lesion commonly represents a slow growing benign mass. Brain metastases originating from colorectal cancers are rare, occurring in approximately 2-3% of patients. Therefore the presence of a calcified brain lesion in a patient with a positive oncological history requires a high index of suspicion for brain metastases. Presented herein is a case of a frontoparietal calcified lesion initially overlooked as a benign tumour. Subsequent imaging following a neurological episode revealed a significant increase in size of the lesion with surrounding tissue oedema, prompting further investigation for suspicion of a calcified metastatic colorectal adenocarcinoma.

1. Introduction

The radiological findings of calcified intracranial lesions generally represent slow growing, benign masses [1]. Most common differential diagnoses include angiomas, gliomas, meningiomas, and granulomatous lesions [1]. It is rare for metastatic brain lesions to present with calcification; however these represent approximately 1-3.5% of cases found on computer tomography (CT) [1-4].

We present a case of a frontoparietal calcified brain lesion initially diagnosed as either a meningioma or a granuloma. Subsequently, with a delay of just under a year, the lesion was correctly diagnosed as metastatic colorectal adenocarcinoma.

2. Case Presentation

The patient is a 61-year-old female who was diagnosed with colorectal carcinoma (CRC) in 2011. The diagnosis was made after colonoscopic examination revealed an obstructing mass. The patient underwent an anterior resection with subsequent investigations revealing high grade metastatic adenocarcinoma. The patient was started on palliative chemotherapy consisting of FOLFOX and Avastin.

Two years after diagnosis (04/2013) a CT brain with contrast was performed revealing an incidental finding of a calcified lesion (Figure 1). The calcified focus was 6 × 10 mm located superficially in the high right frontoparietal region with no obvious enhancement of soft tissue density. It was reported as a diagnosis of either an old meningioma or granuloma. Based on the small size, location, calcification, and uniform enhancement after contrast administration, with no oedema or tissue enhancement, the decision was made not to investigate further and treat conservatively.

One year later (March 2014) the patient had an unanticipated episode consisting of uncontrolled neuromotor disturbances with ophthalmoplegia. The event was suspicious for an acute dystonic reaction due to frequent Maxolon (metoclopramide) administration. The episode subsequently self-resolved; however residual left arm weakness was apparent for the following two weeks. A CT brain was organised to exclude metastases and other organic pathologies. The previous calcified lesion on CT was noted to have increased significantly in size to 3 cm with prominent surrounding tissue oedema (Figure 2).

This was increasingly suspicious of a metastatic brain lesion. MRI scan was organised for confirmation, revealing

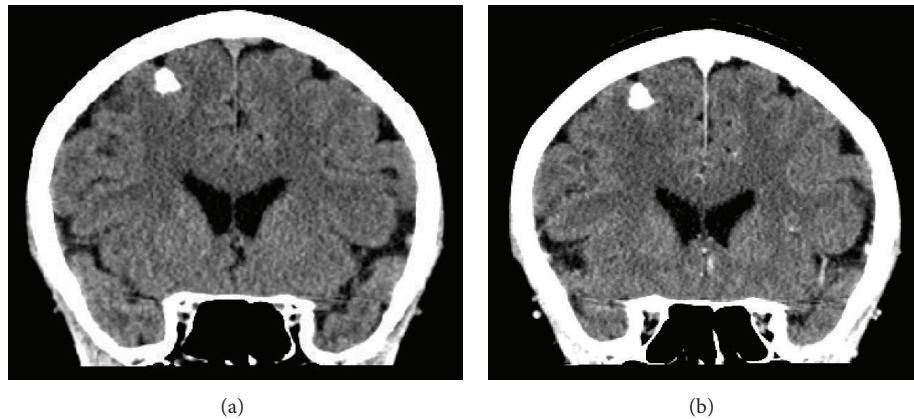


FIGURE 1: (a) 2013 precontrast CT coronal view. (b) 2013 postcontrast CT coronal view.

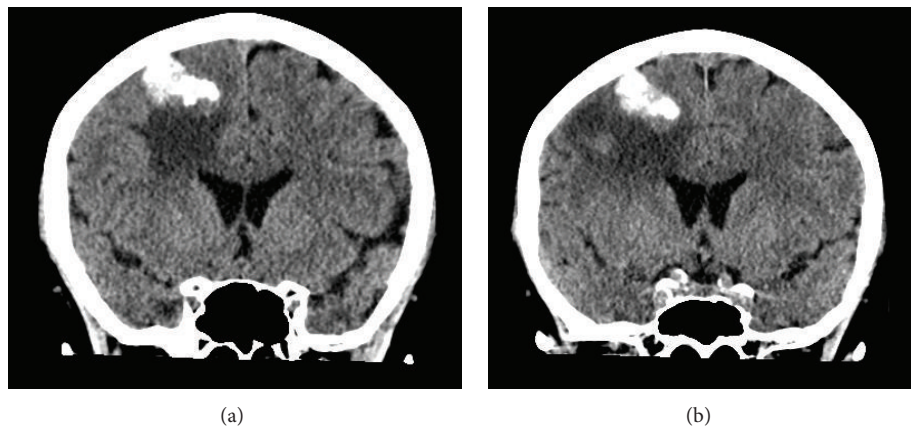


FIGURE 2: (a) 2014 precontrast CT, coronal view. (b) 2014 postcontrast CT, coronal view.

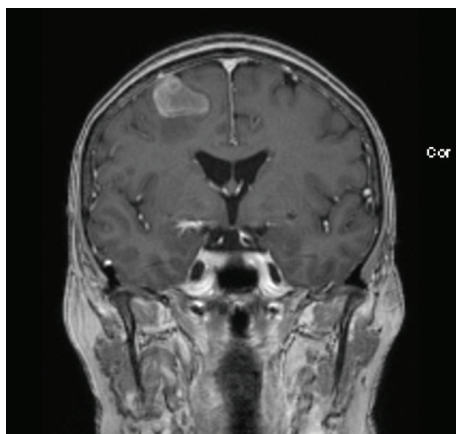


FIGURE 3: 2014 MR image, coronal view.

a nonenhancing intra-axial mass lesion with surrounding vasogenic oedema consistent with the calcified lesion seen on CT (Figure 3). The appearance was not typical for a meningioma, and given the previous history of CRC, it was highly suspicious of a calcified metastatic focus.

Stereotactic craniotomy was performed with successful excision of the tumour. Histological examination of the surgical specimen revealed an adenocarcinoma with abundant tumour necrosis; the tumour was composed of broad palisading glands, papillary formations, and dystrophic calcification (Figure 4). The immunohistochemical profile and morphological features were consistent with the diagnosis of metastatic adenocarcinoma of colorectal origin. The postoperative course was uneventful. The patient received postoperative whole brain radiotherapy and remained well with a good performance status.

3. Discussion

The calcification of brain metastases is extremely rare and can easily be misdiagnosed as a benign tumour [1]. Generally, the long periods required for the deposition of calcium result in the differential diagnosis of slow progressive benign cysts and tumours [2]. Despite the rarity of calcified brain metastases, correct identification of the pathology is vital towards tailoring an appropriate treatment regime.

The most common primary sites reported to produce calcified metastatic cerebral lesions include breast, lungs, ovaries, and colon [4]. The detection of calcified metastases

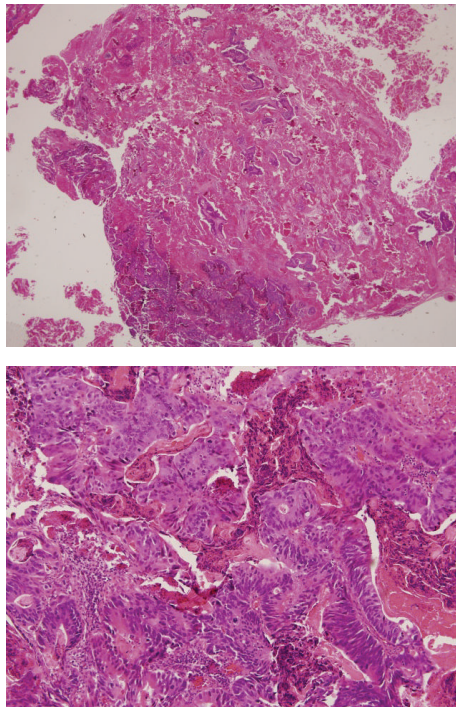


FIGURE 4: Advanced metastatic adenocarcinoma with focal haemorrhage and palisading glands with papillary formation.

is dependent on the imaging modality, with an incidence of 1.4% by plain skull radiographs and 3.5% by CT scanning [2, 5–7]. 2.3–4% of CRC patients are clinically diagnosed with brain metastasis [8, 9]. The most common site is the cerebellum, where 35–55% of CRC brain metastases are found [8–11]. Lesions in the frontal lobe are less common with a reported incidence of 23–33% [8, 12].

Our case demonstrates a solitary calcified frontal lobe nodule, which metastasised from CRC. Using simple arithmetic and known statistics we can appreciate why such a diagnosis can be difficult to determine. Assuming that 2.3% of CRC metastases to the brain and only 3.5% calcify, a rough estimate of only 0.08% of patients with CRC would have such radiological findings [6, 8].

Unlike other metastatic lesions that can be localised using positron emission tomography (PET) scan, brain metastasis proves to be difficult [13]. Magnetic resonance imaging has been established as a superior imaging modality for brain metastases [14]. Sánchez de Cos Escuín et al. reported that cranial MRI had a higher percentage of silent brain metastases diagnosed compared to cranial CT [14]. MRI also performed better than CT in the detection of multiple brain metastases and lesions smaller than 1 cm [14]. Magnetic resonance imaging therefore remains the gold standard for cerebral lesions [15].

Differentiating between metastatic cerebral lesions and benign intracranial neoplasms, such as a meningioma for example, is imperative to appropriate treatment planning. The best therapeutic approach to an asymptomatic benign lesion is conservative treatment with close follow-up to avoid

surgical morbidity [16]. Our case highlights the importance of close follow-up of patients diagnosed with an asymptomatic cerebral lesion. Prior to commitment to conservative treatment the patient must be thoroughly investigated with MR imaging which is considered gold standard for cerebral lesions [17]. Once the clinical decision for conservative treatment has been made the following schedule for low grade tumour follow-up is recommended. MR imaging at a 3-month basis for the first 1 year followed by 6–12-month imaging for another 5 years, with progressively less frequent intervals for the years beyond [17].

The differential diagnoses for solitary calcified lesions depending on location include angiomas, meningiomas, and gliomas [18]. In comparison, the differential diagnoses for multiple calcified lesions include toxoplasmosis, postirradiation changes, tuberous sclerosis, tuberculoma, and other granulomatous diseases [18]. Amongst calcified metastatic lesions, the most commonly reported histological type is adenocarcinoma [4, 10].

McCutcheon reported a median survival of 1–3 months for patients with untreated CRC brain metastases [19]. The median survival for patients treated with surgery was greater at 9 months [19]. Mege et al. confirmed this benefit with surgical resection of brain metastases from colorectal carcinoma, increasing the median overall survival by up to 14 months [12]. Despite the lack of prognostic data specifically for calcified brain metastasis, the benefits of surgical treatment for brain metastases are evident. In the absence of systemic illness, the correct diagnosis enables prompt treatment with curative intent. In the context of disseminated disease, however, palliative treatment improves the patient's quality of life.

4. Conclusion

In conclusion, it is recommended that oncology patients should receive early brain scans even if asymptomatic, as it may lead to the early discovery of silent metastases leading to appropriate treatment, improved survival rates, and a heightened quality of life. Furthermore, the discovery of a single subcentimetric, nonenhancing calcific focus with no perilesional oedema in patients with a known oncology history must include metastases as a differential diagnosis, as although it is uncommon it is clinically significant.

Conflict of Interests

The authors declare that there is no conflict of interests regarding the publication of this paper.

References

- [1] D. Kawamura, T. Tanaka, M. Fuga et al., "Slow progression of calcified cerebellar metastasis from ovarian cancer: a case report and review of the literature," *Neurologia Medico-Chirurgica*, vol. 53, no. 10, pp. 722–726, 2013.
- [2] Y. Ohmoto, T. Nishizaki, K. Kajiwara, S. Nomura, H. Kameda, and M. Suzuki, "Calcified metastatic brain tumor—two case

- reports," *Neurologia Medico-Chirurgica*, vol. 42, no. 6, pp. 264–267, 2002.
- [3] K. Fink and J. Fink, "Imaging of brain metastases," *Surgical Neurology International*, vol. 4, supplement 4, pp. S209–S219, 2013.
 - [4] H. Nakase, T. Sakaki, T. Fujita et al., "Multiple calcified metastatic brain tumor—case report," *Neurologia Medico-Chirurgica*, vol. 31, no. 12, pp. 787–791, 1991.
 - [5] T. Griffiths, "Observations on cranial radiograph in a series of intracranial tumours," *British Journal of Radiology*, vol. 30, no. 350, pp. 57–69, 1957.
 - [6] D. G. Potts and G. T. Svare, "Calcification in intracranial metastases," *The American Journal of Roentgenology, Radium Therapy, and Nuclear Medicine*, vol. 92, pp. 1249–1251, 1964.
 - [7] M. D. F. Deck, A. V. Messina, and J. F. Sackett, "Computed tomography in metastatic disease of the brain," *Radiology*, vol. 119, no. 1, pp. 115–120, 1976.
 - [8] J. P. Mongan, C. E. Fadul, B. F. Cole et al., "Brain metastases from colorectal cancer: risk factors, incidence, and the possible role of chemokines," *Clinical Colorectal Cancer*, vol. 8, no. 2, pp. 100–105, 2009.
 - [9] M. Wroński and E. Arbit, "Resection of brain metastases from colorectal carcinoma in 73 patients," *Cancer*, vol. 85, no. 8, pp. 1677–1685, 1999.
 - [10] S. Bartelt, F. Momm, C. Weissenberger, and J. Lutterbach, "Patients with brain metastases from gastrointestinal tract cancer treated with whole brain radiation therapy: prognostic factors and survival," *World Journal of Gastroenterology*, vol. 10, no. 22, pp. 3345–3348, 2004.
 - [11] T. D. Alden, J. W. Gianino, and T. J. Saclarides, "Brain metastases from colorectal cancer," *Diseases of the Colon & Rectum*, vol. 39, no. 5, pp. 541–545, 1996.
 - [12] D. Mege, M. Ouaisi, D. Fuks et al., "Patients with brain metastases from colorectal cancer are not condemned," *Anticancer Research*, vol. 33, no. 12, pp. 5645–5648, 2013.
 - [13] L. K. Griffeth, "Use of PET/CT scanning in cancer patients: technical and practical considerations," *Proceedings (Baylor University Medical Center)*, vol. 18, no. 4, pp. 321–330, 2005.
 - [14] J. Sánchez de Cos Escuin, D. Masjoans Menna, M. A. Sojo González, J. Zamorano Quirantes, C. Disdier Vicente, and M. C. Pérez Calvo, "Silent brain metastasis in the initial staging of lung cancer: evaluation by computed tomography and magnetic resonance imaging," *Archivos de Bronconeumología*, vol. 43, no. 7, pp. 386–391, 2007.
 - [15] P. Bochev, A. Klisarova, A. Kaprelyan, B. Chaushev, and Z. Dancheva, "Brain metastases detectability of routine whole body 18F-FDG PET and low dose CT scanning in 2502 asymptomatic patients with solid extracranial tumors," *Hellenic Journal of Nuclear Medicine*, vol. 15, no. 2, pp. 125–169, 2012.
 - [16] S. Yano and J.-I. Kuratsu, "Indications for surgery in patients with asymptomatic meningiomas based on an extensive experience," *Journal of Neurosurgery*, vol. 105, no. 4, pp. 538–543, 2006.
 - [17] L. Burt Nabors, M. Ammirati, P. J. Bierman et al., "Central nervous system cancers: clinical practice guidelines in oncology," *Journal of the National Comprehensive Cancer Network*, vol. 11, no. 9, pp. 1114–1151, 2013.
 - [18] J. E. Paillas and W. Pellet, "Brain metastasis," in *Handbook of Clinical Neurology*, P. J. Vinken and G. W. Bruyn, Eds., vol. 18, p. 201, Elsevier, New York, NY, USA, 1975.
 - [19] I. E. McCutcheon, "Colorectal carcinoma and brain metastasis: distribution, treatment, and survival," *Annals of Surgical Oncology*, vol. 3, no. 5, pp. 453–463, 1996.

