

Case Report

Outer Retinopathies Associated with COVID-19 Infection: Case Reports and Review of Literature

Naima Zaheer ¹, Mohammad O. Tallouzi ^{1,2}, N. Ajith Kumar ¹,
and Sreekanth Sreekantam ¹

¹Birmingham and Midland Eye Centre, Sandwell & West Birmingham NHS Trust, Birmingham, UK

²Institute of Clinical Sciences, College of Medical and Dental Sciences, University of Birmingham, Birmingham, UK

Correspondence should be addressed to Naima Zaheer; naima.zaheer1@nhs.net

Received 28 September 2022; Revised 26 December 2023; Accepted 2 January 2024; Published 8 March 2024

Academic Editor: J. Fernando Arevalo

Copyright © 2024 Naima Zaheer et al. This is an open access article distributed under the Creative Commons Attribution License, which permits unrestricted use, distribution, and reproduction in any medium, provided the original work is properly cited.

Background. The coronavirus disease (COVID-19) is a highly contagious disease with profound health implications. It can affect any part of the body with variable severity. Various ophthalmic manifestations of coronavirus disease have been documented. **Case Presentations.** We reported three cases of outer retinopathies associated with COVID-19 infection. All three patients were young females. The first two patients presented within days of COVID-19 infection with complaints of black spots in the eyes. Multimodal retinal imaging showed lesions consistent with acute macular neuroretinopathy. Lesions were bilateral in the first patient and unilateral in the second one. Our third patient presented with blurred vision in one eye, 3 months after a suspected COVID-19 infection. Retinal imaging showed outer retinopathy. Our patients' vision was good and maintained during the follow-up. All three were monitored on observation only, and symptoms and lesions improved with time. **Conclusion.** In conclusion, COVID-19-related thromboinflammatory response can result in localized vascular inflammation and hypoperfusion in any of the retinal capillary plexuses or choriocapillaris resulting in ischemia of the corresponding retinal or choroidal layers.

1. Introduction

The coronavirus disease 2019 (COVID-19) is a highly contagious disease caused by severe acute respiratory syndrome coronavirus 2 (SARS-CoV-2) infection. It is characterized by an exaggerated inflammatory response and has a wide spectrum of clinical presentations ranging from mild flu-like illness and fever to adult respiratory syndrome, sepsis, coagulopathy, multiple organ disease, and death.

In March 2020, the World Health Organization declared the novel coronavirus outbreak a global pandemic [1]. A wide range of ophthalmological complications of coronavirus disease has been documented [2]. The most frequent ophthalmic complications are those involving the anterior segment (conjunctivitis, keratitis, episcleritis, ocular surface

disease, and acute angle closure), followed by posterior segment and neuro-ophthalmological complications (optic neuritis, ischemic optic neuropathy, optic disc swelling, papilledema, extraocular muscle palsies, and orbital compartment syndrome) [2]. Posterior segment complications can affect macrovascular and microvascular circulations leading to retinal venous and arterial occlusions, retinal haemorrhages, and cotton wool spots (CWS) [3, 4]. Retinal vascular abnormalities seem to be evolving as signature ophthalmic manifestations of COVID-19. In a review article, a significant eightfold increase in the prevalence of retinal microvasculopathy was observed in COVID-19 patients [5]. Few case reports also highlighted ocular manifestations as the first sign of COVID-19 infection [6].

In this paper, we are reporting three interesting cases of outer retinopathies associated with COVID-19 infection.

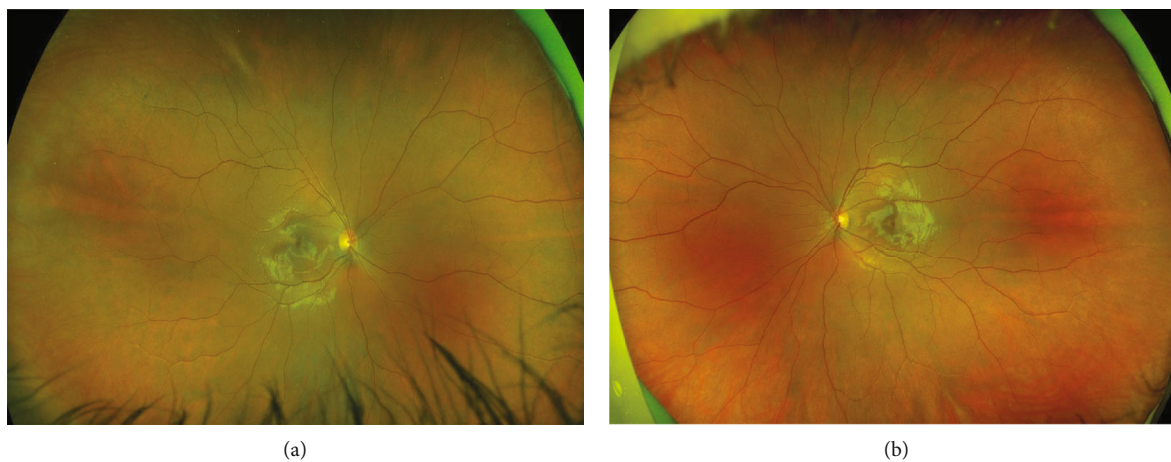


FIGURE 1: Case 1: wide-field retinal images—obtained by Optos: (a) right eye and (b) left eye.

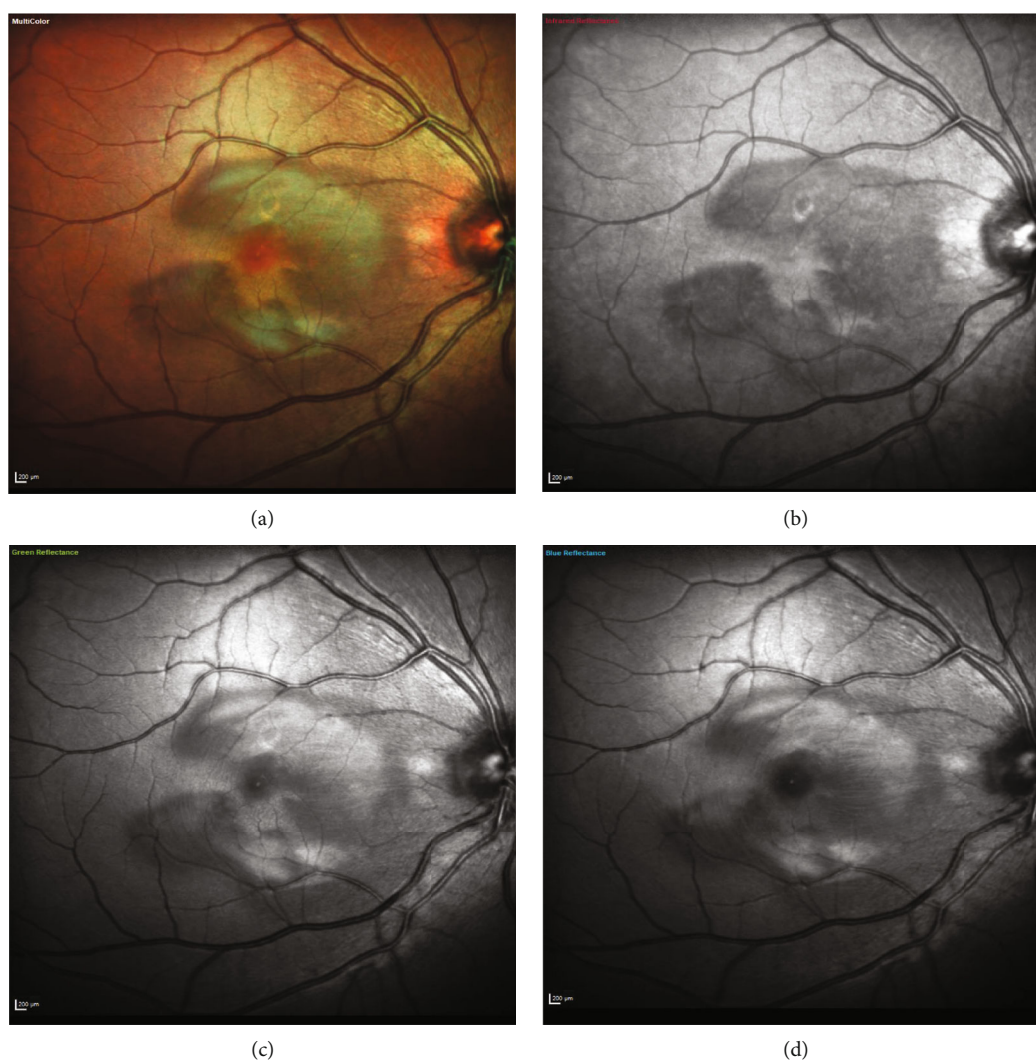


FIGURE 2: Case 1: multispectral fundus imaging of the right eye showing lesions of acute macular neuroretinopathy—(a) multicolor, (b) with infrared reflectance (IR -820 nm), (c) with green reflectance (GR -515 nm), and (d) with blue reflectance (BR -488 nm).

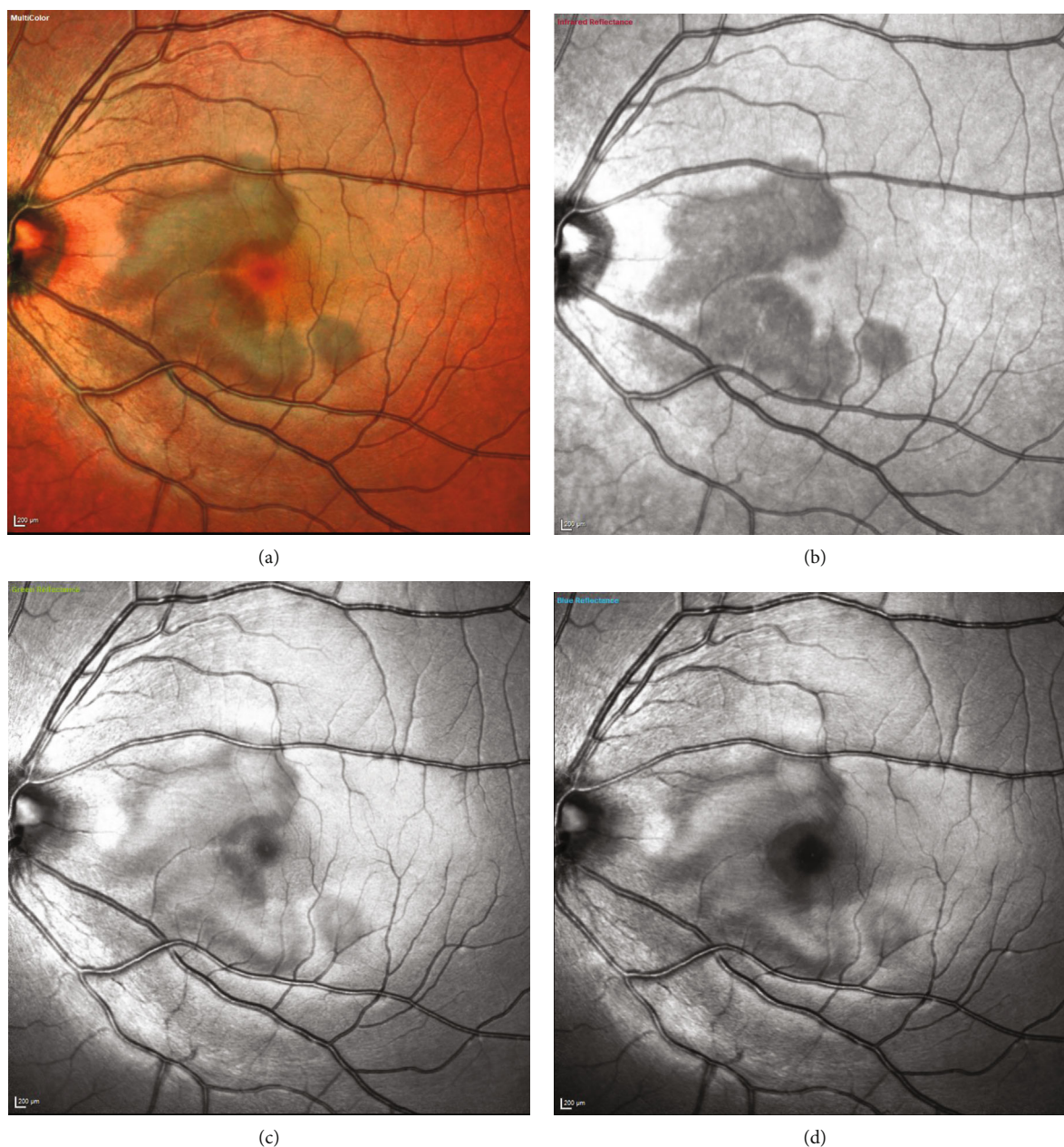


FIGURE 3: Case 1: multispectral fundus imaging of the left eye showing lesions of acute macular neuroretinopathy—(a) multicolor, (b) with infrared reflectance (IR -820 nm), (c) with green reflectance (GR -515 nm), and (d) with blue reflectance (BR -488 nm).

2. Case Presentations

2.1. Case 1. An 18-year-old Caucasian female presented in the eye casualty with complaints of black spots in both eyes. She was unwell for 3-4 days with fever and fatigue. Her nasopharyngeal swab tested positive for COVID-19. Her visual symptoms (of black spots) started after 2 days of being positive for COVID-19. She was a known asthmatic and was on oral contraceptive pills for a year.

On examination, visual acuity (using Snellen's chart) was 6/4 in both eyes. There were no signs of the anterior chamber or vitreous inflammation. Fundus examination was unremarkable in both eyes (Figure 1). Multispectral fundus

imaging showed well-defined pale lesions around the fovea in both eyes (Figures 2 and 3). Spectral-domain optical coherence tomography (SD-OCT) demonstrated focal areas of hyporeflectivity of the external limiting membrane (ELM), the cone ellipsoid zone, and the phagosome zone of retinal pigment epithelium (RPE) (Figures 4 and 5), correlating with the lesions on multispectral imaging. Optical coherence tomography angiography (OCT-A) showed patches of reduced flow signal in the choriocapillaris (Figure 6). Humphrey's visual fields 10-2 and 24-2 showed bilateral areas of reduced sensitivity corresponding with the lesions. On Multifocal electroretinogram (mf-ERG) areas of reduced amplitude and delayed P1 peak time were

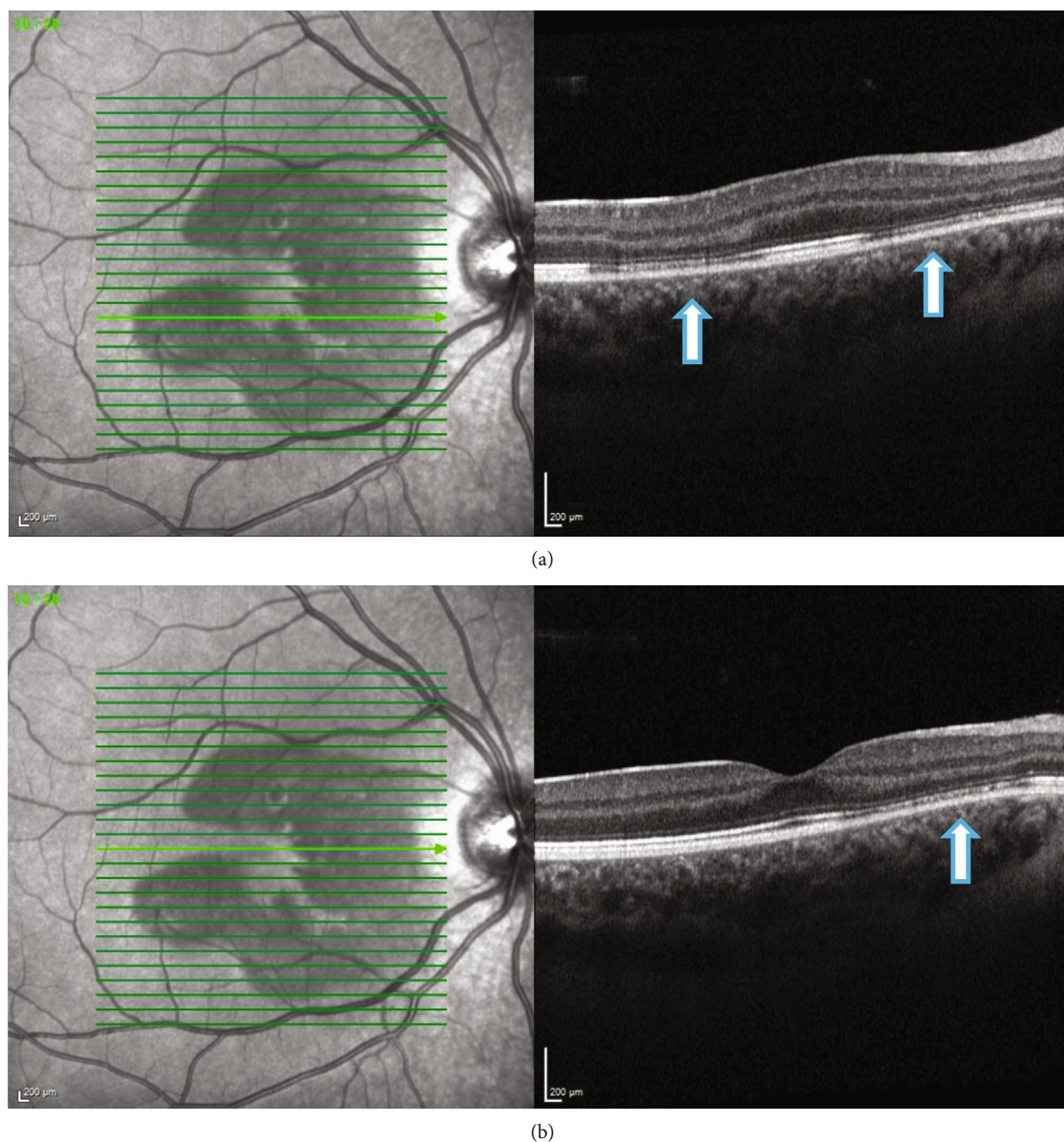


FIGURE 4: (a, b) Case 1: spectral-domain OCT of the right eye showing focal areas of hyporeflectivity of the external limiting membrane, the cone ellipsoid zone, and the phagosome zone of retinal pigment epithelium.

observed in both eyes. These changes were more significant nasally and were more significant in the left eye as compared to the right eye. Her blood tests for the inflammatory screen (baseline blood tests including full blood count, erythrocyte sedimentation rate, C-reactive protein, renal and liver function tests, haemoglobin A1c; serum levels of electrolytes, calcium, glucose, angiotensin-converting enzyme, immunoglobulins (IgG, IgM, and IgA), complement (C3 and C4), rheumatoid factor; and autoantibodies including antinuclear antibody, antineutrophilic cytoplasmic antibody, extractable nuclear antibodies, and cardiolipin antibody profile) were negative.

Diagnosis of acute macular neuroretinopathy (AMNR) possibly secondary to COVID-19 infection was considered. She was kept under close monitoring, and at 2-3 months, the lesions started improving (Figure 7) along with improvement in the visual fields.

2.2. Case 2. A 17-year-old Caucasian female presented in the eye casualty with complaints of a black patch in the right eye for 10 days. Initially, she noticed black patches in both eyes. After 1 week, the symptoms improved in the left eye, but the right eye had a persistent patch. Her visual symptoms started after one day of being positive for COVID-19. She had a history of hay fever and eczema and was on oral contraceptive pills for over a year.

On examination, visual acuity (using Snellen's chart) was 6/5 in both eyes. There were no signs of the anterior chamber or vitreous inflammation. Fundus examination showed a dark spot in the right eye near the fovea (Figure 8). Multi-spectral fundus imaging highlighted a well-defined pale lesion near the fovea in the right eye (Figure 9). Spectral-domain OCT demonstrated a patch of hyporeflectivity of the ELM, the cone ellipsoid zone, and the phagosome zone

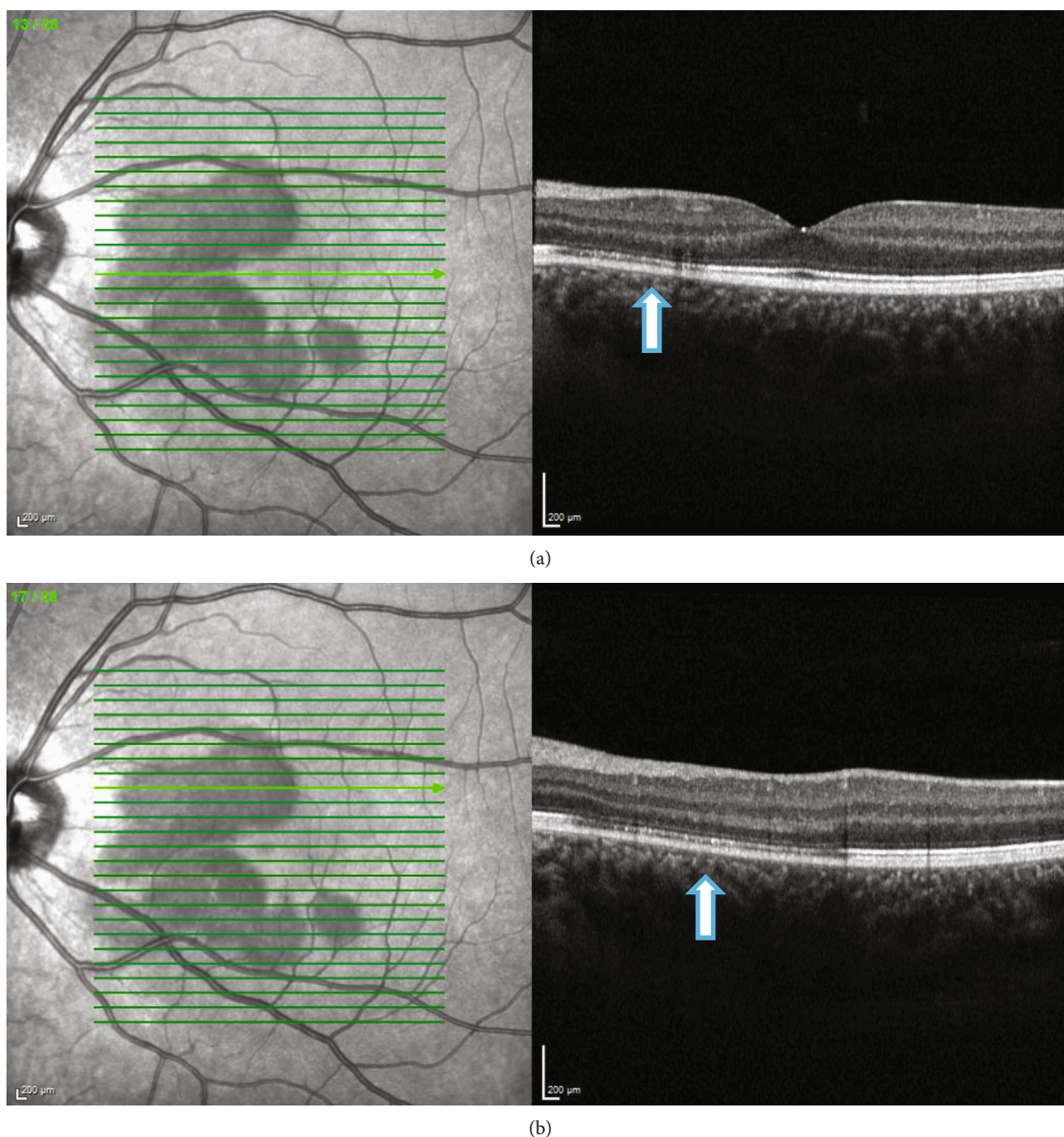


FIGURE 5: (a, b) Case 1: spectral-domain OCT of the left eye showing focal areas of hyporeflectivity of the external limiting membrane, the cone ellipsoid zone, and the phagosome zone of retinal pigment epithelium.

of RPE (Figure 10) correlating with the lesion on multicolor imaging. Optical coherence tomography angiography showed a small patch of reduced flow signal in the choriocapillaris (Figure 11). Humphrey's visual field 10-2 (Figure 12) showed an area of reduced sensitivity in the right eye corresponding with the lesion. Her blood tests for the inflammatory screen (the same tests as mentioned earlier in the first case) were negative.

Diagnosis of AMNR possibly secondary to COVID-19 infection was considered. She was kept under close monitoring, and after 2 months, the lesions started improving along with improvement in visual fields.

2.3. Case 3. A 14-year-old Chinese girl presented to the eye casualty with complaints of foggy vision in her left eye for

one week. There was no associated photopsia or floaters. Approximately three months back, she suffered from a viral illness and COVID-19 symptoms, along with a loss of sense of smell and taste. The nasopharyngeal swab testing was carried out a bit late and came out negative.

On examination, visual acuity (using Snellen's chart) was 6/4 and 6/5 in the right and the left eye, respectively. There were no signs of the anterior chamber or vitreous inflammation in both eyes. Spectral-domain OCT showed left outer retinopathy, with parafoveal loss of ONL, ELM, cone ellipsoid zone, and RPE phagosome zone (Figure 13). Her blood tests for the inflammatory screen were normal. However, antibodies to SARS-CoV-2 (SARS-CoV-2 Ig Tc Ab) were detected. She had not received any COVID-19 vaccine till that time.




FIGURE 6: Case 1: optical coherence tomography angiography (OCT-A) of the right and the left eye, showing patches of reduced flow signal in the choriocapillaris.

Diagnosis of outer retinopathy, presumably secondary to COVID-19 infection, was considered, although ocular involvement occurred late after the COVID-19 infection. As her visual acuity was good, she was monitored with observation only, and the outer retinopathy started improving after 6 weeks (Figure 14).

3. Discussion

We reported three interesting cases of outer retinopathies and AMNR associated with COVID-19 infection.

For the literature review, we performed a PubMed, Medline, Google Scholar, and Cochrane search using keywords of acute macular neuroretinopathy, COVID-19, and coronavirus infection. We reviewed all the case reports and case series in which AMNR was documented associated with COVID-19 infection.

The coronavirus disease is a highly contagious disease with profound health implications. It can affect any part of the body with variable severity. Various ophthalmic manifestations of coronavirus disease have been documented.

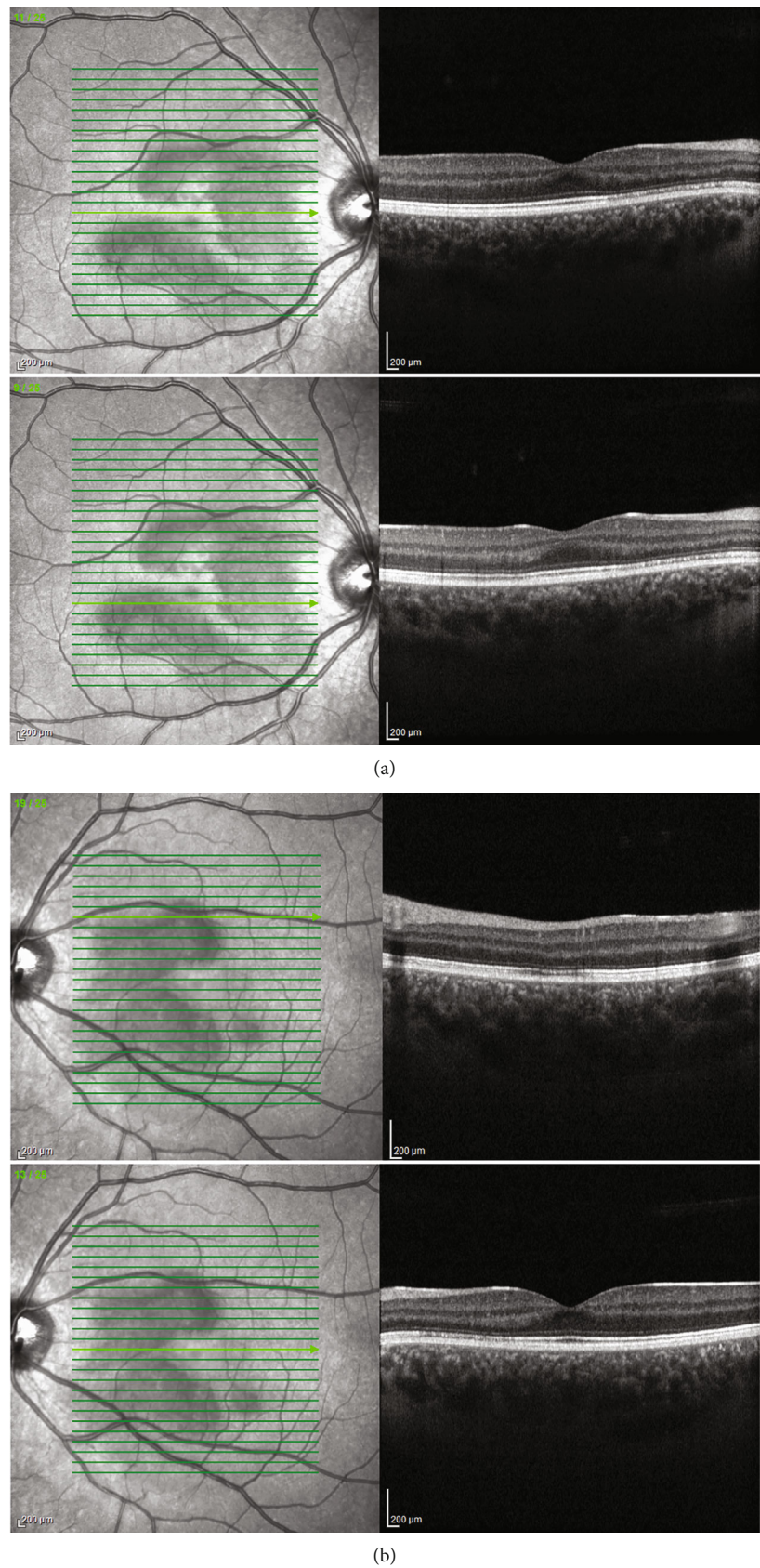


FIGURE 7: (a, b) Case 1: spectral-domain OCT after 2 months showing restoration of outer retinal layers in the (a) right and (b) left eye.

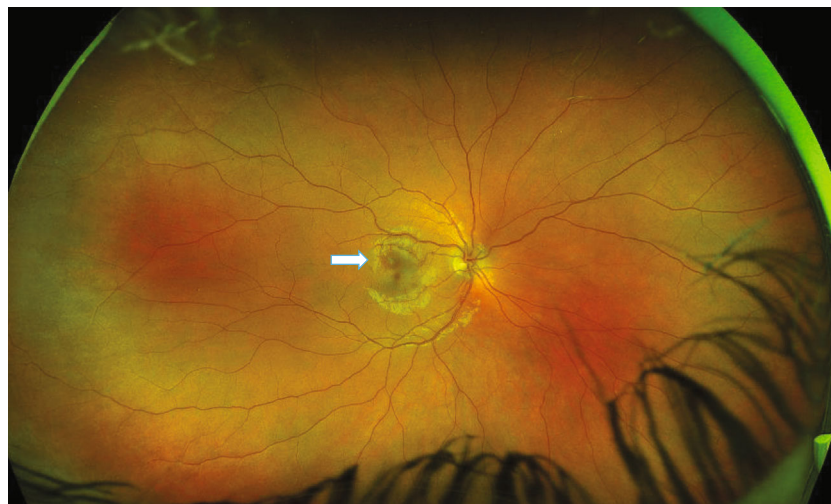


FIGURE 8: Case 2: wide-field retinal image of the right eye—obtained by Optos—showing a dark spot near the fovea.

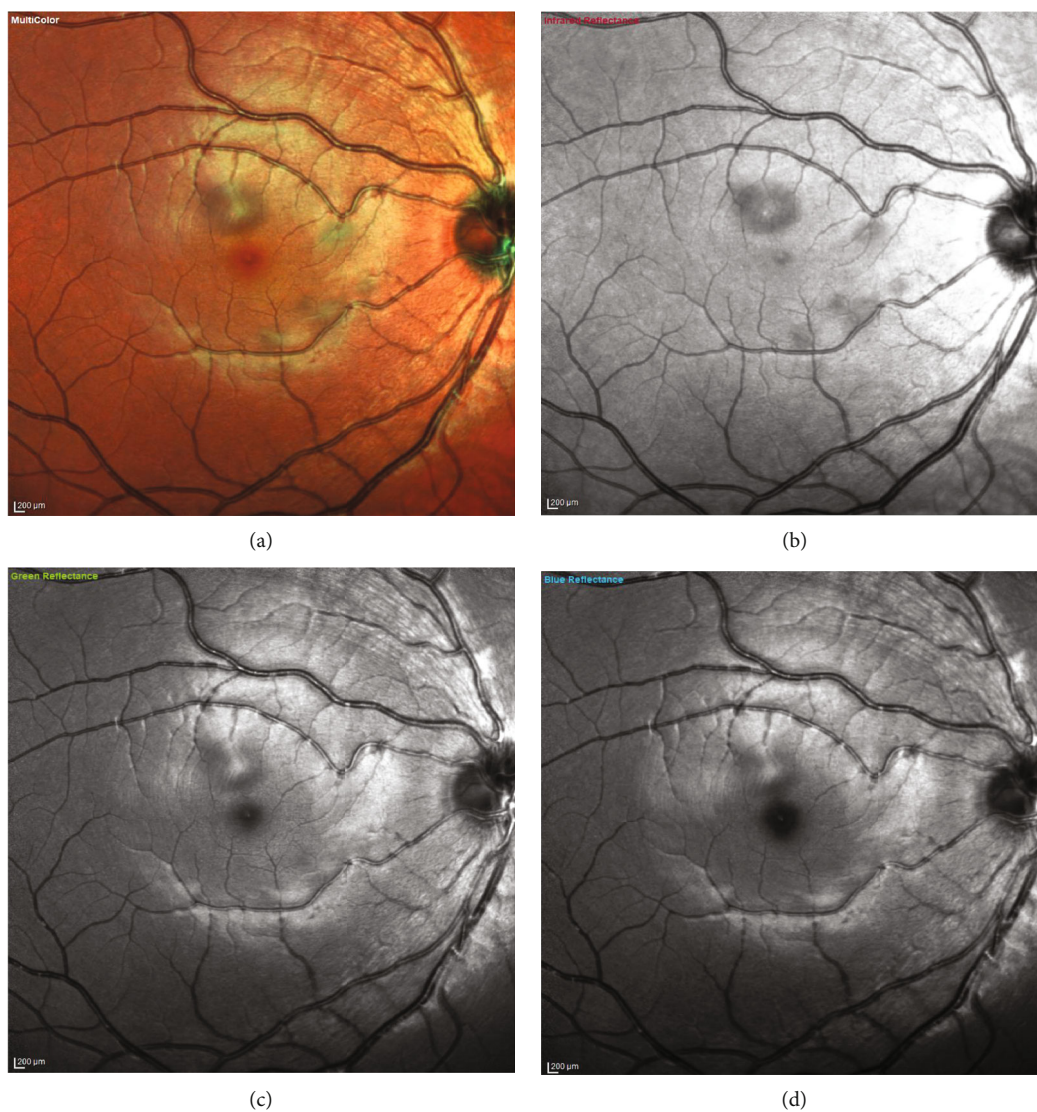


FIGURE 9: Case 2: multispectral fundus imaging of the right eye showing lesions of acute macular neuroretinopathy—(a) multicolor, (b) with infrared reflectance (IR -820 nm), (c) with green reflectance (GR -515 nm), and (d) with blue reflectance (BR -488 nm).

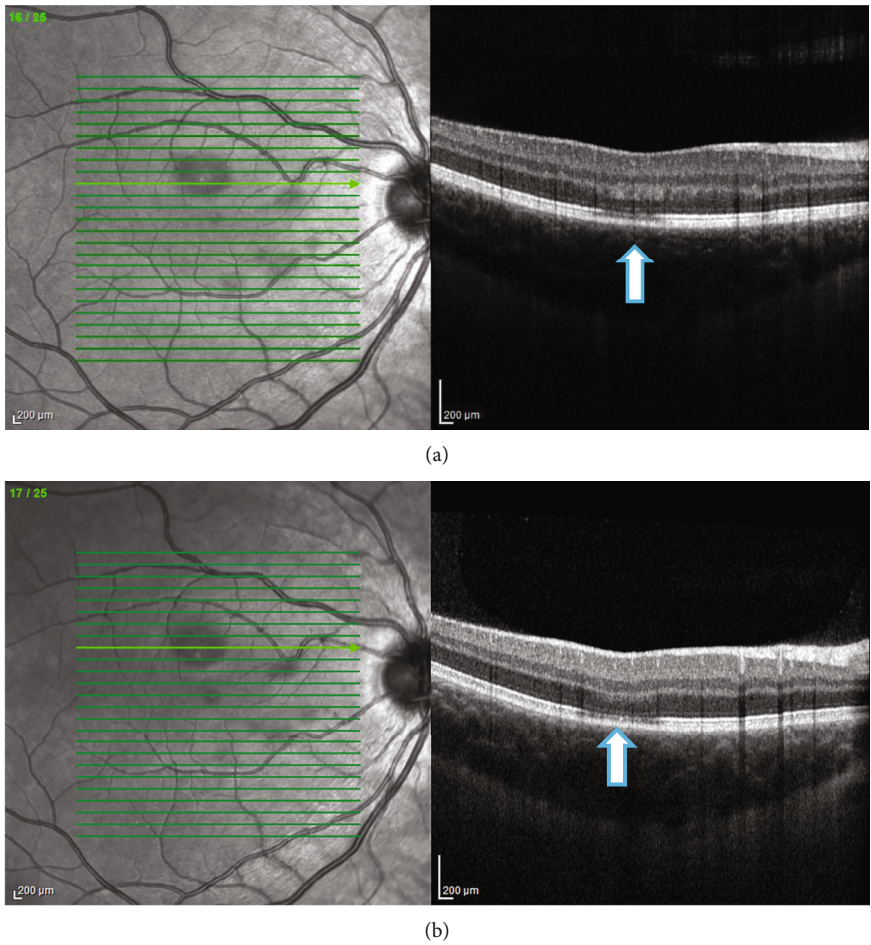


FIGURE 10: (a, b) Case 2: spectral-domain OCT of the right eye showing a patch of hyporeflectivity of the external limiting membrane, the cone ellipsoid zone, and the phagosome zone of retinal pigment epithelium.

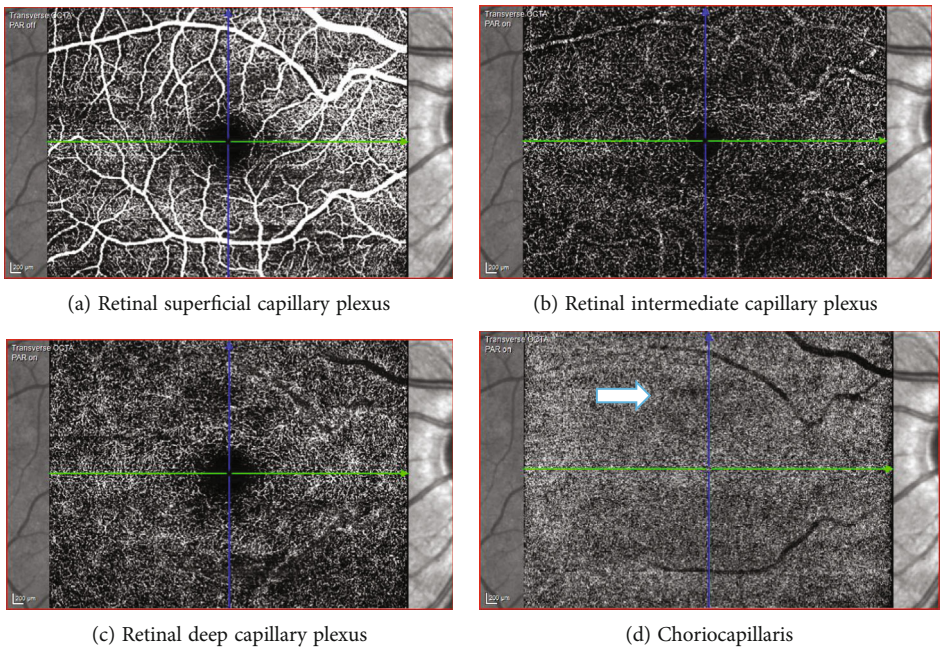


FIGURE 11: Case 2: optical coherence tomography angiography (OCT-A) of the right eye showing a small patch of reduced flow signal in the choriocapillaris.

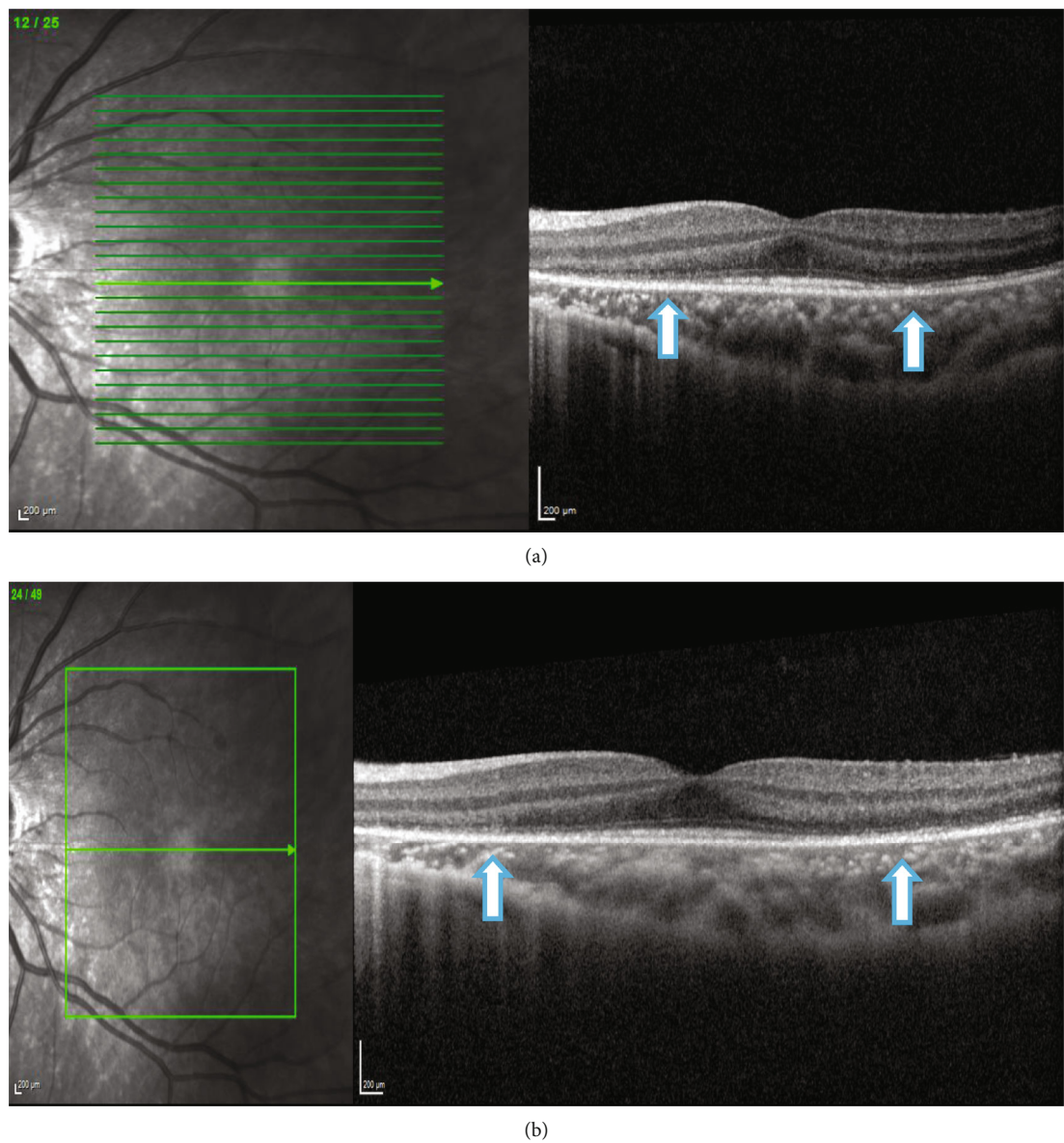


FIGURE 13: Case 3: (a) spectral-domain OCT and (b) enhanced depth imaging of the left eye at presentation, showing left outer retinopathy, with parafoveal loss of ONL, ELM, cone ellipsoid zone, and RPE phagosome zone.

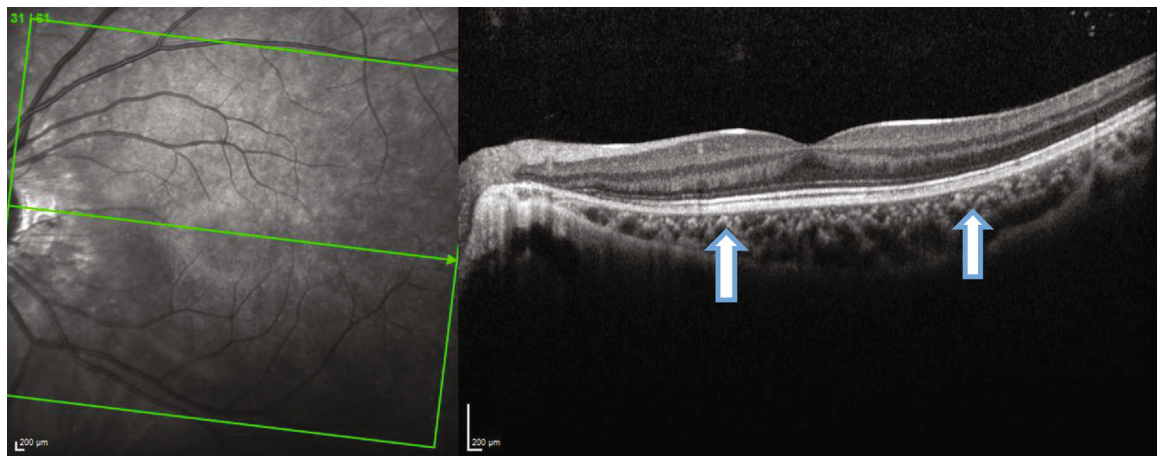


FIGURE 14: Case 3: spectral-domain OCT of the left eye after 3 months, showing restoration of outer retinal layers.

TABLE 1: Summary of the reported cases of acute macular neuroretinopathy, paracentral acute middle maculopathy, and ischemic retinal microvasculopathies associated with COVID-19 infection.

Authors	No. of cases	Age	Gender	Review of literature Duration of ocular signs after COVID-19	Laterality	V/A	OCT	Treatment
David and Fivgas [19]	1	22 years	Female	20 days	BL	6/6	AMNR	Observation
Giacuzzo et al. [20]	1	23 years	Female	14 days	BL		AMNR	Observation
Strzalkowski et al. [21]	1	18 years	Female	21 days	BL		AMNR	Observation
Capuano et al. [22]	1	37 years	Female	First sign of COVID-19	BL		AMNR	Observation
	1	27 years Caucasian	Male	First sign of COVID-19	UL		PAMM	Observation
Azar et al. [23]	1	27 years	Female		BL	6/4.8	AMNR	
	1	28 years	Female		BL	6/6	AMNR	
	1	22 years	Female		UL		AMNR	
	1	21 years	Male		UL	6/60	AMNR	
Masjedi et al. [24]	1	29 years	Female	14 days	UL		AMNR	Observation
Virgo and Mohamed [25]	1	32 years Caucasian	Male	16 days	UL		AMNR	
	1	37 years Caucasian	Female pregnant, GA 14 wk	35 days	UL		PAMM	
Komro et al. [26]	1	34 years	Male	64 days	UL		AMNR	Observation
Jalilink and Bronkhorst [27]	1	21 years	Female	42 days	UL	6/6	AMNR	Observation
	1	29 years	Female	150 days	UL	6/6	AMNR	Observation
Zamani et al. [28]	1	35 years	Female	6 days	UL	6/6	AMNR and AML	Deceased
Aidar et al. [29]	1	71 years	Female	14 days	UL	6/18	AMNR	Observation
Preti et al. [30]	1	70 years	Male	4 days before COVID-19	UL	6/30	AMNR	Observation
El Matri et al. [31]	1	75 years	Female diabetic	90 days	UL		AMNR	Observation
Padhy et al. [32]	1	19 years Indian	Female	14 days	BL	6/12 & 6/38	PAMM, CWS, and raised D-dimer	I/V steroids and enoxaparin
Goyal et al. [33]	1	32 years	Male	120 days	UL		UL ANMR and BL PAMM	Observation
Gascon et al. [34]	1	53 years	Male	8 days	UL	6/19	AMN, PAMM, deep retinal haemorrhages, and Roth spots	
Ortiz-Egea et al. [35]	1	42 years Caucasian	Male	21 days	UL	6/6	Hyper-reflective band at IPL and GCL	
Marinho et al. [36]	12	25-69 years		11-33 days	BL		Hyper-reflective lesions at IPL, GCL, CWS, and haemorrhages	

into the cells is mediated by binding of protein S either to angiotensin-converting enzyme 2 (ACE 2), a specific receptor located on the surface of host cells, or to cluster of differentiation 147 (CD147), a transmembrane glycoprotein. Both ACE 2 receptors and CD147 are expressed in the retina, choroid, and retinal vascular endothelium, facilitating direct virus invasion. SARS-CoV-2 ribonucleic acid (RNA) and proteins S and N have been detected in various layers of the retina, choroid, and optic nerve of the enucleated eyes of COVID-19 patients [9, 14, 15], suggesting that direct virus invasion has a contributory role in the pathogenesis.

It has been observed on OCT-A that macular vascular density measurements in superficial and deep retinal capillary plexus and choriocapillaris were significantly reduced in patients with COVID-19 infection [16–18], which can possibly contribute to increasing the risk of microvascular complications. Our first 2 patients also had localized areas of reduced flow signal in the choriocapillaris contributing to focal ischemia and lesions of outer retinopathy.

COVID-19-related localized retinal or choroidal vessel inflammation results in clinical manifestations in the corresponding layers. COVID-19-related inflammation of the choriocapillaris can cause hypoperfusion and ischemia of the outer retinal layers resulting in AMNR. COVID-19-related inflammation of the retinal intermediate/deep capillary plexus can cause ischemia of the middle retinal layers, INL, and IPL leading to PAMM. In the literature, there are few reported cases of AMNR [19–31] and PAMM [22, 25, 32] associated with COVID-19 infection (Table 1). Goyal et al. [33] and Gascon et al. [34] have reported cases with a combination of both AMNR and PAMM accompanying COVID-19 infection. COVID-19-related inflammation of the retinal superficial capillary plexus can cause ischemia and hyper-reflective bands in the ganglion cell layer (GCL) and nerve fiber layer (NFL) [35, 36].

The incidence of AMNR seems to be increasing since the COVID-19 pandemic and vaccination. In a study from France, Azar et al. studied the cases of AMNR recorded in their hospital in 2019 and 2020 [23]. Eleven cases of AMNR were reported in 2020, during the COVID-19 outbreak. However, only one case of AMNR was documented in 2019, before the pandemic [23].

Regarding the clinical features, all our patients were young females. Our first patient had bilateral AMNR, and others were unilateral. In the literature, the majority of patients with COVID-19-related AMNR were young females with unilateral lesions [23–34], and only a few were bilateral (Table 1) [19–23].

The ocular manifestations can develop after weeks or months after the COVID-19 infection or can be the presenting feature of COVID-19 infection. In our first two patients, the visual symptoms started quite early, within days of the COVID-19 infection. However, our third patient presented late, 3 months after the COVID-19 infection. In literature, retinal signs have been documented varying from 8 to 150 days post-COVID-19 infection (Table 1). It is also known that the COVID-19 virus can persist in tissues for a few months after the infection. Arostegui et al. detected SARS-CoV-2 virions in the colon 3 months after infection [37].

Chertow et al. demonstrated the presence of SARS-CoV-2 RNA in multiple anatomic sites including the brain, for up to 230 days postinfection [38]. Acute macular neuroretinopathy has also been reported as the presenting feature of COVID-19 infection [22, 30].

Our patients were systemically well. Despite the significant visual symptoms and characteristic findings on imaging, our patient's visual acuities were good and were maintained during the follow-up. In the majority of the published cases of COVID-19-related PAMM and AMNR, the vision was good.

Our patients were monitored closely and recovered well. In the literature, majority of the COVID-19-related AMNR and PAMM were managed conservatively with observation only, and only one reported case of PAMM secondary to COVID-19 was treated with IV steroids and enoxaparin due to raised D-dimer levels [32].

In conclusion, COVID-19-related thromboinflammatory response can result in localized vascular inflammation and hypoperfusion in any of the retinal capillary plexuses or choriocapillaris resulting in ischemia of the corresponding retinal or choroidal layers.

Data Availability

The published papers supporting this case report are from previously reported/published case series/case reports which have been cited in the references.

Consent

All 3 patients have consented that their clinical details and scans can be used for publication.

Conflicts of Interest

All the authors declare that there are no conflicts of interest regarding the publication of this article.

References

- [1] D. Cucinotta and M. Vanelli, "WHO declares COVID-19 a pandemic," *Acta Bio Medica: Atenei Parmensis*, vol. 91, no. 1, pp. 157–160, 2020.
- [2] M. Al-Namaeh, "Ocular manifestations of COVID-19," *Therapeutic Advances in Ophthalmology*, vol. 14, article 25158414221083374, 2022.
- [3] L. A. Pereira, L. C. M. Soares, P. A. Nascimento et al., "Retinal findings in hospitalised patients with severe COVID-19," *The British Journal of Ophthalmology*, vol. 106, no. 1, pp. 102–105, 2022.
- [4] R. Lani-Louzada, C. D. V. F. Ramos, R. M. Cordeiro, and A. A. Sadun, "Retinal changes in COVID-19 hospitalized cases," *PLoS One*, vol. 15, no. 12, article e0243346, 2020.
- [5] K. Y. Teo, A. Invernizzi, G. Staurenghi, and C. M. G. Cheung, "COVID-19-related retinal micro-vasculopathy - a review of current evidence," *American Journal of Ophthalmology*, vol. 235, pp. 98–110, 2022.
- [6] A. Daruich, D. Martin, and D. Bremond-Gignac, "Ocular manifestation as first sign of coronavirus disease 2019

- (COVID-19): interest of telemedicine during the pandemic context,” *Journal Français d’Ophtalmologie*, vol. 43, no. 5, pp. 389–391, 2020.
- [7] A. Thanos, L. J. Faia, Y. Yonekawa, and S. Randhawa, “Optical coherence tomographic angiography in acute macular neuroretinopathy,” *JAMA Ophthalmology*, vol. 134, no. 11, pp. 1310–1314, 2016.
 - [8] K. V. Bhavsar, S. Lin, E. Rahimy et al., “Acute macular neuroretinopathy: a comprehensive review of the literature,” *Survey of Ophthalmology*, vol. 61, no. 5, pp. 538–565, 2016.
 - [9] C. A. Araujo-Silva, A. A. Marcos, P. M. Marinho et al., “Presumed SARS-CoV-2 viral particles in the human retina of patients with COVID-19,” *JAMA Ophthalmology*, vol. 139, no. 9, pp. 1015–1021, 2021.
 - [10] G. D. Wool and J. L. Miller, “The impact of COVID-19 disease on platelets and coagulation,” *Pathobiology*, vol. 88, no. 1, pp. 15–27, 2021.
 - [11] W. Miesbach and M. Makris, “COVID-19: coagulopathy, risk of thrombosis, and the rationale for anticoagulation,” *Clinical and Applied Thrombosis/Hemostasis*, vol. 26, article 1076029620938149, 2020.
 - [12] S. X. Gu, T. Tyagi, K. Jain et al., “Thrombocytopenia and endotheliopathy: crucial contributors to COVID-19 thromboinflammation,” *Nature Reviews Cardiology*, vol. 18, no. 3, pp. 194–209, 2021.
 - [13] T. Iba, J. M. Connors, and J. H. Levy, “The coagulopathy, endotheliopathy, and vasculitis of COVID-19,” *Inflammation Research*, vol. 69, no. 12, pp. 1181–1189, 2020.
 - [14] M. Casagrande, A. Fitzek, M. Spitzer et al., “Detection of SARS-CoV-2 genomic and subgenomic RNA in retina and optic nerve of patients with COVID-19,” *British Journal of Ophthalmology*, vol. 106, no. 9, pp. 1313–1317, 2022.
 - [15] M. Casagrande, A. Fitzek, K. Püschel et al., “Detection of SARS-CoV-2 in human retinal biopsies of deceased COVID-19 patients,” *Ocular Immunology and Inflammation*, vol. 28, no. 5, pp. 721–725, 2020.
 - [16] T. Cetinkaya, M. M. Kurt, and C. Akpolat, “Analysis of swept-source optical coherence tomography angiography measurement alterations in adult patients recovered from COVID-19,” *Clinical & Experimental Optometry*, vol. 7, pp. 1–5, 2022.
 - [17] I. C. Turker, C. U. Dogan, D. Guven, O. K. Kutucu, and C. Gul, “Optical coherence tomography angiography findings in patients with COVID-19,” *Canadian Journal of Ophthalmology*, vol. 56, no. 2, pp. 83–87, 2021.
 - [18] M. Abrishami, K. Hassanpour, S. Hosseini et al., “Macular vessel density reduction in patients recovered from COVID-19: a longitudinal optical coherence tomography angiography study,” *Graefes Archive for Clinical and Experimental Ophthalmology*, vol. 260, no. 3, pp. 771–779, 2022.
 - [19] J. A. David and G. D. Fivgas, “Acute macular neuroretinopathy associated with COVID-19 infection,” *American Journal of Ophthalmology Case Reports*, vol. 24, article 101232, 2021.
 - [20] C. Giacuzzo, C. M. Eandi, and A. Kawasaki, “Bilateral acute macular neuroretinopathy following COVID-19 infection,” *Acta Ophthalmologica*, vol. 100, no. 2, pp. e611–e612, 2022.
 - [21] P. Strzalkowski, J. S. Steinberg, and S. Dithmar, “COVID-19-assoziierte akute makuläre Neuroretinopathie,” *Die Ophthalmologie*, vol. 120, no. 7, pp. 767–770, 2023.
 - [22] V. Capuano, P. Forte, R. Sacconi et al., “Acute macular neuroretinopathy as the first stage of SARS-CoV-2 infection,” *European Journal of Ophthalmology*, vol. 33, no. 3, pp. NP105–NP111, 2023.
 - [23] G. Azar, S. Bonnin, V. Vasseur et al., “Did the COVID-19 pandemic increase the incidence of acute macular neuroretinopathy?,” *Journal of Clinical Medicine*, vol. 10, no. 21, p. 5038, 2021.
 - [24] M. Masjedi, M. Pourazizi, and N. S. Hosseini, “Acute macular neuroretinopathy as a manifestation of coronavirus disease 2019: a case report,” *Clinical Case Reports*, vol. 9, no. 10, article e04976, 2021.
 - [25] J. Virgo and M. Mohamed, “Paracentral acute middle maculopathy and acute macular neuroretinopathy following SARS-CoV-2 infection,” *Eye*, vol. 34, no. 12, pp. 2352–2353, 2020.
 - [26] J. Komro, J. D. Bogaard, and C. C. Warren, “Acute macular neuroretinopathy as a manifestation of Covid-19,” *Ophthalmology Case Reports*, vol. 5, no. 1, pp. 96–103, 2021.
 - [27] M. B. Jalink and I. H. G. Bronkhorst, “A sudden rise of patients with acute macular neuroretinopathy during the COVID-19 pandemic,” *Case Reports in Ophthalmology*, vol. 13, no. 1, pp. 96–103, 2022.
 - [28] G. Zamani, S. Ataei Azimi, A. Aminizadeh et al., “Acute macular neuroretinopathy in a patient with acute myeloid leukemia and deceased by COVID-19: a case report,” *Journal of Ophthalmic Inflammation and Infection*, vol. 10, no. 1, p. 39, 2021.
 - [29] M. N. Aidar, T. M. Gomes, M. Z. H. de Almeida, E. P. de Andrade, and P. D. Serracarbassa, “Low visual acuity due to acute macular neuroretinopathy associated with COVID-19: a case report,” *The American Journal of Case Reports*, vol. 22, article e931169, 2021.
 - [30] R. C. Preti, L. C. Zacharias, L. P. Cunha, and M. L. R. Monteiro, “Acute macular neuroretinopathy as the presenting manifestation of COVID-19 infection,” *Retinal Cases & Brief Reports*, vol. 16, no. 1, pp. 12–15, 2022.
 - [31] K. El Matri, S. Werda, A. Chebil et al., “Acute macular outer retinopathy as a presumed manifestation of COVID-19,” *Journal Français d’Ophtalmologie*, vol. 44, no. 8, pp. 1274–1277, 2021.
 - [32] S. K. Padhy, R. P. Dcruz, and A. Kelgaonkar, “Paracentral acute middle maculopathy following SARS-CoV-2 infection: the D-dimer hypothesis,” *BMJ Case Reports*, vol. 14, no. 3, article e242043, 2021.
 - [33] M. Goyal, S. I. Murthy, and S. Annum, “Retinal manifestations in patients following COVID-19 infection: a consecutive case series,” *Indian Journal of Ophthalmology*, vol. 69, no. 5, pp. 1275–1282, 2021.
 - [34] P. Gascon, A. Briantais, E. Bertrand et al., “Covid-19-associated retinopathy: a case report,” *Ocular Immunology and Inflammation*, vol. 28, no. 8, pp. 1293–1297, 2020.
 - [35] J. M. Ortiz-Egea, J. Ruiz-Medrano, and J. M. Ruiz-Moreno, “Retinal imaging study diagnoses in COVID-19: a case report,” *Journal of Medical Case Reports*, vol. 15, no. 1, p. 15, 2021.
 - [36] P. M. Marinho, A. A. A. Marcos, A. C. Romano, H. Nascimento, and R. Belfort Jr., “Retinal findings in patients with COVID-19,” *Lancet*, vol. 395, no. 10237, p. 1610, 2020.
 - [37] D. Arostegui, K. Castro, S. Schwarz, K. Vaidy, S. Rabinowitz, and T. Wallach, “Persistent SARS-CoV-2 nucleocapsid protein presence in the intestinal epithelium of a pediatric patient 3 months after acute infection,” *JPGN Reports*, vol. 3, no. 1, article e152, 2022.
 - [38] D. Chertow, S. Stein, S. Ramelli et al., “SARS-CoV-2 infection and persistence throughout the human body and brain,” *Research Square*, 2021.