

## Case Report

# Simultaneous Bilateral Quadriceps Tendon Rupture following Long-Term Low-Dose Nasal Corticosteroid Application

**Mohamed Omar, Philipp Haas, Max Ettinger, Christian Krettek, and Maximilian Petri**

*Trauma Department, Hannover Medical School, Carl-Neuberg-Straße 1, 30625 Hannover, Germany*

Correspondence should be addressed to Mohamed Omar; [omar.mohamed@mh-hannover.de](mailto:omar.mohamed@mh-hannover.de)

Received 10 June 2013; Accepted 14 July 2013

Academic Editors: M. Cadossi, T. Ito, M. G. Lykissas, and M. Massobrio

Copyright © 2013 Mohamed Omar et al. This is an open access article distributed under the Creative Commons Attribution License, which permits unrestricted use, distribution, and reproduction in any medium, provided the original work is properly cited.

Simultaneous bilateral quadriceps tendon rupture is a very rare injury, which was previously only described in slightly more than 100 cases in the English literature. Occurrence after minor trauma is predominantly associated with certain medical conditions including chronic diseases and long-term use of certain drugs. We report the case of a 61-year-old healthy patient who sustained a simultaneous bilateral quadriceps tendon rupture following minor trauma. Medical history was completely clear except of a long-term nasal corticosteroid medication due to allergic rhinitis.

## 1. Introduction

Quadriceps tendon rupture predominantly occurs after major trauma in younger patients or as the result of tendon weakening due to obesity and arteriosclerosis-induced fibrotic changes or previous injury [1].

Simultaneous bilateral quadriceps tendons rupture is a very rare injury. Since the first description by Steiner and Plamer [2], only slightly more than 100 cases were reported in the English literature. It mostly occurs in patients with chronic diseases including chronic renal failures [3], hyperparathyroidism [1], gout, systemic lupus erythematosus [4], and long-term use of drugs such as quinolones, statins [5], and anabolic steroids [6].

Corticosteroid application is known to produce a variety of adverse effects including the induction of apoptosis of tendon cells resulting in partial or complete rupturing [7]. This effect is very well described following local and systemic medication [8, 9]. However, adverse effects resulting in quadriceps tendon rupture following nasal application of corticosteroids have not been found yet [10]. According to Blanco et al. [11], singular cases of Achilles tendon ruptures and tendinopathies after topical application (e.g. inhalation, nasal, and cutaneous) were reported.

We report the case of a 61-year-old healthy man who sustained simultaneous bilateral quadriceps tendons rupture

after a minor trauma. Long-term low-dose nasal application of a corticosteroid due to an allergic rhinitis was identified as exclusive predisposing factor.

## 2. Case Presentation

A 61-year-old man was admitted to our emergency department who stumbled and consequently fell on both knees. The patient heard loud cracks as he touched the ground. Immediately after the trauma, he was not able to bear weight and collapsed due to giving way of both knees.

The patient was retired and did not perform heavy labour throughout his life. He was regularly performing sportive activities including swimming and cycling. Medical history was completely clear except of daily use of a nasal corticosteroid (mometasone-17-2-furoate) in a concentration of 300  $\mu\text{m}$  per day for two years due to allergic rhinitis. The patient declined the use of any other medications, especially those that are known to be associated to tendon ruptures. There was no history of tendon or joint pathology before steroid treatment.

On physical examination, there was oedematous swelling and hematoma in the suprapatellar region as well as intra-articular effusion of both knees. There was no skin affection. Palpation did not reveal osseous disruption of the patella.

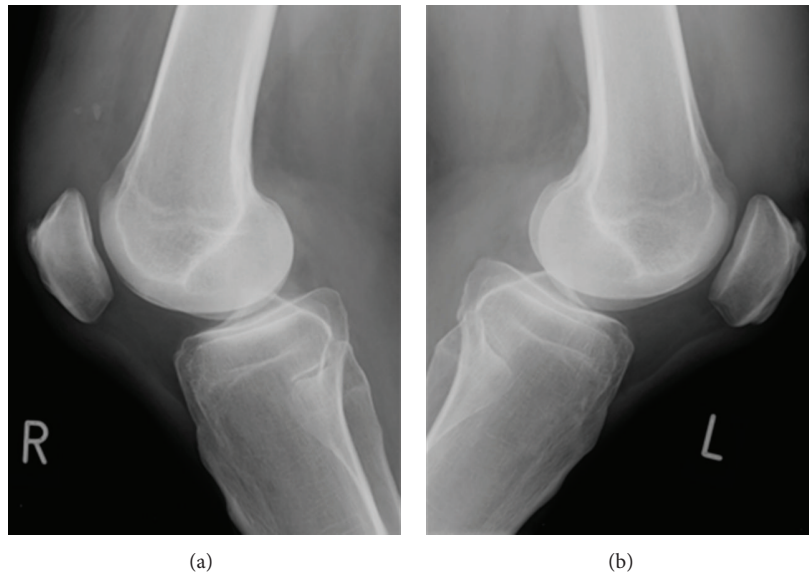


FIGURE 1: Plain radiographies show low riding of both patellae and signs of suprapatellar ossification of the right knee.

In the suprapatellar region of both quadriceps tendons, soft tenderness was palpable. Patellae showed increased instability for lateral, medial, and distal, but not for cranial, shifting indicating intact patellar ligaments. Quadriceps contraction did not result in movement of the patellae. The patient was unable to actively extend his legs or to lift the extended legs. There was full range of motion and muscle strength for active flexion of the knees. Neurologic and neurovascular examinations were normal.

Plain radiography showed low riding of both patellae and signs of suprapatellar ossification of the right knee indicating pretraumatic degeneration as illustrated in Figure 1.

In sonographic examination, a complete disruption of the quadriceps tendon at the patella insertion sites was revealed. The patient was operated two days after injury. Ruptured tendons were exposed through a median approach. A full-thickness rupture was observed at the insertion site of the superior patellar aspect on the right leg as shown in Figure 2. The left side showed a full-thickness intratendinous tear of the quadriceps tendon 3 cm proximal to its insertion point at the patella.

The stumps were trimmed and stitched through transosseous sutures using a 2.5 mm drill and a fibre wire with a double row Bunnell technique. Postoperative radiography showed regular positioning of the patellae as illustrated in Figure 3.

Using a range-of-motion brace, knee flexion was postoperatively limited to 60 degrees for three weeks following another period of three weeks with flexion limitation of 90 degrees. The patient was not allowed to perform weight bearing for the time of knee flexion limitation. After 6 weeks, the patient was able to do full weight bearing. There was an extension lag of 10° at the right side and 15° at the left side as shown in Figure 4.

### 3. Discussion

The quadriceps femoris muscle is the largest muscle in humans and primary performs extension of the knee. The muscle inserts to the tibial tuberosity through the patella and patella ligament. The quadriceps tendon is attached to the superior aspect of the patella. It can resist considerable loads. It could be demonstrated that approximately 50% of a healthy tendon's tissues have to be severed to result in rupturing. Quadriceps tendon rupture can occur by direct or indirect mechanisms. Most traumas involve eccentric contraction while weight bearing in a partially flexed position of the knee [12].

Typical history, trauma mechanism, and evaluation of the risk factors can lead to the diagnosis. The trias of symptoms with painful swelling, palpable suprapatellar gap, and the inability to actively extend the knee is not obligatory and only found in about 60% of patients [13]. Plain radiographs reveal only indirect signs of the lesion including intraarticular swelling, shadow in the tendon line, patellar spurs at the tendons insertion, and low riding and forward tilting of the patella. In case of systemic diseases or degeneration, suprapatellar calcifications due to bony transformation can be observed [5]. Ultrasound and magnetic resonance imaging can directly prove the rupture as they visualize the soft tissue.

Quadriceps tendon rupture is a common injury of the knee after major trauma in younger patients. In elderly patients, rupture is the result of tendon weakening due to obesity and arteriosclerosis-induced fibrotic changes or previous injury [1]. Bilateral and simultaneous rupture is a rarity. Since the first description by Steiner and Plamer [2], only slightly more than 100 cases were reported in the English literature. Bilateral ruptures are generally associated with chronic diseases including chronic renal failures [3], hyperparathyroidism, gout, systemic lupus erythematosus [4],

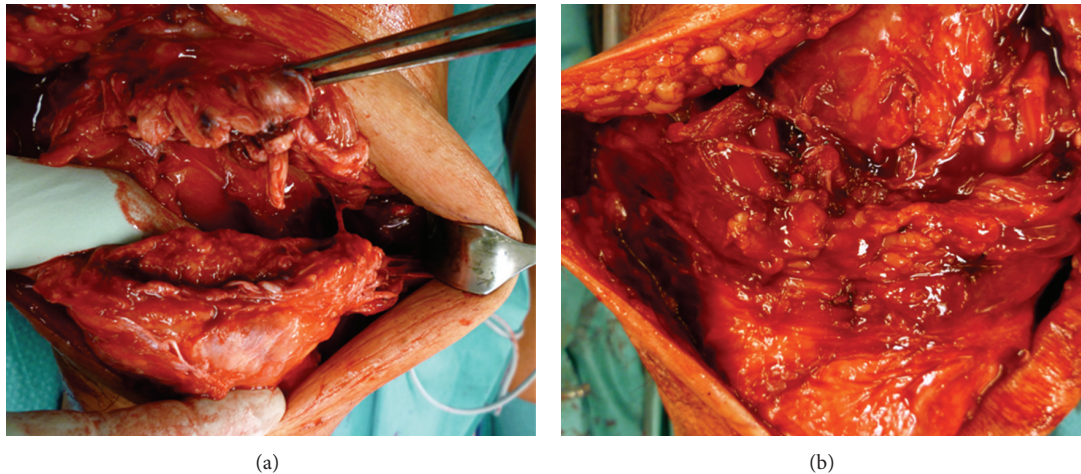


FIGURE 2: Intraoperative pictures of the ruptured quadriceps tendons. On the right side (a), the rupture is directly at the insertion site of the tendon to the suprapatellar aspect while an intratendinous rupture is apparent on the left side (b).

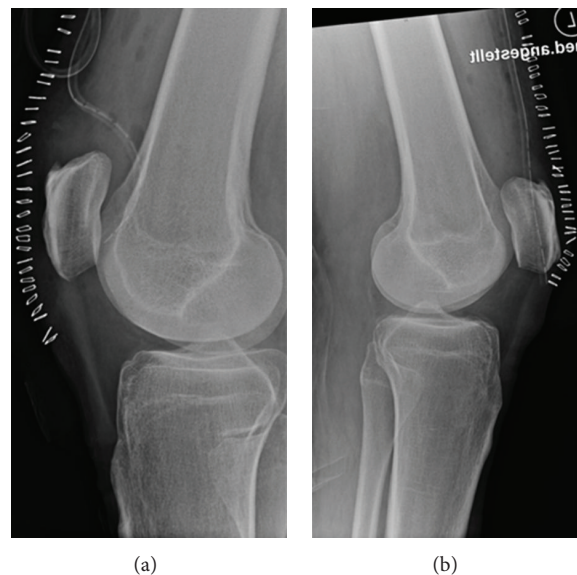


FIGURE 3: Postoperative radiographies demonstrate regular positioning of the patellae.

or long-term use of drugs such as quinolones, statins [14], and anabolic steroids [6].

Tendon rupture following corticosteroid medication is very well described. Systemic and local application of corticosteroids is known to generate a variety of adverse effects. These include growth inhibition induced by hypothalamus-pituitary-adrenal (HPA) axis suppression, decreased bone mineral density, myopathy, cataract, glaucoma, hypertension, hyperglycemia, and skin affections [15].

The occurrence of tendon ruptures and impaired tendon healing following systemic or local corticosteroid usage have been described previously. Newnham et al. [9] and Kotnis et al. [8] reported atraumatic ruptures of Achilles tendon in patients with respiratory diseases treated with systemic

corticosteroids. The relation between local corticosteroid application and tendon rupture could be demonstrated by Nguyen and Jones [16] who observed the rupture of both the abductor pollicis longus and extensor pollicis brevis tendons after repetitive steroid injection for treatment of de Quervain tenosynovitis. Although the mechanism is not elucidated in detail, it is assumed that steroids suppress the repair of partially ruptured or degenerated tendons. Therefore, minor trauma can easily lead to complete rupture of the already damaged tendon. These findings are supported by in vitro observations of Hossain et al. [7] who could demonstrate that increasing concentrations of corticosteroids inhibit the proliferation and induce apoptosis of cultivated canine tendon cells.

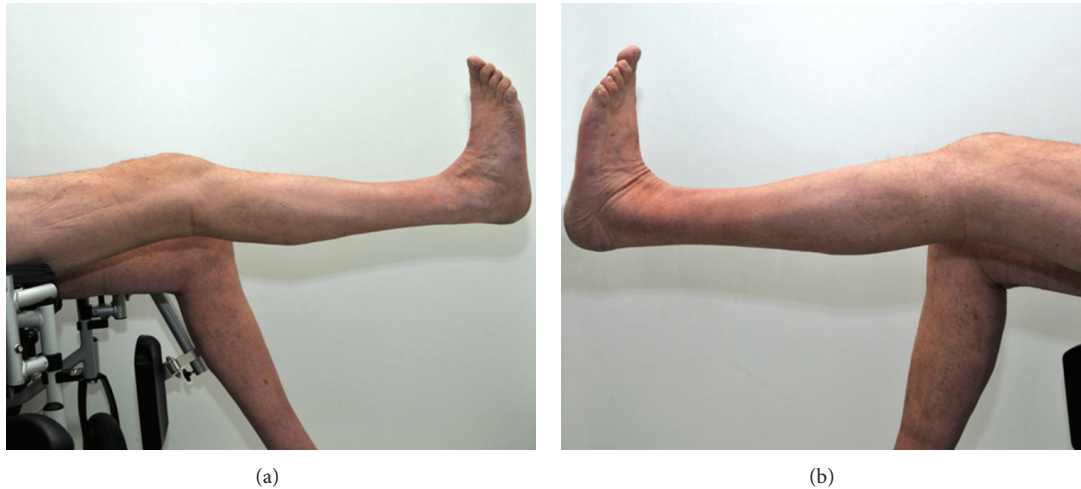


FIGURE 4: Six weeks following tendon suturing, the patient was able to extend the knee actively. However, there was an extension lag of  $10^{\circ}$  at the right side (a) and  $15^{\circ}$  at the left side (b).

In our case, there was no history for local or systemic corticosteroid usage. Moreover, no joint or tendon pathologies have been reported before the accident. The suprapatellar calcification in the right knee was the only evidence for pretraumatic degeneration as a possible result of a chronic corticosteroid medication. Corticosteroids are known to exert their negative effect on bone metabolism by altering both calcium homeostasis and sex hormone production [17]. Suprapatellar calcifications are not exclusive for corticosteroid medication, but the occurrence of calcifications may be a sign of corticosteroid associated adverse effects. Apart from that, the patient did not show any noticeable medical conditions. He was a healthy 61-year-old man who regularly performed endurance activities like cycling and swimming known not to be stressful for tendons. He never had any tendinopathies or injuries of the musculoskeletal system. The patient sustained bilateral quadriceps rupture after a minor trauma as he stumbled and fell on both knees. As discussed earlier, the trauma mechanism is not typical for quadriceps tendon rupture. As the incidence of bilateral quadriceps tendon ruptures without any underlying risk factors is very low [18], we assumed that the corticosteroid medication could play a certain role.

The long-term use of nasal mometasone in a concentration of  $300\ \mu\text{g}$  per day for two years appeared to be the exclusive risk factor. However, as reviewed in detail by Sastre and Mosges [10], nasal steroid application has been shown to be safe and in first line leads to local adverse effects including nasal irritation and epistaxis. In many studies, it could be demonstrated that nasal corticosteroid does not alter the concentration of blood cortisol level. However, certain amounts reach systemic circulation, and adverse effects are therefore considerable. Although rarely reported, there were singular cases of tendinopathies after topical (i.e., ocular, cutaneous, and nasal) corticosteroid use [11]. These cases predominantly consisted of Achilles tendon

ruptures and in a minority of cases of tendinitis or an unspecified tendon disorder. Tendinopathies or even ruptures of the quadriceps tendons after topical corticosteroid medication have not been described yet.

Although nasal application of corticosteroids seems to be safe, in a minority of cases adverse systemic effects have been reported. This is the first case to demonstrate a possible relation between bilateral quadriceps tendon ruptures after a minor trauma and long-term use of nasal corticosteroids. Further investigations are required to prove this assumption. However, as corticosteroids in general are known to generate adverse effects on tendons, topic application should be taken into consideration as potential risk factor for tendinopathies.

## Disclosure

The authors declare that they have no conflict of interests. The patient gave his informed consent to the publication of the paper including all images.

## Acknowledgments

The authors acknowledge the support for the publication fee by the DFG Deutsche Forschungsgemeinschaft and the Open Access Publications Fund of Medizinische Hochschule Hannover (MHH).

## References

- [1] M. Thauat, P. Gaudin, C. Naret, P. Beaufile, and O. Thauat, "Role of secondary hyperparathyroidism in spontaneous rupture of the quadriceps tendon complicating chronic renal failure," *Rheumatology*, vol. 45, no. 2, pp. 234–235, 2006.
- [2] C. A. Steiner and L. H. Palmer, "Simultaneous bilateral rupture of the quadriceps tendon," *The American Journal of Surgery*, vol. 78, no. 5, pp. 752–755, 1949.

- [3] B. S. Kim, Y. W. Kim, E. K. Song, J. K. Seon, K. D. Kang, and H. N. Kim, "Simultaneous bilateral quadriceps tendon rupture in a patient with chronic renal failure," *Knee Surgery & Related Research*, vol. 24, pp. 56–59, 2012.
- [4] I. Potasman and H. M. Bassan, "Multiple tendon rupture in systemic lupus erythematosus: case report and review of the literature," *Annals of the Rheumatic Diseases*, vol. 43, no. 2, pp. 347–349, 1984.
- [5] E. Calvo, A. Ferrer, A. G. Robledo, L. Alvarez, F. Castillo, and C. Vallejo, "Bilateral simultaneous spontaneous quadriceps tendons rupture. A case report studied by magnetic resonance imaging," *Clinical Imaging*, vol. 21, no. 1, pp. 73–76, 1997.
- [6] R. L. Y. Liow and S. Tavares, "Bilateral rupture of the quadriceps tendon associated with anabolic steroids," *British Journal of Sports Medicine*, vol. 29, no. 2, pp. 77–79, 1995.
- [7] M. A. Hossain, J. Park, S. H. Choi, and G. Kim, "Dexamethasone induces apoptosis in proliferative canine tendon cells and chondrocytes," *Veterinary and Comparative Orthopaedics and Traumatology*, vol. 21, no. 4, pp. 337–342, 2008.
- [8] R. A. Kotnis, J. C. Halstead, and P. J. Hormbrey, "Atraumatic bilateral Achilles tendon rupture: an association of systemic steroid treatment," *Journal of Accident and Emergency Medicine*, vol. 16, no. 5, pp. 378–379, 1999.
- [9] D. M. Newnham, J. G. Douglas, J. S. Legge, and J. A. R. Friend, "Achilles tendon rupture: an underrated complication of corticosteroid treatment," *Thorax*, vol. 46, no. 11, pp. 853–854, 1991.
- [10] J. Sastre and R. Mosges, "Local and systemic safety of intranasal corticosteroids," *Journal of Investigational Allergology and Clinical Immunology*, vol. 22, no. 1, pp. 1–12, 2012.
- [11] I. Blanco, S. K. Uhl, and R. G. Schlienger, "Corticosteroid-associated tendinopathies: an analysis of the published literature and spontaneous pharmacovigilance data," *Drug Safety*, vol. 28, no. 7, pp. 633–643, 2005.
- [12] A. G. MacEachern and J. L. Plewes, "Bilateral simultaneous spontaneous rupture of the quadriceps tendons," *Journal of Bone and Joint Surgery. British*, vol. 66, no. 1, pp. 81–83, 1984.
- [13] D. I. Ilan, N. Tejwani, M. Keschner, and M. Leibman, "Quadriceps tendon rupture," *The Journal of the American Academy of Orthopaedic Surgeons*, vol. 11, no. 3, pp. 192–200, 2003.
- [14] E. C. Celik, M. Ozbaydar, D. Ofluoglu, and E. Demircay, "Simultaneous and spontaneous bilateral quadriceps tendons rupture," *American Journal of Physical Medicine & Rehabilitation*, vol. 91, no. 7, pp. 631–634, 2012.
- [15] M. Zitt, T. Kosoglou, and J. Hubbell, "Mometasone furoate nasal spray: a review of safety and systemic effects," *Drug Safety*, vol. 30, no. 4, pp. 317–326, 2007.
- [16] M. L. Nguyen and N. F. Jones, "Rupture of both the abductor pollicis longus and extensor pollicis brevis tendons after steroid injection for de quervain tenosynovitis," *Plastic and Reconstructive Surgery*, vol. 129, pp. 883e–886e, 2012.
- [17] D. B. Allen, "Systemic effects of intranasal steroids: an endocrinologist's perspective," *Journal of Allergy and Clinical Immunology*, vol. 106, no. 4, pp. S179–S190, 2000.
- [18] R. S. Bikkina, G. Chaljub, H. Singh, and S. D. Allen, "Magnetic resonance imaging of simultaneous bilateral quadriceps tendon rupture in a weightlifter: case report," *Journal of Trauma*, vol. 52, no. 3, pp. 582–584, 2002.



**Hindawi**  
Submit your manuscripts at  
<http://www.hindawi.com>

