

## Case Report

# Dysphagia due to Diffuse Idiopathic Skeletal Hyperostosis

**Masafumi Ohki**

*Department of Otolaryngology, Saitama Medical Center, 1981 Kamoda, Kawagoe-shi, Saitama 350-8550, Japan*

Correspondence should be addressed to Masafumi Ohki, m-ohki@umin.ac.jp

Received 15 December 2011; Accepted 2 February 2012

Academic Editors: S. Ulualp and L.-F. Wang

Copyright © 2012 Masafumi Ohki. This is an open access article distributed under the Creative Commons Attribution License, which permits unrestricted use, distribution, and reproduction in any medium, provided the original work is properly cited.

Diffuse idiopathic skeletal hyperostosis (DISH) is usually asymptomatic. However, rarely, it causes dysphagia, hoarseness, dyspnea, snoring, stridor, and laryngeal edema. Herein, we present a patient with DISH causing dysphagia. A 70-year-old man presented with a 4-month history of sore throat, dysphagia, and foreign body sensation. Flexible laryngoscopy revealed a leftward-protruding posterior wall in the hypopharynx. Computed tomography and magnetic resonance imaging revealed a bony mass pushing, anteriorly, on the posterior hypopharyngeal wall. Ossification included an osseous bridge involving 5 contiguous vertebral bodies. Dysphagia due to DISH was diagnosed. His symptoms were relieved by conservative therapy using anti-inflammatory drugs. However, if conservative therapy fails and symptoms are severe, surgical treatments must be considered.

## 1. Introduction

Diffuse idiopathic skeletal hyperostosis (DISH) is a disease characterized by massive, noninflammatory ossification with intensive formation of osteophytes affecting ligaments, tendons, and fascia of the anterior part of the spinal column, mostly in the middle and lower thoracic regions [1, 2]. It is called Forestier disease as Forestier was the first to report this disorder [1]. The defining criteria include ossification forming an osseous bridge involving at least 4 contiguous vertebral bodies [2]. Ossification can occur in the cervical region as well. It is mainly an asymptomatic disorder in elderly persons. However, DISH in the cervical region can, in rare cases, cause dysphagia [3]. We herein report a rare case of dysphagia associated with DISH.

## 2. Case

A 70-year-old man presented with a 4-month history of sore throat, dysphagia, and foreign body sensation. Flexible laryngoscopy revealed a left-sided protrusion in the posterior hypopharyngeal wall (Figure 1(a)). The surface of the protruding wall was smooth and intact, and the protruding mass was hard. Vocal cord mobility was normal. The left piriform sinus of the hypopharynx was narrowed by the protruding wall and saliva pooled within it. Axial computed tomography

(CT) (Figure 1(b)) and magnetic resonance imaging (MRI) (Figures 1(c) and 1(d)) of the neck showed a bony mass pushing, anteriorly, the posterior wall of the hypopharynx suggesting dysphagia associated with DISH. One month after starting carbocisteine at 1500 mg and lysozyme hydrochloride 90 mg daily, his symptoms of sore throat and foreign body sensation showed relief. The saliva pooling in the piriform sinus was decreased.

## 3. Discussion

The proposed mechanisms of dysphagia in DISH include mechanical compression, periesopharyngeal inflammation with edema and fibrosis due to chronic irritation, and cricopharyngeal spasm also due to chronic irritation [4–6]. A bolus is blocked at the piriform sinus. Limited mobility of the epiglottis and elevation of the larynx cause dysphagia as well as aspiration. The narrowed airway causes dyspnea [7–10]. Retrocricoid inflammation can induce laryngeal edema [11], dysphonia, vocal cord immobility [12, 13], or stridor [7]. We first applied conservative therapy, that is, anti-inflammatory drugs, muscle relaxants, and so on. Only when symptoms are severe, that is, aphagia, appearance of neurological signs such as compression (myelopathy) [14, 15] or obstruction of the airway [8–10], is surgical treatment indicated. Surgery is performed mainly via the anterior (Smith-Robinson approach)

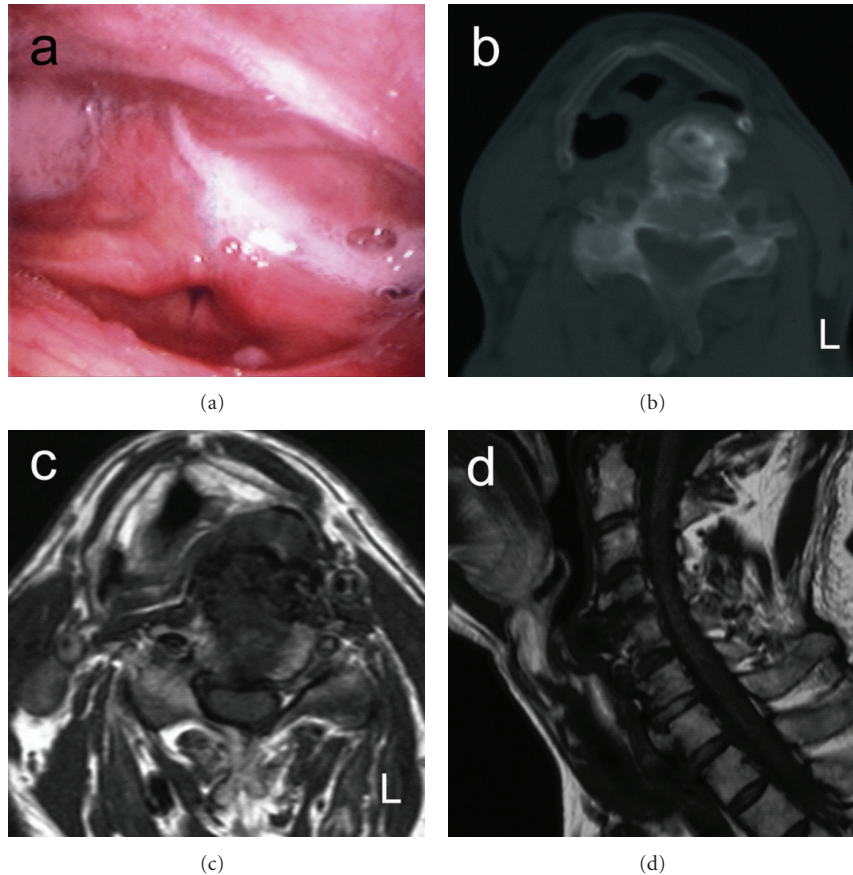


FIGURE 1: (a) a hard mass protruding in the posterior hypopharyngeal wall. (b) CT scan shows a bony mass pushing the posterior piriform sinus wall anteriorly. (c) Axial T1 weighted-MRI shows a mass pushing the posterior piriform sinus wall anteriorly. (d) sagittal T1 weighted-MRI shows an anterior mass of the cervical spine from C4 to T1.

[16, 17] and transpharyngeal approaches [17, 18]. However, we must be aware of potentially severe complications of surgical treatment such as hematoma, Horner syndrome, recurrent nerve palsy, superior laryngeal nerve palsy, and esophageal injury [19]. The anterior approach carries a risk of dysphonia or dysphagia, at rates of 38% and 23%, respectively, for more than 6 months after surgery [16]. Therefore, surgical treatment should be selected with care.

#### 4. Conclusion

Dysphagia due to DISH is rare. CT or MRI is useful for diagnosing DISH. Although conservative therapy and surgical treatments are available, surgery carries severe potential risks. Conservative therapy is recommended first and surgical treatment is considered only if conservative therapy fails and symptoms are severe.

#### References

- [1] J. Forestier and J. Rotes-Querol, "Senile ankylosing hyperostosis of the spine," *Annals of the Rheumatic Diseases*, vol. 9, no. 4, pp. 321–330, 1950.
- [2] D. Resnick, S. R. Shaul, and J. M. Robins, "Diffuse idiopathic skeletal hyperostosis (DISH): Forestier's disease with extraspinal manifestations," *Radiology*, vol. 115, no. 3, pp. 513–524, 1975.
- [3] M. J. Carlson, R. N. Stauffer, and W. Spencer Payne, "Ankylosing vertebral hyperostosis causing dysphagia," *Archives of Surgery*, vol. 109, no. 4, pp. 567–570, 1974.
- [4] T. O. Seidler, J. C. Pérez Álvarez, K. Wonneberger, and T. Hacki, "Dysphagia caused by ventral osteophytes of the cervical spine: clinical and radiographic findings," *European Archives of Oto-Rhino-Laryngology*, vol. 266, no. 2, pp. 285–291, 2009.
- [5] P. Lecerf and O. Malard, "How to diagnose and treat symptomatic anterior cervical osteophytes?" *European Annals of Otorhinolaryngology, Head and Neck Diseases*, vol. 127, no. 3, pp. 111–116, 2010.
- [6] A. Di Martino, V. Costa, and V. Denaro, "Dysphagia and dysphonia due to anterior cervical osteophytes: report of a patient affected by DISH," *European Journal of Orthopaedic Surgery and Traumatology*, vol. 16, no. 4, pp. 344–347, 2006.
- [7] K. Papakostas, A. Thakar, V. Nandapalan, and G. O'Sullivan, "An unusual case of stridor due to osteophytes of the cervical spine: (Forestier's disease)," *Journal of Laryngology and Otolaryngology*, vol. 113, no. 1, pp. 65–67, 1999.
- [8] K. Demuyneck, F. Van Calenbergh, J. Goffin, J. Verschakelen, M. Demedts, and K. Van de Woestijne, "Upper airway obstruction

- caused by a cervical osteophyte," *Chest*, vol. 108, no. 1, pp. 283–284, 1995.
- [9] A. J. Matan, J. Hsu, and B. A. Fredrickson, "Management of respiratory compromise caused by cervical osteophytes: a case report and review of the literature," *Spine Journal*, vol. 2, no. 6, pp. 456–459, 2002.
- [10] C. B. Caminos, I. Z. Cenoz, C. J. Louis, T. B. Otano, B. F. Esáin, and M. T. F. Pérez de Ciriza, "Forestier disease: an unusual cause of upper airway obstruction," *American Journal of Emergency Medicine*, vol. 26, no. 9, pp. 1072.e1–1072.e3, 2008.
- [11] B. Marks, E. Schober, and H. Swoboda, "Diffuse idiopathic skeletal hyperostosis causing obstructing laryngeal edema," *European Archives of Oto-Rhino-Laryngology*, vol. 255, no. 5, pp. 256–258, 1998.
- [12] K. Aydin, T. Ulug, and T. Simsek, "Bilateral vocal cord paralysis caused by cervical spinal osteophytes," *British Journal of Radiology*, vol. 75, no. 900, pp. 990–993, 2002.
- [13] W. L. Verstraete, H. G. De Cauwer, D. Verhulst, and F. Jacobs, "Vocal cord immobilisation in diffuse idiopathic skeletal hyperostosis (DISH)," *Acta Oto-Rhino-Laryngologica Belgica*, vol. 52, no. 1, pp. 79–84, 1998.
- [14] S. Koizumi, M. Yamaguchi-Okada, and H. Namba, "Myelopathy due to multilevel cervical canal stenosis with forestier disease," *Neurologia Medico-Chirurgica*, vol. 50, no. 10, pp. 942–945, 2010.
- [15] H. Pascal-Moussellard, G. Drossard, J. C. Cursolles, Y. Catonné, and D. Smadja, "Myelopathy by lesions of the craniocervical junction in a patient with forestier disease," *Spine*, vol. 31, no. 16, pp. E557–E560, 2006.
- [16] C. P. Winslow, T. J. Winslow, and M. K. Wax, "Dysphonia and dysphagia following the anterior approach to the cervical spine," *Archives of Otolaryngology*, vol. 127, no. 1, pp. 51–55, 2001.
- [17] M. H. Saffouri and P. H. Ward, "Surgical correction of dysphagia due to cervical osteophytes," *Annals of Otolaryngology and Rhinology*, vol. 83, no. 1, pp. 65–70, 1974.
- [18] S. Uppal and A. H. Wheatley, "Transpharyngeal approach for the treatment of dysphagia due to Forestier's disease," *Journal of Laryngology and Otology*, vol. 113, no. 4, pp. 366–368, 1999.
- [19] H. Heeneman, "Vocal cord paralysis following approaches to the anterior cervical spine," *Laryngoscope*, vol. 83, no. 1, pp. 17–21, 1973.



**Hindawi**  
Submit your manuscripts at  
<http://www.hindawi.com>

