

Case Report

A Constellation of Rare Findings in a Case of Goldenhar Syndrome

Mitesh Bedi, Rakesh Kumar Jain, Vipin Kumar Barala, Abhimanyu Singh, and Hiranmayi Jha

Department of Plastic Surgery, SMS Medical College, Jaipur, Rajasthan, India

Correspondence should be addressed to Mitesh Bedi; miteshbedi03@gmail.com

Received 28 December 2016; Revised 19 March 2017; Accepted 20 April 2017; Published 21 May 2017

Academic Editor: Mohammad M. A. Faridi

Copyright © 2017 Mitesh Bedi et al. This is an open access article distributed under the Creative Commons Attribution License, which permits unrestricted use, distribution, and reproduction in any medium, provided the original work is properly cited.

An 18-month-old child presented with right macrostomia, bilateral preauricular skin tags, bilateral CTEV, squint in bilateral eyes, thoracic vertebral anomalies, right sided aortic arch, and associated left pulmonary agenesis. The patient did not have any associated respiratory symptoms. Ipsilateral pulmonary agenesis is considered as a rare association with Goldenhar syndrome and a case of contralateral pulmonary aplasia has been described as an even rarer association.

1. Introduction

Oculoauricular dysplasia, consisting of preauricular appendages, fistulas, and epibulbar dermoids, was first described in 1952 by the Swiss ophthalmologist Maurice Goldenhar and hence named Goldenhar syndrome. Gorlin et al. (1963) included vertebral anomalies as signs of the syndrome and suggested the name oculoauriculovertebral (OAV) dysplasia for this condition [1]. The incidence of Goldenhar syndrome has been reported to be 1:3500–1:5600 with a male to female ratio of 3:2 [2]. It is an incompletely understood spectrum of disorders of unknown etiology. It is a complex malformation of varying severity involving the structures arising from first and second branchial arches, first pharyngeal pouch, first branchial cleft, and primordia of the temporal bone.

2. Case Report

An 18-month-old child referred to the Department of Plastic and reconstructive surgery, SMS Medical College and Hospital, Jaipur, with complaints of macrostomia and bilateral preauricular skin tags. The child was born as a full term normal vaginal delivery with immediate cry and a birth weight of 1.75 kgs. There was no history of trauma to head and neck region or maternal exposure to teratogenic agents. The child was also noted for the presence of bilateral CTEV

at birth. There were no signs of mental retardation or impairment of cognitive function. On examination, the head circumference was 43 cms. The child's weight was 13 kgs. And length was 74.93 cms. There were preauricular skin tags bilaterally along with macrostomia on right side (Figures 1 and 2) and squint in bilateral eyes; however, the child did not have any epibulbar dermoids or cyst.

The patient is undergoing treatment with serial casting for bilateral CTEV at present.

The patient has not had any previous history of respiratory problems.

Imaging studies include the following:

X-ray hands: normal bone age

X-ray vertebra (Figure 3): multiple thoracic vertebrae anomaly present including the following:

- (i) Mild scoliosis
- (ii) Butterfly vertebrae (C5 and T1)

X-ray chest: complete loss of volume of left lung with contralateral hyperinflated lung and rib crowding in left hemithorax (Figure 4)

USG abdomen: liver slightly enlarged and bright; kidneys: normal [3]

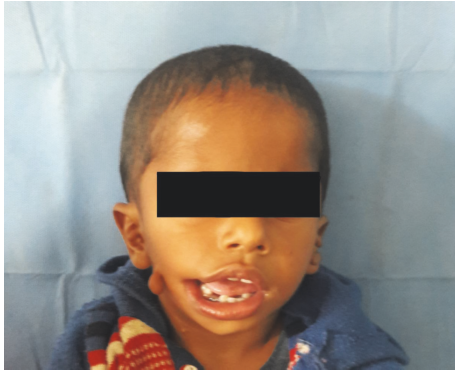

FIGURE 1: Frontal profile of patient.

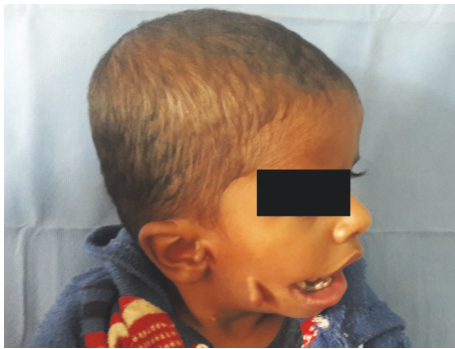

FIGURE 2: Side profile patient.

Echocardiography: normal

CT thorax (Figure 5):

- (i) Nonvisualization of left lung parenchyma and left bronchus with cardiac border shifted ipsilaterally
- (ii) Right sided aortic arch

The child had a combination of rare findings including preauricular skin tags bilaterally along with macrostomia on right side, butterfly vertebrae (C5 and T1), left pulmonary agenesis, right sided aortic arch, and bilateral CTEV.

No genetic studies were carried out in the patient.

On the basis of these findings, a diagnosis of Goldenhar syndrome with pulmonary agenesis was made.

3. Management and Follow-Up

The patient was undergoing serial casting for bilateral club foot in orthopaedics department, at the time of presentation to plastic surgery department. The patient was operated on for correction of macrostomia and preauricular skin tags. The intraoperative as well as the postoperative course was uneventful.

4. Discussion

The classical features of Goldenhar syndrome patients involve ocular anomalies, including microphthalmia, anophthalmia,

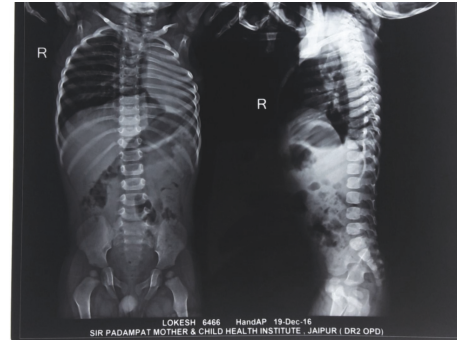


FIGURE 3: X-ray vertebrae.

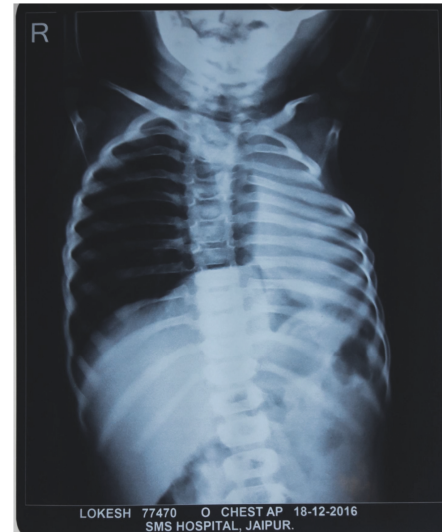

FIGURE 4: X-ray chest.

epibulbar dermoid (or lipodermoid) tumors, and eyelid colobomas, aural defects, such as preauricular tags, anotia, microtia, and hearing loss, vertebral abnormalities, such as scoliosis, hemivertebrae, and cervical fusion, and mandibular hypoplasia [4–6]. There may be an association with other major organ system anomalies including cardiac structural defects, renal agenesis, pulmonary agenesis, and vascular anomalies [7–9]. Our patient had no prior history of respiratory complaints, and the finding of pulmonary findings was an incidental finding on work-up of the patient. There have been only few reports of Goldenhar syndrome associated pulmonary anomalies in the literature [10, 11]. Usually, there is involvement of the lung on the same side as that of facial anomalies [10, 12, 13]. Contralateral pulmonary involvement is rarest association reported with Goldenhar syndrome [14, 15]. Although diagnosis is mainly clinical, radiographic investigations help to support the clinical diagnosis. Prenatal diagnosis is possible with considerable accuracy with ultrasound which may detect obvious defects. Since no specific genes have been linked to this syndrome, prenatal deoxyribonucleic acid testing cannot be used to diagnose the condition [16]. Orthopaedic abnormalities in this syndrome usually include spinal anomalies but may also rarely involve congenital

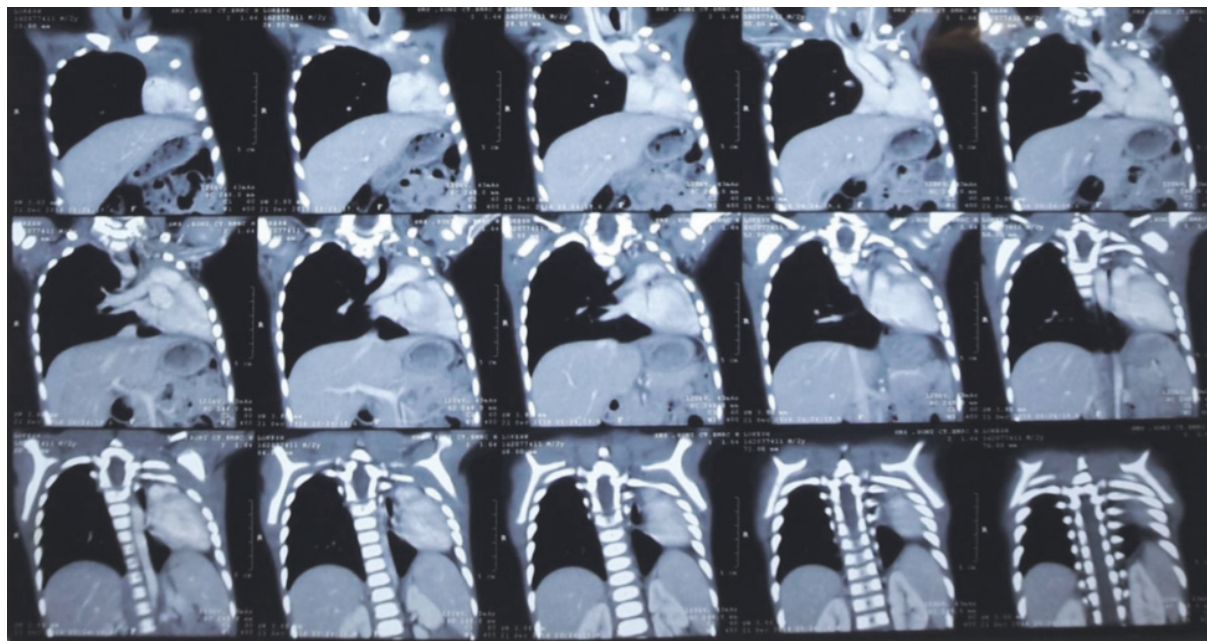


FIGURE 5: CT thorax.

dislocation of the hip, Sprengel's deformity, clubfoot, and radial limb defects [17]. A combination of these rare findings in a single patient has been rarely reported in the literature to the best of our knowledge.

Conflicts of Interest

The authors declare that there are no conflicts of interest regarding the publication of this paper.

References

- [1] M. Goldenhar, "Associations malformatives de l'oeil et l'oreille, en particulier le syndrome dermoideépibulbaire-appendices auriculaires-fistula auriscongenita et ses relations avec la dysostosemandibulo-faciale," *Journal of Human Genetics*, vol. 1, pp. 243–282, 1952.
- [2] C. S. Ashokan, A. Sreenivasan, and G. K. Saraswathy, "Goldenhar syndrome—review with case series," *Journal of Clinical and Diagnostic Research*, vol. 8, no. 4, pp. ZD17–ZD19, 2014.
- [3] N. Berker, G. Acaroğlu, and E. Soykan, "Goldenhar's syndrome (oculo-auriculo-vertebral dysplasia) with congenital facial nerve palsy," *Yonsei Medical Journal*, vol. 45, no. 1, pp. 157–160, 2004.
- [4] B. R. Rollnick, C. I. Kaye, K. Nagatoshi, W. Hauck, and A. O. Martin, "Oculoauriculovertebral dysplasia and variants: phenotypic characteristics of 294 patients," *American Journal of Medical Genetics*, vol. 26, no. 2, pp. 361–375, 1986.
- [5] K. Strömland, M. Miller, L. Sjögreen et al., "Oculo-auriculo-vertebral spectrum: associated anomalies, functional deficits and possible developmental risk factors," *American Journal of Medical Genetics, Part A*, vol. 143A, no. 12, pp. 1317–1325, 2007.
- [6] P. J. Anderson and D. J. David, "Spinal anomalies in Goldenhar syndrome," *Cleft Palate-Craniofacial Journal*, vol. 42, no. 5, pp. 477–480, 2005.
- [7] R. Kokavec, "Goldenhar syndrome with various clinical manifestations," *Cleft Palate-Craniofacial Journal*, vol. 43, no. 5, pp. 628–634, 2006.
- [8] A. Greenough, T. Ahmed, and S. Broughton, "Unilateral pulmonary agenesis," *Journal of Perinatal Medicine*, vol. 34, no. 1, pp. 80–81, 2006.
- [9] M. Fischer, M. Gorenflo, and J. Eichhorn, "First description of unilateral lung agenesis and anomalous pulmonary venous connection in a newborn with Goldenhar syndrome," *Cardiology in the young*, vol. 22, no. 3, pp. 344–345, 2012.
- [10] B. Ermis, N. Oztas, M. Yildirim, M. Hosnuter, and T. Yavuz, "Pulmonary Hypoplasia in a Newborn with Goldenhar Syndrome," *Journal of Pediatrics*, vol. 156, no. 1, p. article 161, 2010.
- [11] G. J. Downing and H. Kilbride, "An interesting case presentation: pulmonary malformations associated with oculoauriculo-vertebral dysplasia (Goldenharanomalad)," *Journal of Perinatology*, vol. 11, pp. 190–192, 1991.
- [12] D. Milani and A. Selicorni, "Right pulmonary agenesis with ipsilateral microtia: a new laterality association or part of the oculoauriculo-vertebral spectrum?" *Prenatal Diagnosis*, vol. 22, no. 11, pp. 1053–1054, 2002.
- [13] M. L. Cunningham and N. Mann, "Pulmonary agenesis: a predictor of ipsilateral malformations," *American Journal of Medical Genetics*, vol. 70, no. 4, pp. 391–398, 1997.
- [14] F. Cekmez, E. Z. Ince, A. Coban, S. Yildirim, E. O. Bulut, and Kayserili, "Goldenhar syndrome: a new case expanding the phenotype by costal agenesis and pulmonary hypoplasia," *European Review for Medical and Pharmacological Sciences*, vol. 16, no. 9, pp. 1307–1308, 2012.
- [15] T. S. Juggal, J. Kumar, S. Gupta, and A. Garg, "Goldenhar syndrome with contralateral pulmonary aplasia: a rare association," *Journal of Radiology Case Reports*, vol. 10, no. 1, pp. 35–40, 2016.

- [16] M. Goswami, U. Bhushan, and B. Jangra, "Goldenhar Syndrome: a case report with review," *International Journal of Clinical Pediatric Dentistry*, vol. 9, no. 3, pp. 278–280, 2016.
- [17] S. W. Avon and J. L. Shively, "Orthopaedic manifestations of goldenhar syndrome," *Journal of Pediatric Orthopaedics*, vol. 8, no. 6, pp. 683–686, 1988.



Hindawi
Submit your manuscripts at
<https://www.hindawi.com>

