

Case Report

Genital and Intertriginous Rashes Refractory to Antimicrobial Treatments: Have You Thought about Crohn's Disease?

Candelaria O'Farrell, Annette Roberts , Claudia Riera Canales, Carrie Firestone Baum, and Lina Maria Felipez

Nicklaus Children's Hospital, Miami, FL, USA

Correspondence should be addressed to Annette Roberts; annetterobertsmd@gmail.com

Received 25 February 2021; Accepted 9 July 2021; Published 23 July 2021

Academic Editor: Anselm Chi Wai Lee

Copyright © 2021 Candelaria O'Farrell et al. This is an open access article distributed under the Creative Commons Attribution License, which permits unrestricted use, distribution, and reproduction in any medium, provided the original work is properly cited.

Crohn's disease is an inflammatory bowel disease that can have multiple extraintestinal manifestations and can develop prior to, following, or simultaneously with gastrointestinal tract involvement (Aberumand et al. (2017), Georgious et al. (2006), Larsen et al. (2010), Levine and Burakoff (2011), Louis et al. (2018)). This report examines the case of a 16-year-old male with a rash of the genital, intergluteal, and inguinal regions refractory to antimicrobial treatments suspicious for an extraintestinal manifestation of Crohn's disease. The patient was diagnosed with inflammatory, nonfistulizing colonic Crohn's disease following presentation with gastrointestinal symptoms including abdominal pain and bloody stools 6 months after the onset of the rash. The genital lesions resolved after starting treatment for Crohn's disease with adalimumab.

1. Introduction

Crohn's disease (CD) is a type of inflammatory bowel disease that can present with extraintestinal manifestations and can develop prior to, following, or simultaneously with gastrointestinal tract involvement and symptoms [1–5]. These extraintestinal manifestations may present as cutaneous lesions of the genital region. Rarely, extraintestinal manifestations of Crohn's disease can manifest as cutaneous noncaseating granulomas outside of the gastrointestinal tract and is referred to as metastatic Crohn's disease [1, 5–9]. Cutaneous manifestations of CD may occasionally precede intestinal involvement and can occur anywhere on the body including the genital regions [2–7]. Anti-TNF medications have been used in the management of Crohn's disease with improvement of extraintestinal manifestations of Crohn's [7, 10].

2. Case Presentation

Our patient, a 16-year-old male, initially presented for evaluation of abdominal pain, bloody stools, and weight loss.

6 months prior to the onset of his abdominal symptoms, he had developed a nonpruriginous, painless, erythematous, scaly, and raised rash on his inguinal, scrotal, and intergluteal regions (Figure 1). He had no other notable past medical history. He was originally diagnosed with jock's itch and treated with topical ciclopirox without improvement. After failing treatment with topical ciclopirox, he was treated for suspected bacterial and fungal infections with PO doxycycline and topical mupirocin and ketoconazole creams also without improvement. Dermatophyte test medium (DTM) fungal cultures were negative, and an aerobic culture grew *Staphylococcus* and *Moraxella catarrhalis*. Aluminum acetate soaks were added with only partial improvement of rash. Upon reexamination, he was noted to have well-demarcated erythematous scaly plaques on the groin folds and gluteal cleft with associated skin-colored nodules and papules, as well as erythema and edema of the scrotum. Meanwhile, he underwent endoscopy, colonoscopy, and MRI enterography for workup of his abdominal symptoms. His endoscopy was unremarkable. Colonoscopy visualized congestion, erosions, friability, and loss of vascularity consistent with moderate inflammation in the rectum and

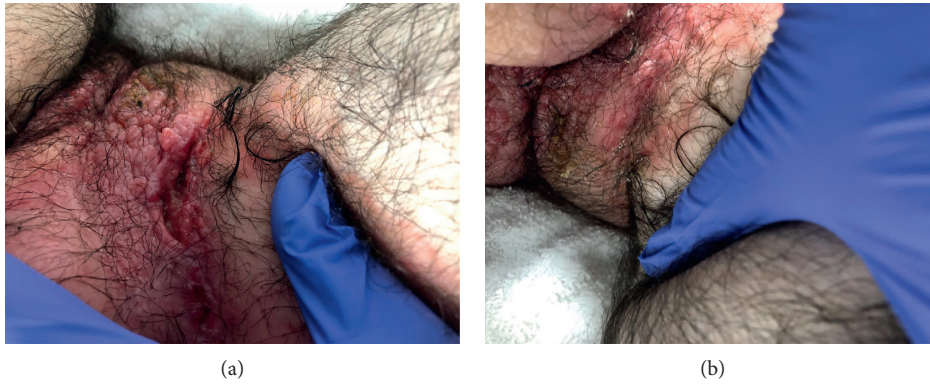

FIGURE 1: Well-demarcated erythematous plaques, nodules, and papules noted on the groin (a) and gluteal cleft (b) observed prior to treatment with adalimumab.

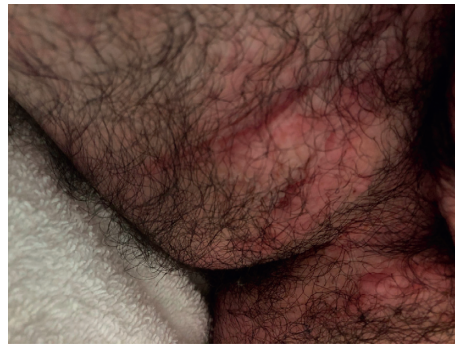

FIGURE 2: Improvement following 8 months of treatment with adalimumab.

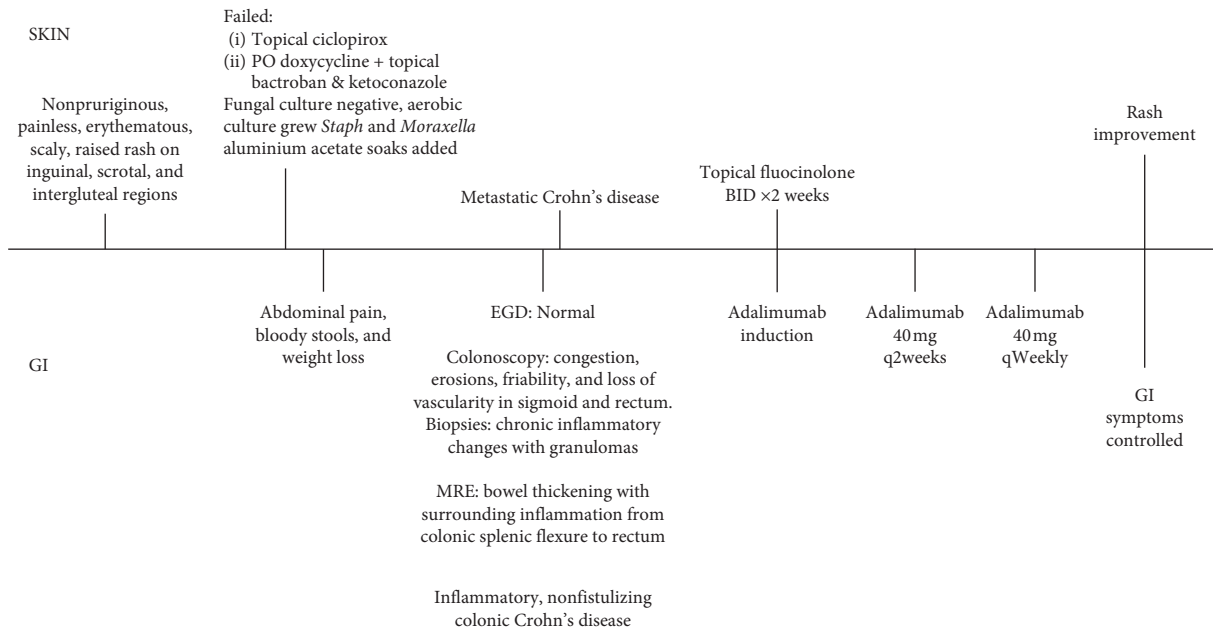


FIGURE 3: Timeline depicting the series of events occurring from the onset of the rash to its resolution following appropriate therapy.

sigmoid colon. Biopsies showed chronic inflammatory changes with focal epithelioid granulomata in the colon with negative acid-fast bacilli and fungal stains. MRI

enterography noted bowel thickening with surrounding inflammation extending from the colonic splenic flexure to the rectum. A diagnosis of inflammatory, nonfistulizing

colonic CD was made. After 2 weeks of topical flucinolone twice daily and induction therapy with adalimumab followed by subsequent doses of 40 mg every other week, the rash had greatly improved, consistent with an extraintestinal manifestation of his CD (Figure 2). His adalimumab dose was increased to 40 mg weekly due to subtherapeutic drug levels (6.3 ug/ml) and persistence of GI symptoms. Continued improvement of the rash was noted with the subsequent dose increase.

3. Discussion

CD is a multisystemic chronic inflammatory disorder that can present with cutaneous findings preceding gastrointestinal symptoms of CD such as abdominal pain and bloody stools. Early recognition of extraintestinal cutaneous manifestations of CD can lead to a timely diagnosis and treatment of CD with resolution of both intestinal and extraintestinal symptoms. Thus, when encountering genital or intertriginous rashes refractory to antimicrobial treatments, underlying inflammatory bowel disease should be investigated (Figure 3).

Data Availability

No data were used to support the findings of this study.

Consent

Consent to authorize the use of these images and case summary for publication were obtained by the patient and parent prior to submission of this manuscript.

Conflicts of Interest

The authors declare that there are no conflicts of interest regarding the publication of this paper.

References

- [1] B. Aberumand, J. Howard, and J. Howard, "Metastatic crohn's disease: an approach to an uncommon but important cutaneous disorder," *BioMed Research International*, vol. 2017, Article ID 8192150, 6 pages, 2017.
- [2] G. Georgiou, E. Pasmatz, A. Monastirli, and D. Tsambaos, "Cutaneous manifestations of inflammatory bowel disease," *Hospital Chronicle*, vol. 1, pp. 158–168, 2006.
- [3] S. Larsen, K. Bendtzen, and O. H. Nielsen, "Extraintestinal manifestations of inflammatory bowel disease: epidemiology, diagnosis, and management," *Annals of Medicine*, vol. 42, no. 2, pp. 97–114, 2010.
- [4] J. S. Levine and R. Burakoff, "Extraintestinal manifestations of inflammatory bowel disease," *Gastroenterology & Hepatology*, vol. 7, no. 4, pp. 235–241, 2011.
- [5] E. J. Louis, W. Reinisch, D. A. Schwartz et al., "Adalimumab reduces extraintestinal manifestations in patients with crohn's disease: a pooled analysis of 11 clinical studies," *Advances in Therapy*, vol. 35, no. 4, pp. 563–576, 2018.
- [6] A. A. Kafity, A. E. Pellegrini, and J. J. Fromkes, "Metastatic Crohn's disease," *Journal of Clinical Gastroenterology*, vol. 17, no. 4, pp. 300–303, 1993.
- [7] D. J. B. Kurtzman, T. Jones, F. Lian, and L. S. Peng, "Metastatic Crohn's disease: a review and approach to therapy," *Journal of the American Academy of Dermatology*, vol. 71, no. 4, pp. 804–813, 2014.
- [8] C. Panackel, J. John, D. Krishnadas, and K. Vinayakumar, "Metastatic Crohn's disease of external genitalia," *Indian Journal of Dermatology*, vol. 53, no. 3, pp. 146–148, 2008.
- [9] S. L. Schneider, K. Foster, D. Patel, and T. Shwayder, "Cutaneous manifestations of metastatic Crohn's disease," *Pediatric Dermatology*, vol. 35, no. 5, pp. 566–574, 2018.
- [10] S. R. Vavricka, J. A. Galván, H. Dawson et al., "Expression patterns of TNF α , MAdCAM1, and STAT3 in intestinal and skin manifestations of inflammatory bowel disease," *Journal of Crohn's and Colitis*, vol. 12, no. 3, pp. 347–354, 2018.