

Erratum

Erratum to “A Rare Case of Fatal Hemorrhagic Stroke in a Young Female with Early Mixed Connective Tissue Disease”

James R. Agapoff IV 

Department of Psychiatry, University of Hawai'i, John A. Burns School of Medicine, Honolulu, HI, USA

Correspondence should be addressed to James R. Agapoff IV; nubis13@gmail.com

Received 24 January 2022; Accepted 24 January 2022; Published 23 February 2022

Copyright © 2022 James R. Agapoff IV. This is an open access article distributed under the Creative Commons Attribution License, which permits unrestricted use, distribution, and reproduction in any medium, provided the original work is properly cited.

In the article titled “A Rare Case of Fatal Hemorrhagic Stroke in a Young Female with Early Mixed Connective Tissue Disease” [1], the second paragraph of the Discussion section should be corrected as follows due to an error introduced during the production process.

“Only 10–20% of patients with MCTD experience neurological manifestations, with few case reports known where neurological symptoms were the presenting symptom [6–8]. [6, 7]” to “Only 10–20% of patients with MCTD experience neurological manifestations, with few case reports known where neurological symptoms were the presenting symptom [6–8].”

In addition, Figure 1 is revised as follows, to remove the cursor from the image and include a scale.

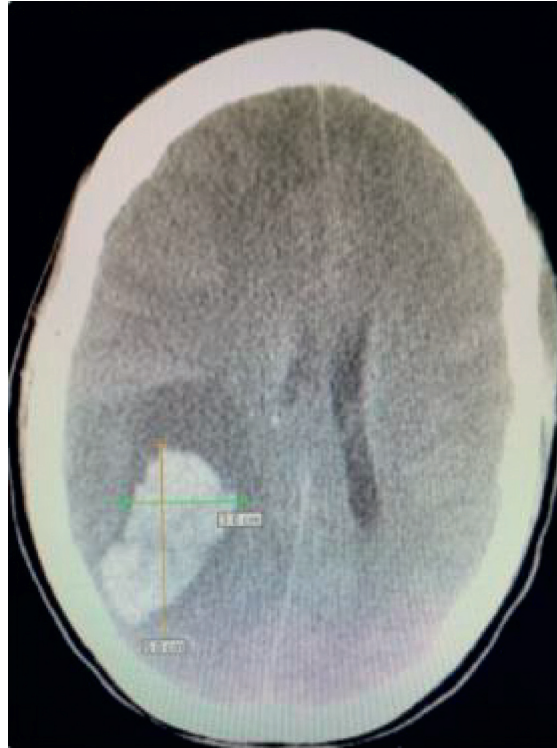


FIGURE 1: Computerized tomography (CT) axial head without contrast showing intraparenchymal hemorrhage and secondary mass effect.

References

- [1] R. James, "A rare case of fatal hemorrhagic stroke in a young female with early mixed connective tissue disease," *Case Reports in Rheumatology*, vol. 2021, Article ID 5321438, 4 pages, 2021.