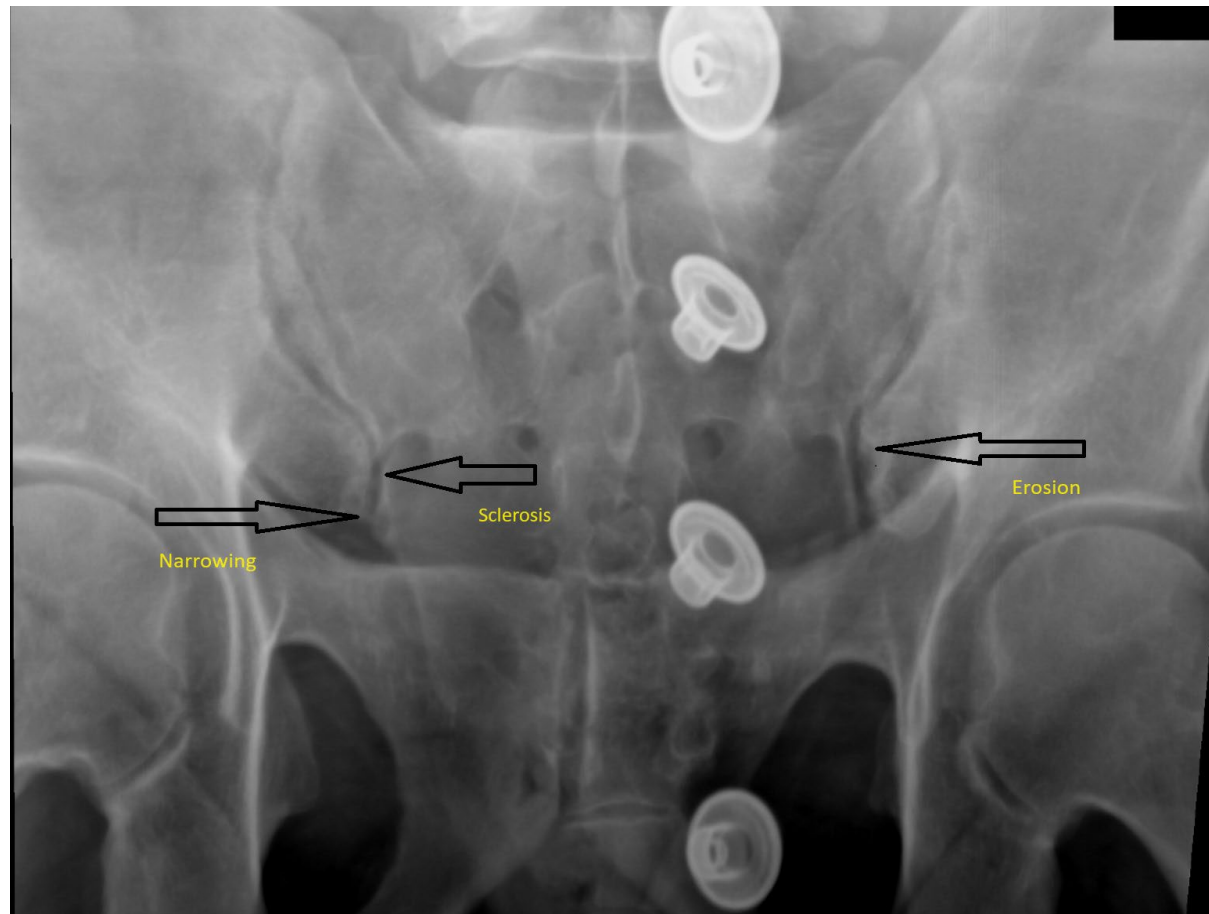


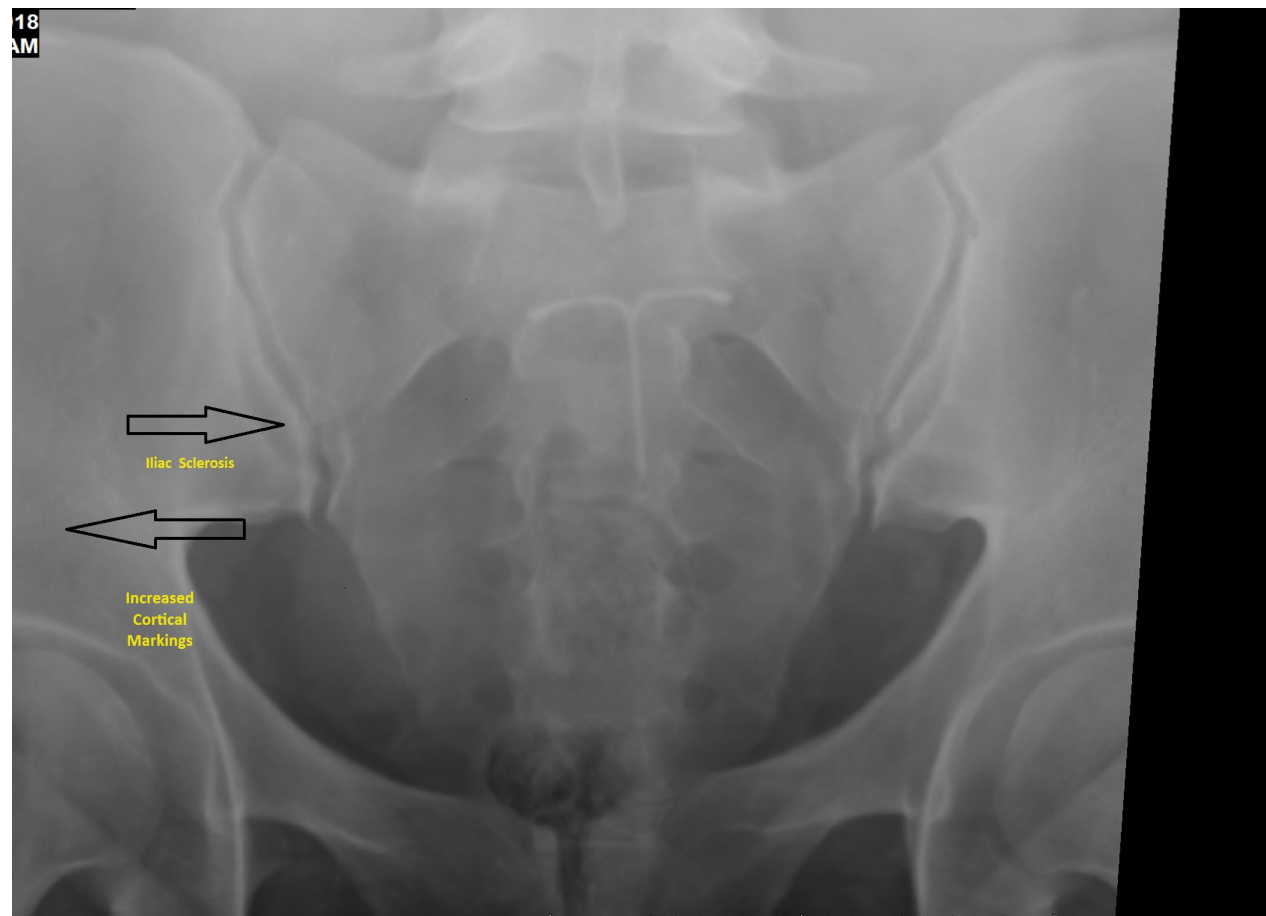
Rare Case Studies

Bilateral And Symmetric Sacroiliac Disease

Ap Sacroiliac Image #1 Bilateral SIJ Disease



AP Sacroiliac Image #2 with sclerosis along interior, inferior iliac margins bilaterally



AP Sacroiliac Image #3 –Bilateral Iliac Sclerosis with narrowing, marrow edema on MRI

