Hindawi Publishing Corporation
Case Reports in Veterinary Medicine
Volume 2012, Article ID 230398, 4 pages
doi:10.1155/2012/230398

Case Report

Klossiella equi Infection in an Immunosuppressed Horse: Evidence of Long-Term Infection

Lora R. Ballweber,[1] Deanna Dailey,[2] and Gabriele Landolt[3]

[1] *Veterinary Diagnostic Laboratory, College of Veterinary Medicine and Biomedical Sciences, Colorado State University, Fort Collins, CO 80523-1644, USA*
[2] *Cell and Molecular Biology Graduate Program, College of Veterinary Medicine and Biomedical Sciences, Colorado State University, Fort Collins, CO 80523-1005, USA*
[3] *Department of Clinical Sciences, College of Veterinary Medicine and Biomedical Sciences, Colorado State University, 300 West Drake Road, Fort Collins, CO 80523-1678, USA*

Correspondence should be addressed to Lora R. Ballweber, lora.ballweber@colostate.edu

Received 26 September 2012; Accepted 11 November 2012

Academic Editors: J. Orós, I. Pires, and D. M. Wong

A 13-year-old quarter horse gelding presented with a history of hematuria of approximately 1-year duration, anemia, weight loss over the previous six months, and bilateral nasal discharge of 2-week duration. It was determined that hematuria was most likely caused by the coccidian parasite *Klossiella equi*. Additional case workup suggested a diagnosis of pituitary pars intermedia dysfunction. Confirmatory testing was declined by the owners and the horse was discharged on medical therapy. Despite initial improvement after discharge, the horse developed unresolving sinusitis approximately 1 year later and was euthanized. Necropsy confirmed the presence of an adenoma of the pars intermedia of the pituitary gland, supporting the initial diagnosis. Additional findings included multiple developmental stages of *K. equi* present in the kidneys. This finding demonstrates infections with *K. equi* can be chronic in nature and supports the association of increased severity of klossiellosis and impaired immune function.

1. Introduction

Klossiella equi is the only known renal coccidian parasite of equines [1–8]. Although first described in 1946, very little is known about this parasite. Schizogony occurs within Bowman's capsule and the proximal convoluted tubules while gametogony and sporogony occur within the loop of Henle and distal convoluted tubules [3, 5, 6, 9, 10]. Mode of transmission has not been identified but is thought to be through ingestion of sporulated sporocysts passed in urine [4, 9]. The duration of infection has not been determined, although, as a coccidian it has been proposed that infections would be self-limiting [7]. There is no known effective treatment.

Klossiella equi has been reported in various areas of the world but the prevalence is unknown. Attempts to define the prevalence ante mortem have met with difficulties in recovery of sporocysts in urine samples [7]; thus, prevalence has been primarily based on histological examination of the kidneys taken at necropsy. Using this, 6/47 horses in Australia [7], 2/8 donkeys in Kenya [6], 8/14 burros residing in the US but born in Mexico [1], and 5/40 ponies and 3/14 burros in the US [9] have been found to be infected. Thus, the prevalence appears to vary considerably. In addition to horses, ponies, donkeys, and burros, *K. equi* has also been reported from zebras [8].

Klossiella equi is usually considered to be an incidental finding [1, 6, 8], although it has been associated with renal tubular nephrosis and nephritis in immunocompromised animals [4, 5, 7]. Thus, there may be an association between severity of infection with *K. equi* and impaired immune function.

2. Case Presentation

A 13-year-old quarter horse gelding was admitted to the Colorado State University (CSU) Veterinary Teaching Hospital (VTH) with a history of hematuria of approximately 1-year duration, anemia, weight loss over the previous six

months, and bilateral nasal discharge of 2-week duration. Urethroscopy and cystoscopy performed by the referring veterinarian revealed macroscopic pigmenturia originating from the left ureter. No other abnormalities were detected. The horse was treated (duration unknown) with antimicrobials consisting of sulfadiazine/trimethoprim (30 mg/kg PO BID) and ceftiofur (2.2 mg/kg IM SID) for presumed urinary tract infection, which did not resolve the hematuria.

Upon presentation at the VTH, the horse was quiet, alert, and responsive. His body weight was 454 kg with a body condition score of 4/9. Physical examination demonstrated normal vital signs, bilateral mucopurulent nasal discharge, and an enlarged right submandibular lymph node. Rebreathing examination and rectal palpation revealed no abnormalities. Complete blood count and biochemical profile revealed the presence of a lymphopenia ($0.7 \times 10^3/\mu$L reference range $1.5–4.0 \times 10^3/\mu$L), macrocytic erythrocytopenia (red blood cell count: $5.7 \times 10^6/\mu$L reference range $6.5–10.5 \times 10^6/\mu$L; mean corpuscular volume: 61 fL reference range 42–52 fL), and hyperglycemia (239 mg/dL reference range 70–135 mg/dL). Quantitative serum immunoglobulin test indicated that IgM was decreased (31 mg/dL reference range 89–151 mg/dL) with a compensatory increase in IgG and IgA (IgG: 3863 mg/dL reference range 984–1684 mg/dL; IgA: 658 mg/dL reference range 67–239 mg/dL).

Endoscopy of the lower urinary tract showed no structural abnormalities within the urethra or bladder; however, the urine present in the bladder was red in color. Urine was observed flowing from both ureteral openings, with urine exiting from the right ureter straw colored and urine from the left ureter red in color. The bladder and both ureters were catheterized (endoscopically guided) and urine collected. Glucosuria (100 mg/dL) was evident in all 3 urine samples; hematuria (200–500 red blood cells/high-power field) and mild proteinuria were present in the urine from the left ureter and bladder. Coccidian sporocysts (Figure 1) were found in the urine sediment in all 3 samples and on centrifugal flotation with Sheather's sugar solution (1.27 sp. g.). Sporocysts measured $15.0–17.5 \times 7.5–12.5\,\mu$m (average = $16.25 \times 10.25\,\mu$m), contained 8–12 sporozoites and were morphologically identical to *K. equi* [4, 7]. Bacterial culture of both ureter samples resulted in no growth. Ultrasonographic evaluation of the kidneys showed a mildly enlarged left kidney with normal shape and corticomedullary distinction.

An upper airway endoscopic examination revealed mucopurulent exudate in both nasal passages, which appeared to originate from the sinus openings; examination of the guttural pouches, ethmoids, and upper trachea did not reveal any abnormalities. Radiographs of the maxillary sinuses and tooth roots showed an irregular wavy surface to the occlusion surfaces of the upper and lower dental arcades. Moreover, a gap was evident between the fourth premolar and first molar bilaterally, with an increased lucency along the caudal border of the fourth premolar (108) and the rostral border of the first molar (109) on the right side, with sclerosis of the alveolar bone surrounding these teeth. Lastly, there was evidence of fluid in the right rostral and caudal maxillary sinuses. An oral examination confirmed the presence of a wave mouth and bilateral diastemata between the upper fourth premolars (108, 208) and first molars (109, 209), as well as the presence of periodontal disease.

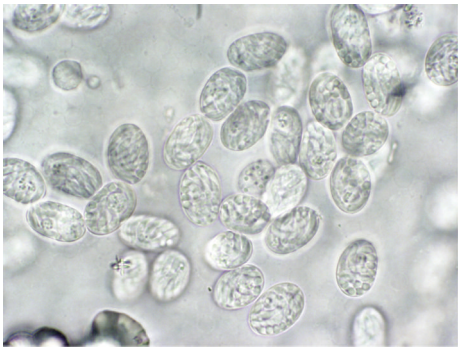

Figure 1: Sporocysts of *Klossiella equi* found on centrifugal flotation of urine with Sheather's sugar solution (1.27 sp. g.).

The findings of hyperglycemia, glucosuria, and evidence of chronic infections (sinusitis and hematuria) in a >7-year old horse are consistent with pituitary pars intermedia dysfunction (PPID) [11] and testing recommended. Although the dexamethasone suppression test (DST) is the most widely accepted and recommended test for the diagnosis of PPID in horses, the owners declined this procedure but did consent to resting ACTH concentration. Determination of the resting ACTH level is considered to be a good alternative to the DST when the latter is inconclusive or not an option [11]. A blood sample was collected which showed baseline endogenous ACTH level to be elevated (63 pg/mL reference range 18–25 pg/mL), a finding consistent with PPID [11]. Recommendations were made regarding the treatment of the dental abnormalities, the sinusitis, the presumed PPID, and the *K. equi* infection. The owners elected to pursue medical therapy consisting of administration of a nonsteroidal anti-inflammatory drug (phenylbutazone, 4.4 mg/kg PO once daily for 3 days, followed by 2.2 mg/kg PO once daily for 10 days), an antibiotic (sulfadiazine/trimethoprim, 30 mg/kg PO twice daily for 2 weeks), as well as an antiprotozoal agent (pyrimethamine, 1 mg/kg PO once daily for 2 weeks). The horse was discharged from the VTH with a guarded prognosis.

Over the next several months, follow-up reports by the referring veterinarian indicated that the horse did well on the treatment with improvement in appetite and resolution of the macroscopic hematuria. However, approximately 1 year after the initial evaluation at the VTH, the horse developed bilateral facial swelling. In addition, a focal area of skin necrosis and swelling developed over the right mandible that drained mucopurulent exudate. Antibiotic treatment by the referring veterinarian resulted in improvement in clinical signs; however, as complete resolution was not achieved, the owners elected to euthanize the horse. The carcass of the animal was submitted to the CSU Veterinary Diagnostic Laboratory for necropsy.

Gross necropsy revealed firm, bilateral swelling of the maxillary sinuses and a focal area of erosion on the right

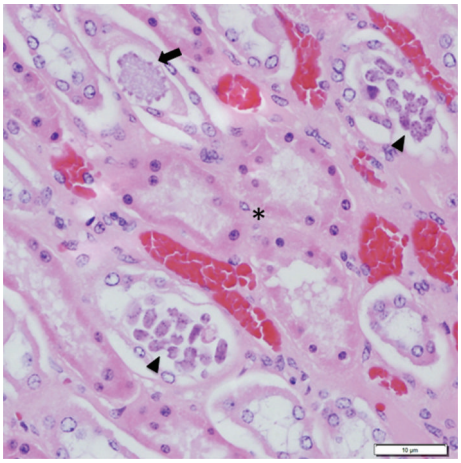

Figure 2: Multiple stages of *Klossiella equi* are found multifocally expanding tubular epithelial cells (schizont, arrow; sporocysts, arrowheads). Occasional tubular necrosis is present (asterick). (HE).

mandible. Subcutaneous tissue in this area was hyperemic and swollen but a draining tract could not be identified. Examination of the teeth showed multiple periodontal fistulas with extension into the maxillary sinuses. There was severe bilateral maxillary sinus impaction with abundant feed material and purulent exudate and chronic bilateral suppurative sinusitis of the frontal sinuses. The lungs showed focally extensive chronic fibrinous sclerosing bronchopneumonia. The pituitary gland was approximately 2.5–3 times its normal size, with a focal nodular area of hemorrhage (~1.5 cm diameter) and histologic features consistent with an adenoma of the pars intermedia. There was gross and histologic evidence of compression of the pars distalis and the overlying brain stem.

Grossly, the kidneys were normal in appearance; however, multiple developmental stages consistent with *K. equi* were found within the tubular epithelium (Figure 2). There was occasional scattered tubular ectasia and/or tubular necrosis, which was sometimes associated with the presence of parasites. There were also occasional small interstitial lymphoplasmacytic inflammatory infiltrates with rare interstitial fibroplasia, consistent with mild, chronic interstitial nephritis. Urine was not present in the bladder; thus, evaluation for sporocyst shedding could not be done.

3. Discussion

Postmortem examination of this horse confirmed the presence of an adenoma of the pars intermedia of the pituitary gland, supporting the presumed diagnosis of PPID made one year prior. PPID is a chronic disease of aged horses [11]. Typical clinical signs include hirsutism, hyperhidrosis, muscle loss, chronic or recurrent laminitis, chronic infections, delayed wound healing, and possibly polyuria/polydipsia. Commonly observed infections include chronic respiratory tract infections, sinusitis, skin diseases, and hoof abscesses. Recently, an increased susceptibility to endoparasites (i.e., small strongyles), resulting from impairment of the immune system, has been suggested [12]. Likewise, a relationship between severity of infection with *K. equi* and impaired immune function has been proposed [4, 5, 7] which is consistent with the findings of the present case.

It has been suggested that infections with *K. equi* would likely be self-limiting [7]. However, with evidence of infection spanning a year in the present case, it appears klossiellosis can be chronic in nature, at least in animals with impaired immune function. Whether this represents long-term infection or multiple reinfection events cannot be determined at this time.

The clinical sign primarily responsible for the initial referral to the VTH was unresolving hematuria despite antibiotic treatment for a presumed urinary tract infection. Hematuria has rarely been reported in *K. equi* infections [10]; however, it seems reasonable that hematuria could be a result of the epithelial cell damage caused by developing parasites.

It appears that equids with PPID or other immunosuppressive disorders are at a higher risk of chronic klossiellosis, which should be considered when evaluating these animals. Ante mortem diagnosis of klossiellosis depends on the detection of sporocysts in urine, which can be problematic. Sporocysts do not sediment readily in undiluted urine and flotation in salt solutions results in rupture of the sporocysts [7]. In the present case, sporocysts were successfully concentrated from undiluted urine by flotation with Sheather's sugar solution (1.27 sp. g.). Thus, it is suggested that sedimentation of diluted urine sample [7] or centrifugal flotation in sugar (present case) be performed when attempting to detect *K. equi* sporocysts in urine.

Conflict of Interests

The authors declare that they have no conflict of interests.

Acknowledgments

The authors wish to thank David Manuelito for assitance with case management during the initial hospital stay; they also thank the staff of both the Clinical Pathology Laboratory and the Veterinary Diagnostic Laboratory at the College of Veterinary Medicine and Biomedical Sciences for providing laboratory findings.

References

[1] H. A. Hartman, "The protozoan parasite, Klossiella equi, in the Mexican burro," *American Journal of Veterinary Research*, vol. 22, pp. 1126–1128, 1961.

[2] K. S. Todd, H. S. Gosser, and D. P. Hamilton, "*Klossiella equi* Baumann, 1946 (Sporozoa: Eucoccidiorida) from an Illinois horse," *Veterinary Medicine/Small Animal Clinician*, vol. 72, no. 3, pp. 443–448, 1977.

[3] R. J. Austin and K. H. Dies, "*Klossiella equi* in the kidneys of a horse," *Canadian Veterinary Journal*, vol. 22, no. 5, pp. 159–161, 1981.

[4] C. R. Reinemeyer, R. M. Jacobs, and G. N. Spurlock, "A coccidial sporocyst in equine urine," *Journal of the American*

Veterinary Medical Association, vol. 182, no. 11, pp. 1250–1251, 1983.

[5] W. I. Anderson, C. A. Picut, and M. E. Georgi, "*Klossiella equi* induced tubular nephrosis and interstitial nephritis in a pony," *Journal of Comparative Pathology*, vol. 98, no. 3, pp. 363–366, 1988.

[6] D. N. R. Karanja, T. A. Ngatia, and J. G. Wandera, "Donkey klossiellosis in Kenya," *Veterinary Parasitology*, vol. 59, no. 1, pp. 1–5, 1995.

[7] G. P. Reppas and G. H. Collins, "*Klossiella equi* infection in horses; sporocyst stage identified in urine," *Australian Veterinary Journal*, vol. 72, no. 8, pp. 316–318, 1995.

[8] W. K. Suedmeyer, E. Restis, and B. T. Beerntsen, "*Klossiella equi* infection in a Hartmann's Mountain zebra (*Equus zebra hartmannae*)," *Journal of Zoo and Wildlife Medicine*, vol. 37, no. 3, pp. 420–423, 2006.

[9] J. M. Vetterling and D. E. Thompson, "*Klossiella equi* Baumann, 1946 (Sporozoa: Eucoccidia: Adeleina) from equids," *Journal of Parasitology*, vol. 58, no. 3, pp. 589–594, 1972.

[10] P. K. Gathumbi, V. Varma, and C. W. Wells, "Pathological and ultrastructural features of *Equine Klossiellosis*," *The Kenya Veterinarian*, vol. 21, pp. 45–48, 2001.

[11] D. McFarlane and R. E. Toribio, "Pituitary pars intermedia dysfunction (equine cushing's disease)," in *Equine Internal Medicine*, S. M. Reed, W. M. Bayly, and D.C. Sellon, Eds., pp. 1262–1270, Elsevier, St. Louis, Mo, USA, 3rd edition, 2010.

[12] D. McFarlane, G. M. Hale, E. M. Johnson, and L. K. Maxwell, "Fecal egg counts after anthelmintic administration to aged horses and horses with pituitary pars intermedia dysfunction," *Journal of the American Veterinary Medical Association*, vol. 236, no. 3, pp. 330–334, 2010.