Hindawi Publishing Corporation
Case Reports in Veterinary Medicine
Volume 2015, Article ID 542842, 11 pages
http://dx.doi.org/10.1155/2015/542842

Case Report

Fluoroscopic-Assisted Olecranon Fracture Repair in Three Dogs

Stephen C. Jones,[1,2] Daniel D. Lewis,[1] and Matthew D. Winter[1]

[1]*Department of Small Animal Clinical Sciences, College of Veterinary Medicine, University of Florida, Gainesville, FL 32610, USA*
[2]*Department of Veterinary Clinical Sciences, College of Veterinary Medicine, The Ohio State University, 601 Vernon L. Tharp Street, Columbus, OH 43210, USA*

Correspondence should be addressed to Stephen C. Jones; jones.5609@osu.edu

Received 1 July 2015; Accepted 5 October 2015

Academic Editor: Lysimachos G. Papazoglou

Copyright © 2015 Stephen C. Jones et al. This is an open access article distributed under the Creative Commons Attribution License, which permits unrestricted use, distribution, and reproduction in any medium, provided the original work is properly cited.

Olecranon fractures in dogs are often both comminuted and intra-articular. Anatomic reduction and stable internal fixation are thus paramount to achieving primary bone healing and mitigating the development of posttraumatic osteoarthritis. Intraoperative fluoroscopy can be useful to confirm accurate fracture reduction and facilitate precise implant placement, potentially reducing the surgical exposure required and additional trauma. Despite widespread use in human surgery, reports of fluoroscopic-assisted fracture repair in dogs are limited. Presented here are three dogs in which intraoperative fluoroscopy was used to facilitate accurate olecranon fracture reduction and implant positioning. The olecranon fractures appeared to heal by primary bone union, although the anconeal process failed to obtain osseous union in one dog. Despite the development of mild-to-moderate osteoarthritis in all three dogs, and the nonunion of the anconeal process in one dog, the clinical outcome was considered successful with all dogs subjectively free of lameness at long-term follow-up evaluation. Intraoperative fluoroscopy was found to be a useful modality during fracture reduction and implant placement in dogs with olecranon fractures.

1. Introduction

The olecranon is the most proximal segment of the ulna and is comprised of the olecranon tuber, the anconeal process, and the proximal portion of the trochlear notch [1]. The triceps brachii muscle group inserts on the olecranon which functions as a lever arm to mediate elbow extension and enable weight-bearing [1].

The majority of antebrachial fractures in dogs involve the radial and ulnar diaphyses [2] with surgical intervention often directed towards stabilization of the radius alone [3]. Isolated fractures of the olecranon are rare [2]. Olecranon fractures are often comminuted and commonly involve the articular surface of the trochlear notch [4]. Owing to the large tensile force exerted by the triceps brachii muscles and the frequent articular involvement, anatomic reduction and stable internal fixation of olecranon fractures are required to promote primary bone healing, mitigate the development of posttraumatic osteoarthritis, and optimize the probability of a return to prefracture limb function.

Intraoperative fluoroscopy is routinely used during human fracture repair [5–9] and is slowly being integrated in small animal orthopedics [10–14]. The use of fluoroscopy allows surgeons to accurately assess fracture reduction while facilitating and confirming proper implant placement. Intraoperative fluoroscopy helps to reduce additional surgical trauma, often allowing surgery to be done in a minimally invasive fashion [15]. This report describes the use of intraoperative fluoroscopy to facilitate the anatomic reduction and stabilization of intra-articular olecranon fractures in three dogs.

2. Case 1

A 1-year-old spayed female Bloodhound, weighing 29 kg, presented to the University of Florida Small Animal Hospital (UF SAH) in September 2008 for evaluation of a non-weight-bearing lameness of the left thoracic limb, which was sustained in a road traffic accident. Radiographic examination

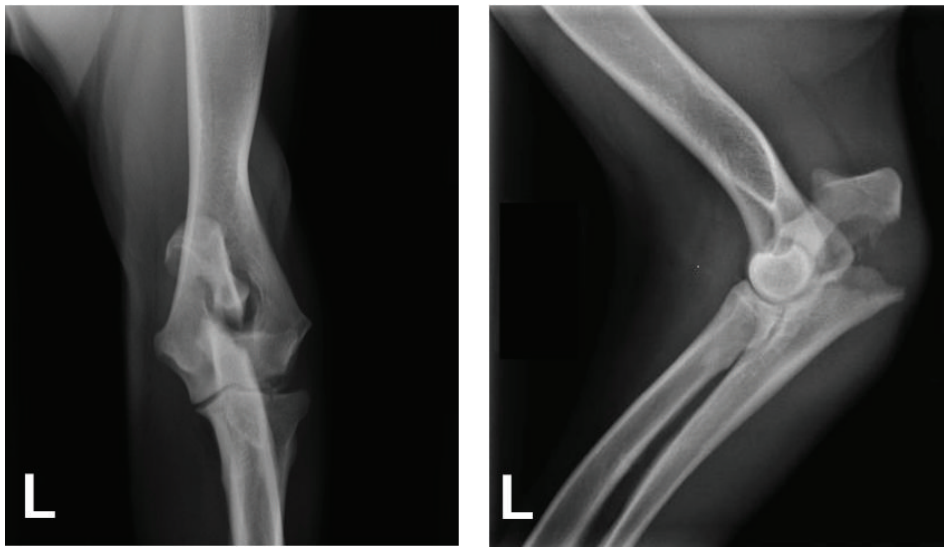

(a) (b)

Figure 1: Preoperative radiographs of dog 1. (a) Craniocaudal and (b) mediolateral radiographs showing a closed mildly comminuted short oblique fracture of the left olecranon. The fracture is seen extending into the articular margin of the ulnar trochlear notch, resulting in a proximally displaced olecranon tuber and anconeal process segment. There is a large osseous defect with adjacent mineral fragments in the lateral aspect of the humeral condyle. A linear, incomplete fissure is also seen in the proximal articular margin of the radial head.

revealed a closed, short oblique, mildly comminuted olecranon fracture extending in a caudoproximal-to-craniodistal orientation, terminating in the caudal articular margin of the ulnar trochlear notch. A linear, incomplete fissure was also detected in the proximal articular margin of the radial head. In the articular margin of the humeral capitulum, there was also a large lucent defect, with an associated displaced osteochondral fragment (Figure 1).

The dog was placed in dorsal recumbency, adjacent to the left edge of the table to facilitate fluoroscopic image acquisition. Fracture repair was accomplished via open reduction using a lateral approach [16]. The proximal olecranon fracture segment was visualized, directly reduced, and maintained in reduction with Vulsellum forceps (Schroeder Uterine Vulsellum Forceps, KNY-Scheerer Corporation of America, New York, NY). Intraoperative fluoroscopy (Siremobil Compact Fluoroscope, Siemens, Iselin, NJ) was used to assess the accuracy of reduction and implant placement. The fluoroscopic C-arm was covered with a disposable sterile plastic sleeve to prevent contamination of the surgical field. The C-arm was brought in from a caudal-to-cranial direction, positioning the elbow adjacent to the image intensifier; a member of the surgical team elevated the limb to prevent interference of the C-arm from the chest wall. Mediolaterally directed fluoroscopic images facilitated appropriate placement of an interfragmentary 1.1 mm Kirschner wire, which was placed perpendicular to the fracture line, in a caudodistal-to-cranioproximal direction. A 1.6 mm antirotational Kirschner wire was also placed in a similar orientation, under fluoroscopic guidance, immediately distal to the proximal wire. The proximal Kirschner wire functioned as a guide wire for the placement of a 3.5 mm lag screw. A 3.5 mm cannulated drill bit (Arthrex, Naples, FL, USA) was used to overdrill the cisfracture segment; a drill sleeve was inserted into the hole over the Kirschner wire and a 2.5 mm cannulated drill bit (Arthrex, Naples, FL, USA) was used to drill through the transsegment. After tapping threads in the transsegment, a 3.5 mm cortical screw was placed in lag fashion. An eight-hole 2.7 mm String-of-Pearls locking plate (Orthomed, Vero Beach, FL, USA) was contoured and applied to the lateral surface of the ulna, with two bicortical screws engaging the proximal ulnar segment and four bicortical screws engaging the distal ulnar segment. The radial head fissure fracture was directly visualized via an approach between the lateral digital extensor and the extensor carpi ulnaris muscles; this fracture was stabilized using a 1.2/1.5 mm self-compressing pin (Orthofix Magic Pin, McKinney, TX, USA) and washer, and a 0.9 mm Kirschner wire, both inserted laterally to medially. Similarly, the humeral condylar fracture was stabilized with two diverging 0.9 mm Kirschner wires (Figure 2).

Recovery from surgery was uneventful. The dog was discharged from the hospital 36 hours after surgery; tramadol was administered (2 mg/kg PO every 8 hrs) for 14 days. A carpal flexion bandage was placed to discourage weight-bearing. This bandage was maintained for 4 weeks, with weekly evaluations and bandage changes. Passive range-of-motion exercises for the shoulder and elbow were conducted three times daily by the owner, for the first 6 weeks postoperatively. Radiographic examination of the fractures was conducted at 25, 53, and 80 days postoperatively. The fractures had obtained radiographic union by 80 days. There were no complications associated with the implants, but there was mild progression of periarticular new bone formation on the proximal aspect of the olecranon and the cranioproximal aspect of the radial head.

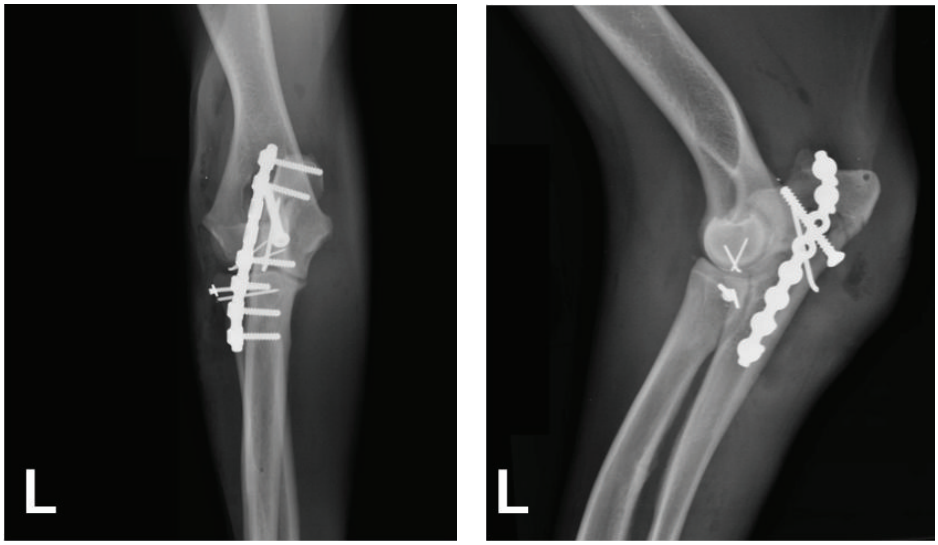

(a) (b)

Figure 2: Immediate postoperative craniocaudal (a) and lateral (b) radiographs of the left elbow of dog 1. A screw and a Kirschner wire have been placed across the olecranon fracture in a caudocranial direction. This fixation is supported by an eight-hole String-of-Pearls locking plate applied to the lateral olecranon and proximal ulnar diaphysis. Two divergent Kirschner wires are seen stabilizing the osseous fragment in the humeral capitulum. The self-compressing pin and Kirschner wire are seen stabilizing the fissure fracture of the proximal radius.

The owner was solicited to return the dog to the UF SAH for long-term evaluation, 5 years after surgery. There was no appreciable lameness or gait abnormality. The dog was comfortable on manipulation of the left elbow; small periarticular osteophytes were palpable, but the elbow was not effused. Range of motion of the left elbow (flexion = 25°, extension = 165°) was very similar to the right elbow (flexion = 20°, extension = 164°). Muscle atrophy was not evident with left brachial circumference (25.8 cm) being nearly identical to the right brachial circumference (25.9 cm). Gait was objectively evaluated by walking the dog on a force plate (Advanced Mechanical Technology Inc., Newton, MA, USA) and a pressure walkway (GAIT4Dog Walkway, Sparta, NJ, USA). Three successful trials were included for analysis. The mean peak vertical force (PVF) was slightly greater in the left (100.5 N/N) compared with the right (94.4 N/N) thoracic limb. The mean vertical impulse of the left (16.8 N-sec/N) and right (15.9 N-sec/N) thoracic limbs was also similar. The percentage of the gait cycle spent in the stance phase was again very similar between the left (59.8%) and right (61.3%) thoracic limbs. Radiographs obtained at this long-term evaluation revealed that the position of the implants was unchanged, with moderate osteophyte production and subchondral bone sclerosis of the ulnar trochlear notch, consistent with progression of elbow degenerative joint disease (Figure 3).

3. Case 2

A 7-year-old spayed female English Mastiff, weighing 71 kg, was examined at the UF SAH in July 2007 for left thoracic and left pelvic limb injuries, which were sustained in a road traffic accident. Radiographic examination of the left elbow revealed a closed, sagittally orientated, irregular olecranon fracture that extended from the proximal margin of the olecranon distally through the caudal articular margin of the ulnar trochlear notch, resulting in a cranially displaced segment that included the anconeal process. There was a 1.5 cm fusiform osseous fragment located adjacent to the lateral humeral epicondyle, as well as moderate soft tissue swelling present surrounding the elbow, with displacement of the periarticular fat planes, suggestive of joint effusion (Figure 4). A concurrent left tarsometatarsal fracture-luxation was found when the left pes was radiographed.

The olecranon fracture was exposed using a lateral approach [16]. The fracture was reduced directly and reduction was maintained with point-to-point reduction forceps; reduction was assessed fluoroscopically and adjusted until there was anatomic apposition at the articular margins. Under fluoroscopic guidance (Siremobil Compact Fluoroscope, Siemens, Iselin, NJ) in a manner similar to that done in dog 1, a 1.1 mm interfragmentary Kirschner wire was placed across the fracture line, in a caudodistal-to-cranioproximal direction, purchasing the anconeal process proximally and cranially. An additional 1.1 mm Kirschner wire was then placed in the same orientation, approximately 13 mm proximally to the first wire. The distal Kirschner wire was used to guide accurate placement of a screw perpendicular to the fracture line. Using a 3.5 mm cannulated drill bit (Arthrex, Naples, FL, USA) placed over the guide wire, the cisfracture segment was overdrilled; a drill sleeve was placed in the hole over the wire, and the transsegment was drilled using a 2.5 mm cannulated drill bit (Arthrex, Naples, FL, USA). After tapping threads in the transsegment, a 3.5 mm cortical screw with an associated washer was placed in lag fashion. In similar fashion, a second 3.5 mm cortical screw and washer was placed in lag fashion using the proximally placed Kirschner

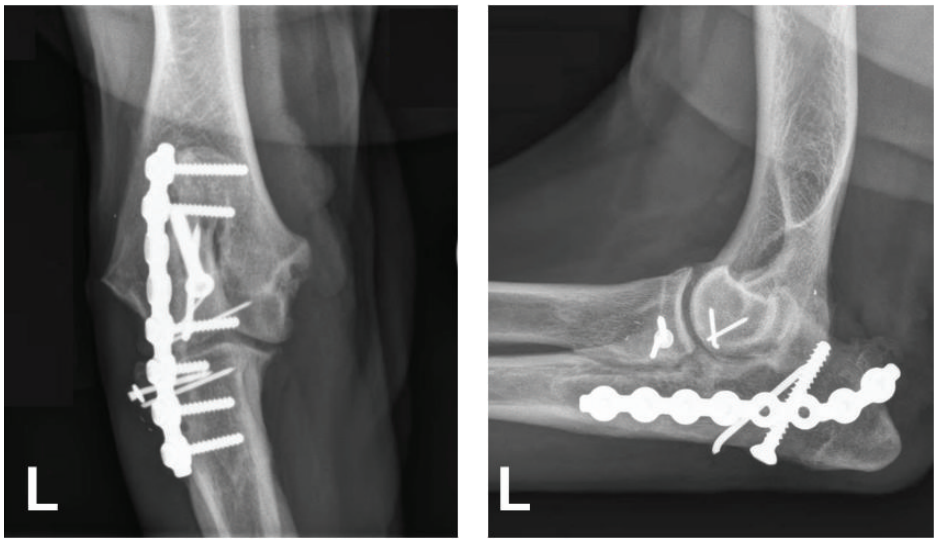

(a) (b)

Figure 3: Radiographs of the left elbow of dog 1 obtained 5 years postoperatively. Craniocaudal (a) and mediolateral (b) radiographs show unchanged implants with modeling at the proximal margin of the String-of-Pearls plate. Moderate osteophyte production is present at the cranial margin of the humeroradial joint and the medial aspect of the humeroulnar joint and along the proximal margin of the anconeal process. Also note the mild sclerosis of the ulnar trochlear notch, with evidence of joint space narrowing. These findings are compatible with progressive degenerative joint disease.

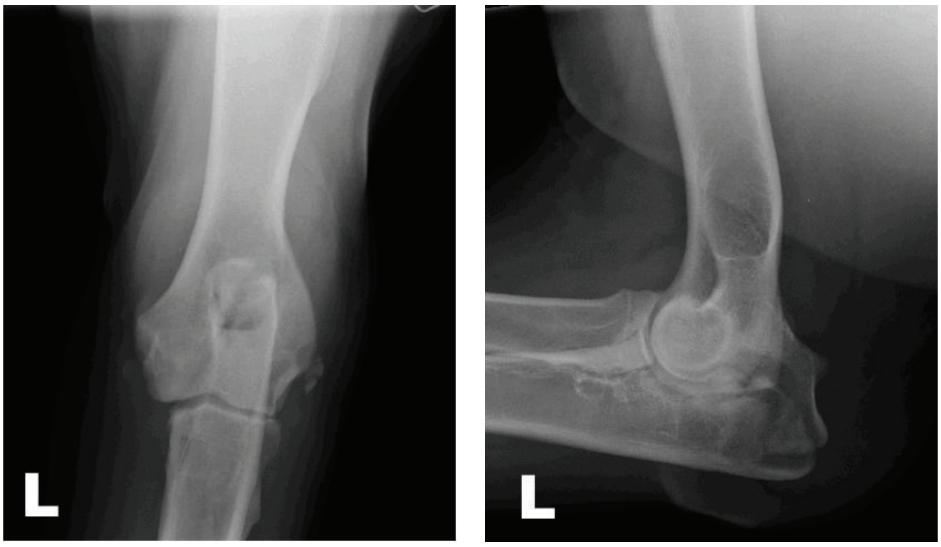

(a) (b)

Figure 4: Craniocaudal (a) and mediolateral (b) radiographs of the left elbow of dog 2 obtained preoperatively. A sagittally oriented, irregular fracture was seen extending from the caudoproximal aspect of the olecranon cranially through the caudal articular margin of the ulnar trochlear notch. This resulted in displacement of a proximal ulnar segment that included the olecranon and anconeal process. Note the fusiform osseous fragment associated with the lateral humeral epicondyle, best seen on the craniocaudal view. There is a small osteophyte located on the medial coronoid process consistent with mild preexisting osteoarthritis.

wire to guide the process. Three 2.7 mm positional screws with washers were then placed through the fracture in a medial-to-lateral direction for additional fracture stabilization (Figure 5). A partial tarsal arthrodesis was performed using a laterally applied 13-hole 3.5 mm dynamic compression plate to stabilize the left pes.

The dog was reevaluated 45 days postoperatively. There was no appreciable lameness or gait abnormality. The dog was comfortable on manipulation of the left elbow; small periarticular osteophytes were palpable, but the elbow was not effused. A small hygroma had developed over the caudal aspect of the olecranon; no discomfort was elicited

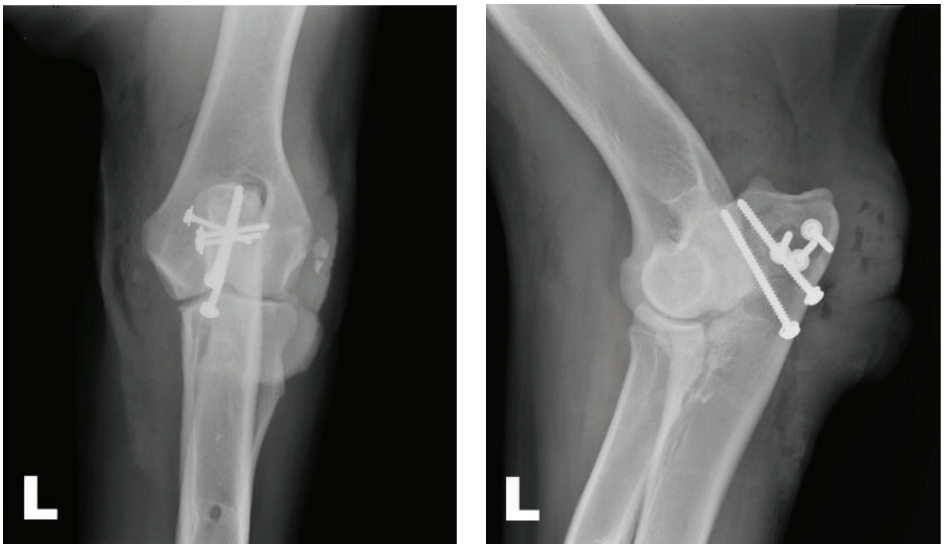

(a) (b)

Figure 5: Craniocaudal (a) and mediolateral (b) radiographs of the left elbow of dog 2 obtained immediately postoperatively. Two interfragmentary 3.5 mm screws with associated washers were placed in a caudodistal-to-cranioproximal orientation, purchasing the anconeal process proximally. Three additional interfragmentary 2.7 mm screws with associated washers were placed in a medial-to-lateral orientation.

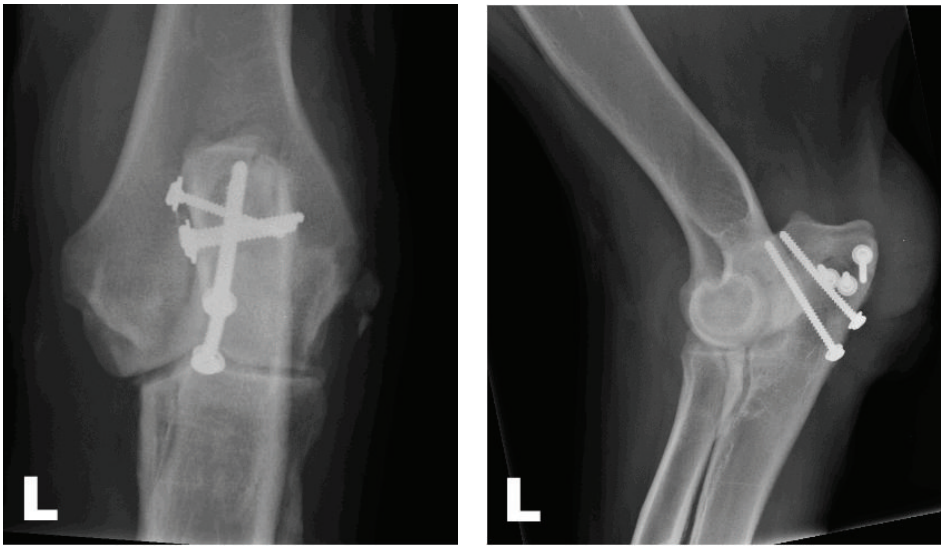

(a) (b)

Figure 6: Craniocaudal (a) and mediolateral (b) radiographs of the left elbow of dog 2 obtained 45 days postoperatively. The margins of the previously described sagittally orientated fracture line are now ill-defined, compatible with healing. Note the osteophyte production at the medial aspect of the humeroulnar joint and cranially at the level of the radial head. The hygroma is visible as soft tissue swelling, being caudal to the olecranon.

on palpation. Radiographically all implants remained stable (Figure 6). Only small regions of the initial fracture remained visible; however, the fracture had ill-defined margins and associated sclerosis, compatible with healing. Narrowing of the humeroulnar articulation was present, with associated sclerosis of the ulnar trochlear notch and early osteophyte formation at the medial aspect of the humeroulnar and the cranial aspect of the humeroradial articulations. The soft tissues surrounding the fracture as well as the elbow joint remained thickened. The dog did not return to the UF SAH for 15 months, when it presented for evaluation of mild swelling over the previous tarsometatarsal arthrodesis site. The tarsal arthrodesis plate and screws were removed due to implant loosening secondary to an associated infection. At that time, there was no appreciable thoracic limb lameness and thus no radiographic examination was performed. The left elbow had a normal range of motion, with no discomfort elicited on manipulation and no palpable effusion. Three and half years

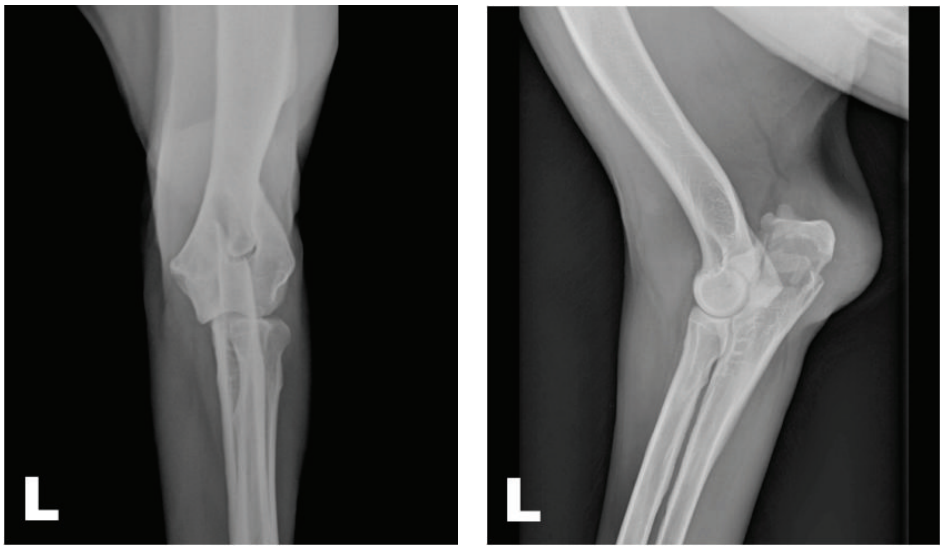

(a) (b)

Figure 7: Craniocaudal (a) and mediolateral (b) radiographs of the left elbow of dog 3 obtained preoperatively. A closed cranioproximal-to-caudodistally orientated olecranon fracture is seen extending into the ulnar trochlear notch. Comminution of the fracture resulted in cranial displacement of the anconeal process, seen best on the mediolateral radiograph.

after the initial fracture repair, the dog was examined by the UF Oncology Service and had a splenectomy to address splenic hemangiosarcoma. The dog was placed on a doxorubicin chemotherapeutic protocol and lived an additional 2 years before succumbing to the disease. No thoracic limb lameness or gait abnormalities were reported by the owner or observed by our Oncology Service up to the point of the dog's demise, 5.5 years following fracture repair.

4. Case 3

A 2-year-old intact male German shepherd, weighing 40 kg, presented to the UF SAH in April 2013 for evaluation of a non-weight-bearing lameness of the left thoracic limb, which was sustained in a road traffic accident. Preoperative radiographs and a computed tomographic (CT) scan showed a caudoproximal-to-craniodistally orientated, closed, comminuted olecranon fracture involving the articular margin of the ulnar trochlear notch, with cranioproximal displacement of the olecranon segment. The pattern of the fracture resulted in a comminution fragment that included the anconeal process, which was minimally, cranially displaced (Figure 7).

The fracture was exposed via a lateral approach [16], the proximal fracture segment, which included the olecranon tubercle, was directly reduced and reduction was maintained using point-to-point reduction forceps. Fluoroscopy (Ziehm Vision[2] FD, Ziehm Imaging, Nurnberg, Germany) was used, in the manner described in dog 1, to evaluate fracture reduction and to facilitate proper implant placement. Fracture fixation was accomplished by means of a laterally-to-medially directed 3.5 mm screw placed in lag fashion. The anconeal process was then anatomically reduced and held in reduction with point-to-point reduction forceps. Two 1.1 mm Kirschner wires were placed under fluoroscopic guidance, in a caudal-to-cranial direction. The distal Kirschner wire was used as a guide wire for a cannulated drill bit to place a 2.7 mm screw, with a washer, in lag fashion. The tip of this screw was advanced to partially engage the transcortex of the anconeal process, ensuring the screw did not protrude through the cortex, avoiding potential impingement in the olecranon fossa. This primary repair was augmented with a caudally applied, eight-hole 2.7 mm locking compression plate (DePuy Synthes, West Chester, PA, USA) with one locking and two cortical screws engaging the proximal segment and two cortical and three locking screws engaging the distal ulnar segment. An additional 1.1 mm Kirschner wire was then placed into the anconeal process, from caudal-to-cranial, under fluoroscopic guidance (Figure 8) and postoperative radiographs were obtained (Figure 9).

Recovery from surgery was uneventful; the dog was discharged the following day. Postoperative therapy included administration of carprofen (1.9 mg/kg PO every 12 hrs for 5 days), tramadol (2.5 mg/kg PO every 12 hrs for 7 days), and cephalexin (25 mg/kg PO every 12 hrs for 14 days). The referring veterinarian performed 1- and 2-month postoperative follow-up examinations. The dog was reported to be using the limb well, with no loss of reduction or fixation and appropriate healing was documented radiographically.

The dog was evaluated at the UF SAH 6 months postoperatively. At that time, the dog had developed a hygroma over the caudal aspect of the left olecranon but ambulated without appreciable lameness. The left elbow had a very similar range of motion (flexion = 26°, extension = 152°) when compared with the right elbow (flexion = 27°, extension = 153°). Mild left elbow joint osteophytosis was palpable. Muscle atrophy was not detected, with the left and right brachial circumference being identical at 25 cm. Gait was objectively evaluated by walking the dog on a force plate (Advanced Mechanical

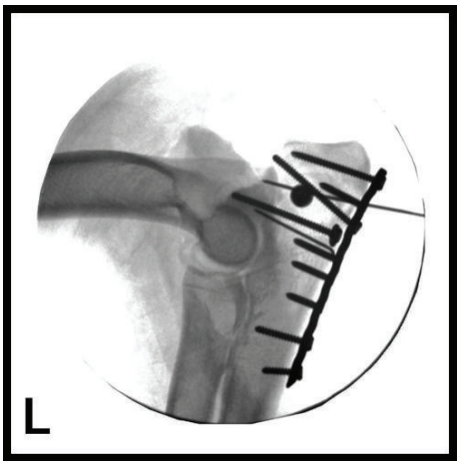

Figure 8: Mediolateral fluoroscopic image of the elbow of dog 3, acquired intraoperatively. This fluoroscopic image was used to assess proper placement of the proximal Kirschner wire in the anconeal process. Note the long protruding segment of the wire, which was subsequently cut adjacent to the caudal cortex of the ulna.

Technology Inc., Newton, MA, USA) and a pressure walkway (GAIT4Dog Walkway, Sparta, NJ, USA). Three successful trials were included for analysis. The mean PVF was found to be slightly decreased in left thoracic limb (123.3 N/N) compared with the right thoracic limb (134.3 N/N). The mean vertical impulse was also slightly decreased in the left (19.1 N-sec/N) compared to the right (21.1 N-sec/N) thoracic limb. The percentage of the gait cycle spent in the stance phase, however, was very similar between the left (60.7%) and right (60.0%) thoracic limbs. The mean pressure placed on the left thoracic limb (3.1 N/m^2) was also similar to the right thoracic limb (3.3 N/m^2).

Radiographic examination revealed osseous union of the olecranon tuber fracture (Figure 10). The anconeal component of the fracture, however, had not obtained union and had ill-defined, sclerotic margins. In addition, there was a fracture of the distal Kirschner wire and mild lucency surrounding the screw stabilizing the anconeal process, indicative of loosening. There was moderate sclerosis of the ulnar trochlear notch, with humeroulnar joint space narrowing. These changes were most severe at the level of the articular fracture and were compatible with healing and a component of degenerative joint disease. A large soft tissue mass was noted over the apex of the olecranon process, consistent with the clinically noted hygroma.

The dog was taken back to surgery and the previously placed plate and associated screws were removed. Under fluoroscopic guidance, the original 36 mm long, 3.5 mm screw in the anconeal process was replaced with a shorter (32 mm long) 3.5 mm screw. A shorter screw was used because there were concerns that the tip of the screw placed initially impinged on the cortical bone at the apex of the anconeal process, limiting the screw's ability to provide effective compression. The proximal and distal Kirschner wires in the anconeal process (apart from broken implanted segment) were removed. A 1.1 mm Kirschner wire was placed 11 mm proximally to the screw. This wire served as a guide wire for drilling a hole to place a second 3.5 mm cortical screw in lag fashion (Figure 11).

Follow-up examination 2 months later (8 months after the initial surgery) revealed mild left thoracic limb lameness. Moderate left elbow effusion and mild fibrosis were palpable. On radiographic examination, the fracture involving the anconeal process persisted, with widening of the fracture gap and loosening of the distal screw (Figure 12). Both screws were removed under fluoroscopic guidance.

The dog was reevaluated 14 months after the initial surgery and was not appreciably lame. Pain was not elucidated on manipulation of the left elbow and there was no palpable effusion. Range of motion in the left elbow (flexion = 27°, extension = 155°) was again very similar to the right elbow (flexion = 21°, extension = 157°). No appreciable muscle atrophy was palpable with right (23.6 cm) and left (23.9 cm) brachial circumference measurements being similar. Gait was again objectively evaluated by walking the dog on a force plate (Advanced Mechanical Technology Inc., Newton, MA, USA) and a pressure walkway (GAIT4Dog Walkway, Sparta, NJ, USA), with three successful trials included for analysis. The mean PVF was found to be slightly decreased in left thoracic limb (103.5 N/N) compared with the right thoracic limb (107.9 N/N). The mean vertical impulse was also slightly decreased in the left (14.5 N-sec/N) compared to the right (16.2 N-sec/N) thoracic limb. The percentage of the gait cycle spent in the stance phase, however, was very similar between the left (64.6%) and right (64.9%) thoracic limbs. The mean pressure placed on the left thoracic limb (3.9 N/m^2) was also similar to the right thoracic limb (3.7 N/m^2).

5. Discussion

Despite widespread application in human orthopedic surgery [5–9], and an apparent increased usage in small animal surgery [15], reports detailing the results associated with fluoroscopic-assisted fracture stabilization in dogs are limited. Intraoperative fluoroscopy has been shown to be advantageous for assessing fracture reduction and facilitating accurate implant placement in human patients [6]. Previous work has described the use of fluoroscopy to aid in closed reduction and lag screw fixation of humeral condylar fractures in dogs [10], to assist in the placement of transilial rods or lag screws in dogs with sacroiliac luxation [11, 12], and for the application of external skeletal fixation in dogs with vertebral column [13] and appendicular long bone trauma [17, 18].

One major challenge associated with open reduction and internal fixation of olecranon fractures, utilizing a standard lateral approach [16], is the ability to fully visualize the articular margins of the fracture. Despite adequate soft tissue dissection and retraction, the capitulum and lateral epicondylar crest of the humerus overlies the trochlear notch, often restricting visualization of the fracture margins. We found that fluoroscopy was useful for assessing our initial fracture reduction, prompting improvement if necessary. Recognizing and correcting inaccuracies in reduction at the articular surface help mitigate abnormal cartilage wear and the development of posttraumatic osteoarthritis [19].

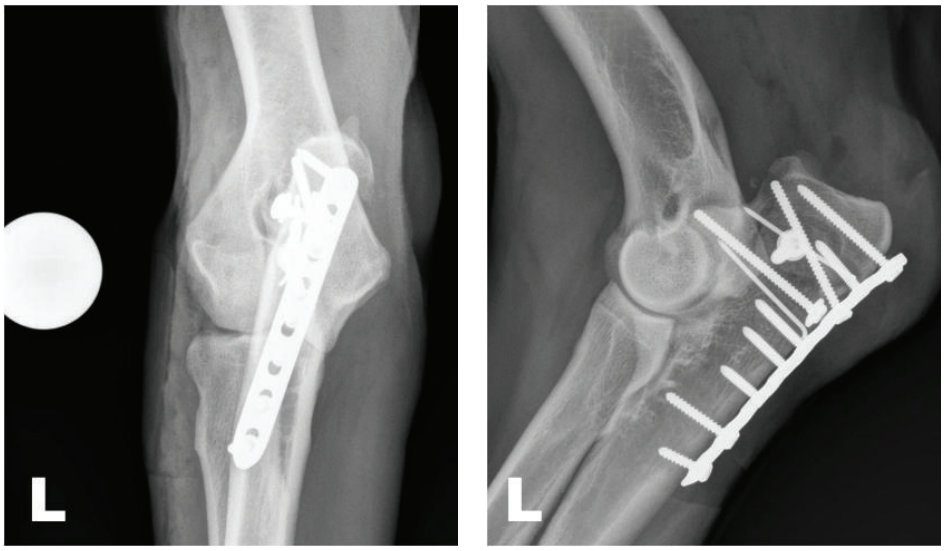

(a) (b)

Figure 9: Craniocaudal (a) and mediolateral (b) radiographs of the left elbow of dog 3 obtained immediately postoperatively. The olecranon fracture was repaired with a laterally-to-medially directed screw, inserted in lag fashion. The anconeal process is stabilized with one screw inserted in lag fashion and two Kirschner wires, inserted in a caudal-to-cranial orientation. This repair was augmented with a caudally applied eight-hole 2.7 mm locking compression plate, with three screws engaging the proximal olecranon segment and five screws engaging the distal segment.

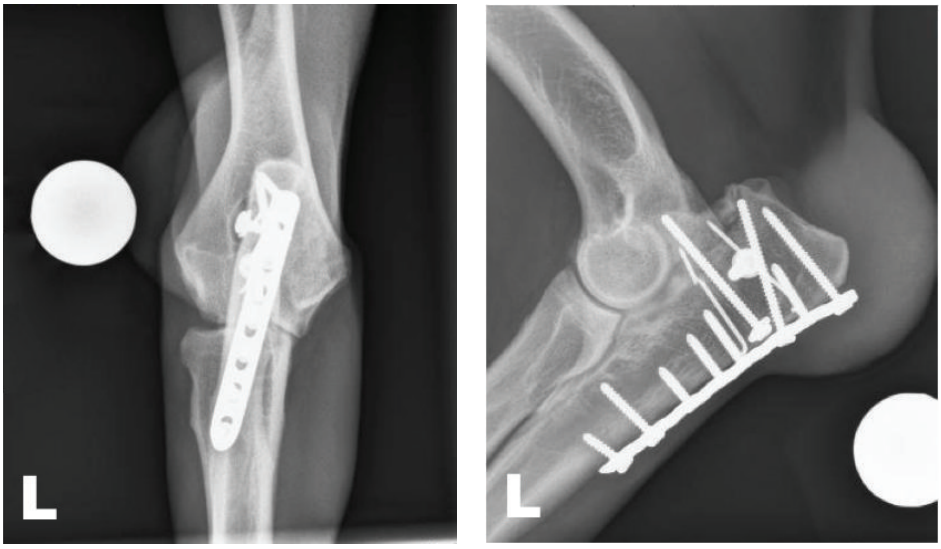

(a) (b)

Figure 10: Craniocaudal (a) and mediolateral (b) radiographs of the left elbow of dog 3 obtained 6 months postoperatively. The fracture associated with the olecranon tuber is fully healed. The fracture margin associated with the anconeal process, however, remains visible, with ill-defined, sclerotic margins, indicating a nonunion. Note the lucency around the lag screw in the anconeal process and the fractured Kirschner wire seated distally in the anconeal process.

In agreement with previous findings [4], all three olecranon fractures in this report had articular involvement. In addition to assisting with accurate fracture reduction, intraoperative fluoroscopy was useful in facilitating appropriate implant placement. Accurate positioning of the Kirschner wires and the use of cannulated drill bits facilitated accurate screw placement in the small juxta-articular and articular fracture segments [20]. Given that all three fractures in this report had articular components, placing the interfragmentary lag screws perpendicular to the fracture line was considered optimal to prevent a loss of reduction as the screws were tightened. Apart from the nonunion of the anconeal process

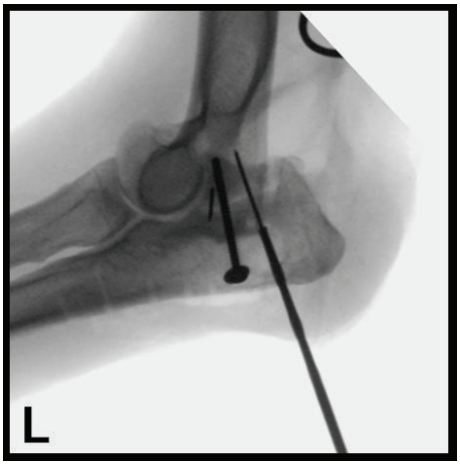

Figure 11: Mediolateral intraoperative fluoroscopic image of the elbow of dog 3. The previously placed caudal ulnar plate and associated screws have been removed. A new Kirschner wire has been placed to function as a guide wire to assist placement of an additional screw. Note the cannulated drill bit inserted over the guide wire, ensuring that the drill-tract and subsequently the screw are appropriately positioned.

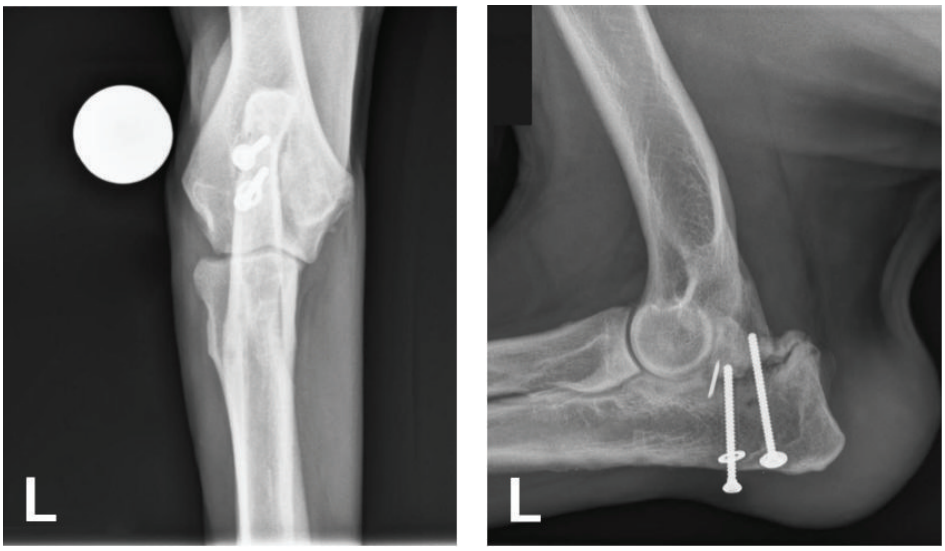

(a) (b)

Figure 12: Craniocaudal (a) and mediolateral (b) radiographs of the left elbow of dog 3 obtained 8 months postoperatively. The fracture margin associated with the anconeal process is widened when compared with previous radiographs, with ill-defined, sclerotic margins. The distal screw has loosened.

in the third dog, the fractures appeared to undergo primary bone healing with limited callus formation.

There are biomechanical advantages to both caudal and lateral plate placement when stabilizing the proximal ulna [21]. In further agreement with the findings of Muir and Johnson we found that the use of a caudally or laterally applied ulnar plate was not associated with any implant failure or fracture-healing complications [4]. The proximal fracture fragment in dog 2 was prohibitively small to permit application of a plate. Placement of multiple interfragmentary screws, however, provided sufficient stability to allow this fracture to achieve union.

In the third dog, the olecranon tubercle fracture healed, but the anconeal process did not obtain radiographic union. Recent reports suggest that optimal treatment for younger dogs with an ununited anconeal process (UAP) involves lag screw fixation in conjunction with proximal ulnar osteotomy [22, 23]. This method of treatment theoretically reduces excessive contact pressure on the anconeal process and addresses contributing elbow incongruity, while simultaneously permitting reduction and compression of the UAP [23]. The anconeal process is considered to be the primary stabilizer of the dog's elbow when the joint is subjected to pronation and is considered a secondary stabilizer when the joint is subjected to supination [24]. These findings suggest that the anconeal process is subjected to large torque moments during ambulation, and our fixation of the anconeal process was likely inadequate in dog 3. Neither the lag screw nor

the interfragmentary Kirschner wires fully engaged the transcortex of the anconeal process, as we did not want these implants to penetrate the articular surface. This may have reduced fracture stability and contributed to the development of the nonunion. Similarly, a previous study found that stabilization of an UAP by placement of a lag screw alone resulted in failure of apophyseal fusion in 8 out of 9 joints [25]. Although UAP is a developmental disease and thus has a different etiology than the traumatic anconeal fracture presented in dog 3, the poor fusion rate [25] highlights the need for rigid fixation to neutralize the large forces exerted on the anconeal process during daily activities. In retrospect, we may have achieved a better outcome if we had initially placed two screws in the anconeal process, with both screws fully engaging the transcortex.

Development of mild to moderate posttraumatic osteoarthritis was documented in all dogs in this report, corroborating findings of previous reports [4, 19]. Varitimidis et al. reported that concomitant arthroscopic and fluoroscopically assisted articular radial fracture repair in human patients helped guide fracture reduction and was associated with improved clinical outcomes, when compared with fluoroscopic assistance only [8]. Patients in that study treated with arthroscopic and fluoroscopic assistance were found to have improved supination, flexion, and extension at all time points, compared with those patients in which only fluoroscopy was used [8]. The feasibility of incorporating closed arthroscopic reduction in dogs thus warrants investigation. The clinical outcome of the three dogs in this report was considered successful, despite the progression of osteoarthritis, even in the third dog in which the anconeal process fracture did not obtain union. All dogs were subjectively free of lameness at the time of the last documented follow-up examination. Our observations in all three dogs were supported by objective assessments of limb function in the first and third dogs.

This report is limited by its retrospective nature, which restricted our ability to obtain standardized outcomes over defined time points for each dog. In addition, we do not have a control group of dogs with similar fractures, managed without fluoroscopic-assisted surgery, for comparison. A further limitation of this report is the small number of dogs, precluding valid statistical comparison of fixation methods and clinical outcomes.

The use of intraoperative fluoroscopy allowed us to confirm anatomic fracture reduction intraoperatively and facilitated accurate implant placement. Anatomic reduction and stable fixation of these articular fractures permitted a successful return to function without appreciable lameness at the time of long-term follow-up evaluation in all three dogs.

Abbreviations

UAP: Ununited anconeal process
UF SAH: University of Florida Small Animal Hospital.

Conflict of Interests

The authors declare that there is no conflict of interests regarding the publication of the paper.

Acknowledgment

The authors would like to acknowledge the assistance of Ms. Debby Sundstrom in the collection of objective gait data and in the preparation of the figures.

References

[1] H. E. Evans and A. de Lahunta, "The skeleton," in *Miller's Anatomy of the Dog*, H. E. Evans and A. de Lahunta, Eds., pp. 134–136, Elsevier Saunders, St. Louis, Mo, USA, 4th edition, 1996.

[2] I. R. Phillips, "A survey of bone fractures in the dog and cat," *Journal of Small Animal Practice*, vol. 20, no. 11, pp. 661–674, 1979.

[3] P. Muir and P. A. Manley, "Stabilisation of fractures of the proximal radius and ulna in a dog by application of a single plate to the ulna," *Veterinary Record*, vol. 134, no. 23, pp. 599–601, 1994.

[4] P. Muir and K. A. Johnson, "Fractures of the proximal ulna in dogs," *Veterinary and Comparative Orthopaedics and Traumatology*, vol. 9, no. 2, pp. 88–94, 1996.

[5] M. S. H. Beerekamp, G. S. I. Sulkers, D. T. Ubbink, M. Maas, N. W. L. Schep, and J. C. Goslings, "Accuracy and consequences of 3D-fluoroscopy in upper and lower extremity fracture treatment: a systematic review," *European Journal of Radiology*, vol. 81, no. 12, pp. 4019–4028, 2012.

[6] B. L. Norris, D. H. Hahn, M. J. Bosse, J. F. Kellam, and S. H. Sims, "Intraoperative fluoroscopy to evaluate fracture reduction and hardware placement during acetabular surgery," *Journal of Orthopaedic Trauma*, vol. 13, no. 6, pp. 414–417, 1999.

[7] B. Carelsen, R. Haverlag, D. T. Ubbink, J. S. K. Luitse, and J. C. Goslings, "Does intraoperative fluoroscopic 3D imaging provide extra information for fracture surgery?" *Archives of Orthopaedic and Trauma Surgery*, vol. 128, no. 12, pp. 1419–1424, 2008.

[8] S. E. Varitimidis, G. K. Basdekis, Z. H. Dailiana, M. E. Hantes, K. Bargiotas, and K. Malizos, "Treatment of intra-articular fractures of the distal radius," *The Journal of Bone & Joint Surgery—British Volume*, vol. 90, no. 6, pp. 778–785, 2008.

[9] M. Kraus, S. von dem Berge, H. Schöll, G. Krischak, and F. Gebhard, "Integration of fluoroscopy-based guidance in orthopaedic trauma surgery—a prospective cohort study," *Injury*, vol. 44, no. 11, pp. 1486–1492, 2013.

[10] J. L. Cook, J. L. Tomlinson, and A. L. Reed, "Fluoroscopically guided closed reduction and internal fixation of fractures of the lateral portion of the humeral condyle: prospective clinical study of the technique and results in ten dogs," *Veterinary Surgery*, vol. 28, no. 5, pp. 315–321, 1999.

[11] J. L. Tomlinson, J. L. Cook, J. T. Payne, C. C. Anderson, and J. C. Johnson, "Closed reduction and lag screw fixation of sacroiliac luxations and fractures," *Veterinary Surgery*, vol. 28, no. 3, pp. 188–193, 1999.

[12] C. S. Leasure, D. D. Lewis, C. W. Sereda, K. L. Mattern, C. T. Jehn, and J. L. Wheeler, "Limited open reduction and stabilization of sacroiliac fracture-luxations using fluoroscopically assisted placement of a trans-iliosacral rod in five dogs," *Veterinary Surgery*, vol. 36, no. 7, pp. 633–643, 2007.

[13] J. L. Wheeler, D. D. Lewis, A. R. Cross, and C. W. Sereda, "Closed fluoroscopic-assisted spinal arch external skeletal fixation for the stabilization of vertebral column injuries in five dogs," *Veterinary Surgery*, vol. 36, no. 5, pp. 442–448, 2007.

[14] C. A. Tonks, J. L. Tomlinson, and J. L. Cook, "Evaluation of closed reduction and screw fixation in lag fashion of sacroiliac fracture-luxations," *Veterinary Surgery*, vol. 37, no. 7, pp. 603–607, 2008.

[15] B. S. Beale and A. Pozzi, "Minimally invasive fracture repair," *Veterinary Clinics of North America—Small Animal Practice*, vol. 42, no. 5, pp. 963–1096, 2012.

[16] D. L. Piermattei and K. A. Johnson, "The forelimb," in *An Atlas of Surgical Approaches to the Bones and Joints of the Dog and Cat*, D. L. Piermattei and K. A. Johnson, Eds., pp. 186–189, Saunders, Philadelphia, Pa, USA, 4th edition, 2012.

[17] J. P. Farese, D. D. Lewis, A. R. Cross, K. E. Collins, G. M. Anderson, and K. B. Halling, "Use of IMEX SK-circular external fixator hybrid constructs for fracture stabilization in dogs and cats," *Journal of the American Animal Hospital Association*, vol. 38, no. 3, pp. 279–289, 2002.

[18] K. A. Kirby, D. D. Lewis, M. P. Lafuente et al., "Management of humeral and femoral fractures in dogs and cats with linear-circular hybrid external skeletal fixators," *Journal of the American Animal Hospital Association*, vol. 44, no. 4, pp. 180–197, 2008.

[19] W. J. Gordon, M. F. Besancon, M. G. Conzemius, K. G. Miles, A. S. Kapatkin, and W. T. N. Culp, "Frequency of post-traumatic osteoarthritis in dogs after repair of a humeral condylar fracture," *Veterinary and Comparative Orthopaedics and Traumatology*, vol. 16, no. 1, pp. 1–5, 2003.

[20] D. D. Lewis, "Femoral neck fracture repair," in *Small Animal Orthopedics, Rheumatology and Musculoskeletal Disorders*, D. D. Lewis and S. J. Langley-Hobbs, Eds., pp. 113–114, CRC Press, Boca Raton, Fla, USA, 2nd edition, 2014.

[21] D. D. Lewis and S. J. Langley-Hobbs, "Olecranon fracture repair," in *Small Animal Orthopedics, Rheumatology and Musculoskeletal Disorders*, D. D. Lewis and S. J. Langley-Hobbs, Eds., pp. 55–56, CRC Press, Boca Raton, Fla, USA, 2nd edition, 2014.

[22] U. Krotscheck, D. A. Hulse, A. Bahr, and R. M. Jerram, "Ununited anconeal process: lag-screw fixation with proximal ulnar osteotomy," *Veterinary and Comparative Orthopaedics and Traumatology*, vol. 13, no. 4, pp. 212–216, 2000.

[23] R. A. Pettitt, J. Tattersall, T. Gemmill et al., "Effect of surgical technique on radiographic fusion of the anconeus in the treatment of ununited anconeal process," *Journal of Small Animal Practice*, vol. 50, no. 10, pp. 545–548, 2009.

[24] K. W. Talcott, K. S. Schulz, P. H. Kass, D. R. Mason, and S. M. Stover, "In vitro biomechanical study of rotational stabilizers of the canine elbow joint," *American Journal of Veterinary Research*, vol. 63, no. 11, pp. 1520–1526, 2002.

[25] A. Meyer-Lindenberg, I. Nolte, and M. Fehr, "The ununited anconeal process: retro- and prospective investigations on surgical treatment," *Tierarztliche Praxis Ausgabe K: Kleintiere Heimtiere*, vol. 27, no. 5, pp. 309–320, 1999.





Hindawi

Submit your manuscripts at
http://www.hindawi.com