Persistent smear positivity for *Mycobacterium tuberculosis* in a patient with occult malignancy

Sir:

The recent increase in prevalence of tuberculosis (TB) in North America and the emergence of multiple drug resistant strains has stimulated renewed interest in the characterization and treatment of TB. This resurgence in North America may be largely attributed to increased immigration from endemic areas, the emergence of human immunodeficiency virus (HIV) infection, inadequate living conditions and poor access to health care. However, the clinical course of the patient described below serves as a reminder that TB need not be associated with these widely appreciated risk factors, and careful investigation and follow-up may be necessary to reveal the cause of host immune defence impairment.

The patient is a 56-year-old white male with a 25 pack-a-year smoking history. He has a longstanding history of chronic cough productive of mucoid sputum consistent with chronic bronchitis. The patient was referred for assessment after a six-month history of involuntary weight loss of over 5 kg and an increase in mucopurulent sputum production. An incidental chest radiograph (Figure 1) demonstrated extensive diffuse nodular infiltrates in the left upper lung field, associated with volume loss and pleural thickening. Moderate right upper lobe infiltrates were also noted. A sputum stain was strongly positive on both the acid fast bacilli (AFB) stain and direct fluorescent antibody (DFA) stain for mycobacterium. Subsequent culture confirmed *Mycobacterium tuberculosis*, which was sensitive to all the conventional antituberculous agents. An HIV test was negative, and complete blood count and baseline liver function tests were normal. It was determined that the patient was born in Canada, with no significant travel history, and he was not on any immunosuppressive drugs. Other than the weight loss, there was no history of malignancy or diabetes mellitus. There was no other past medical history except for a moderate amount of alcohol consumption on a regular basis. His wife had TB 10 years ago, for which she completed a successful course of antituberculous therapy. The patient did not receive isoniazid prophylaxis and he denied any history of TB.

He was started on a standard course of triple TB medications – isoniazid (300 mg/day), rifampin (600 mg/day) and pyrazinamide (25 mg/kg/day) plus vitamin B6 (25 mg/day), which he tolerated well. Compliance was ensured by bimonthly follow-up and dispensing of TB medications at three-month intervals plus regular home visits and surveillance of pill supplies by a public health nurse.

During the initial course of nine months of therapy he continued to smoke and consume a considerable amount of alcohol. However, he gained weight, with noted improvement in energy level and significant reduction in sputum production. Serial follow-up chest radiographs revealed complete clearing of his right lung field infiltrate and partial clearing on the left side with some residual 'scarring'. Serial sputum specimens were consistently positive on AFB and DFA stains but extended 12-week cultures throughout therapy remained negative. Triple antituberculous therapy was maintained for a total of 27 months because of smear-positive sputum. Atypical mycobacterium was never isolated in over 15 sputum cultures. The clinical suspicion of the prolonged sputum smear positivity was host impairment due to chronic alcohol use.

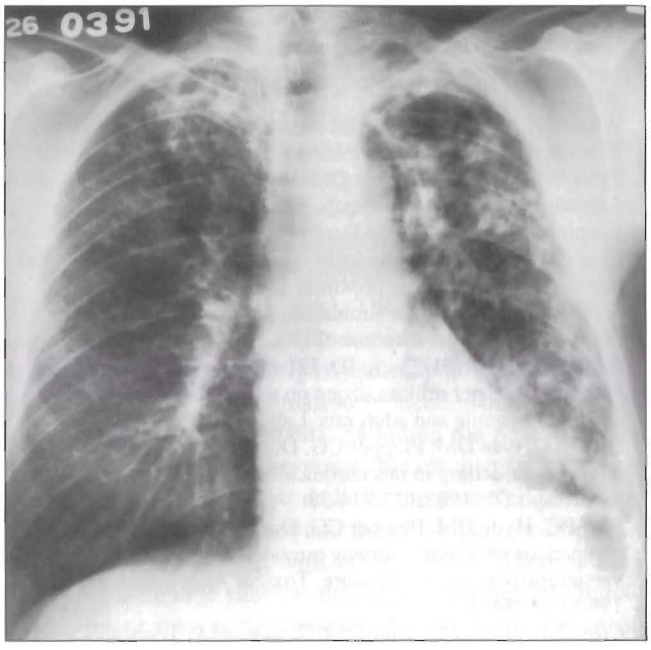

Figure 1) *Chest radiograph of patient, demonstrating extensive diffuse nodular infiltrates in the left upper lung*

Twenty-seven months after initiating antituberculous treatment, the patient developed abdominal pain and anorexia. Subsequent investigations revealed a squamous cell carcinoma of the pancreas with hepatic metastases. AFB/DFA stains and mycobacterial cultures were negative on the pancreatic biopsy. The patient did not develop any other opportunistic infections.

This patient was treated with standard dosages of triple therapy for TB. Compliance was satisfactory but despite a very prolonged course of bactericidal therapeutic regimen for TB, he failed to achieve sputum conversion. The mycobacterial disease was clinically and radiologically controlled throughout the 27-month treatment interval. Despite the failure of sputum smear conversion, cultures were consistently

negative even on 12-week extended cultures. No resistance strain was grown and no atypical mycobacterium was grown on over 15 cultures. Although no apparent immunosuppressive factors were identified, the unusual clinical course was highly suggestive of impairment in the underlying host immune system. Ongoing smoking with chronic bronchitis and alcohol consumption are likely to have been important adverse factors but the occult malignancy is probably a significant factor for immunological impairment.

Although there have been only limited retrospective reviews of TB in malignancy, several studies have demonstrated an increased occurrence of TB in the general population (1,2). TB is felt to be most prevalent in lymphoma and lung cancer (2), although increased incidence has been described in other neoplasms.

Prolonged suppression of cell mediated immunity is a significant risk factor for mycobacterial infections. Along with patients with AIDS, cancer patients have significant impairment to their cell mediated immunity. This case serves as a reminder that careful observation of patients with difficult to eradicate TB with no gross immunosuppressive disease may in fact reveal occult immunosuppression due to underlying malignancy.

REFERENCES

1. Ortbals DW, Marr JJ. A comparative study of tuberculosis and other mycobacterial infections and their associations with malignancy. Am Rev Respir Dis 1978;117:39-45.
2. Kaplan MH, Armstrong D, Rosen P. Tuberculosis complicating neoplastic disease: a review of 201 cases. Cancer 1974;33:850-58.
3. Wilson CB. The cellular immune system and its role in host defense. In: Mandeff GL, Douglas RG, Bennett JE, eds. Principles and Practice of Infectious Diseases, 3rd edn. New York: Churchill Livingstone, 1990:101-38.

Willis H Tsai MD
John Bohnen MD FRCSC FACS
Charles K Chan MD FRCPC FCCP FACP
The Wellesley Hospital, University of Toronto
Toronto, Ontario



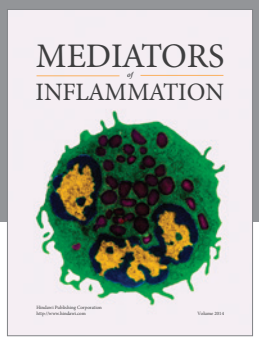

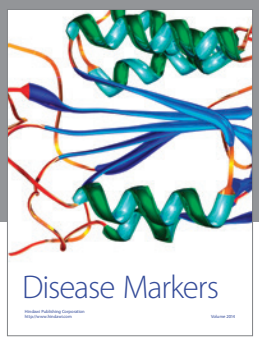



Hindawi
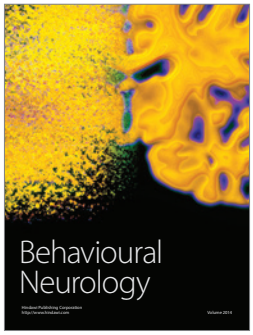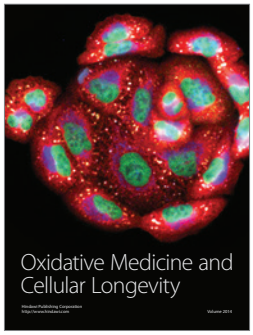
Submit your manuscripts at
http://www.hindawi.com