

Orthodeoxia and platypnea secondary to a patent foramen ovale despite normal right-sided cardiac pressures

Mark Varkul MD FRCPC¹, Trevor Robinson MD², Elane Ng MD³, Robert Hyland MD FRCPC⁴
¹*Division of Respiriology, Department of Medicine, University of Toronto;* ²*Division of Cardiology, Department of Medicine, St Michael's Hospital;* ³*Department of Anaesthesia, University of Toronto;* ⁴*Division of Respiriology, Department of Medicine, St Michael's Hospital, Toronto, Ontario*

M Varkul, T Robinson, E Ng, R Hyland. Orthodeoxia and platypnea secondary to a patent foramen ovale despite normal right-sided cardiac pressures. Can Respir J 2001;8(2):105-107.

Numerous cases of orthodeoxia and platypnea have been reported. Some have been found to be due to intracardiac shunts despite normal intracardiac pressures. In the case presented, a 79-year-old woman was noted to have orthodeoxia and platypnea secondary to a patent foramen ovale (PFO) despite normal intracardiac pressures. She recovered after closure of the PFO. The authors postulate that recent vertebral fractures and subsequent kyphosis, as well as a dilated thoracic aorta, altered intrathoracic relationships and may have led to a stream of venous return being directed across the PFO in the upright position, despite normal intracardiac pressures.

Key Words: *Atrial septal defect; Orthodeoxia; Patent foramen ovale; Platypnea; Shunt*

Syndrôme de platypnée-orthodéoxie secondaire à un foramen ovale perméable malgré des pressions cardiaques droites normales

RÉSUMÉ : De nombreux cas de platypnée-orthodéoxie ont déjà été signalés. Certains seraient attribuables à des shunts intracardiaques, malgré des pressions intracardiaques normales. Voici le cas d'une femme de 79 ans souffrant de platypnée-orthodéoxie secondaire à un foramen ovale perméable (FOP), et ce, malgré des pressions intracardiaques normales; la fermeture du FOP a permis de corriger le syndrome. Les auteurs croient que des fractures vertébrales récentes ayant entraîné une cyphose ainsi qu'une dilatation de l'aorte thoracique auraient altéré l'hémodynamique intrathoracique et auraient causé un retour veineux dans le FOP lorsque la patiente était en position debout, et ce, malgré des pressions intracardiaques normales.

Platypnea and orthodeoxia are dyspnea and arterial desaturation that occur with the assumption of an upright posture and are relieved by recumbency. The first case was described in 1949 (1). Since then, a number of case reports

have been published. Typically, this phenomenon has been attributed to vascular shunts at the lung bases, as noted by Robin et al (2). The upright position results in increased blood flow to the lung bases (by gravitational effect), exacer-

St Michael's Hospital (Wellesley and Bond site), Toronto, Ontario

Correspondence and reprints: Dr R Hyland, St Michael's Hospital, 30 Bond Street, Toronto, Ontario M5B 1W8. Telephone 416-864-5811, fax 416-864-6034, e-mail hylandb@smh.toronto.on.ca

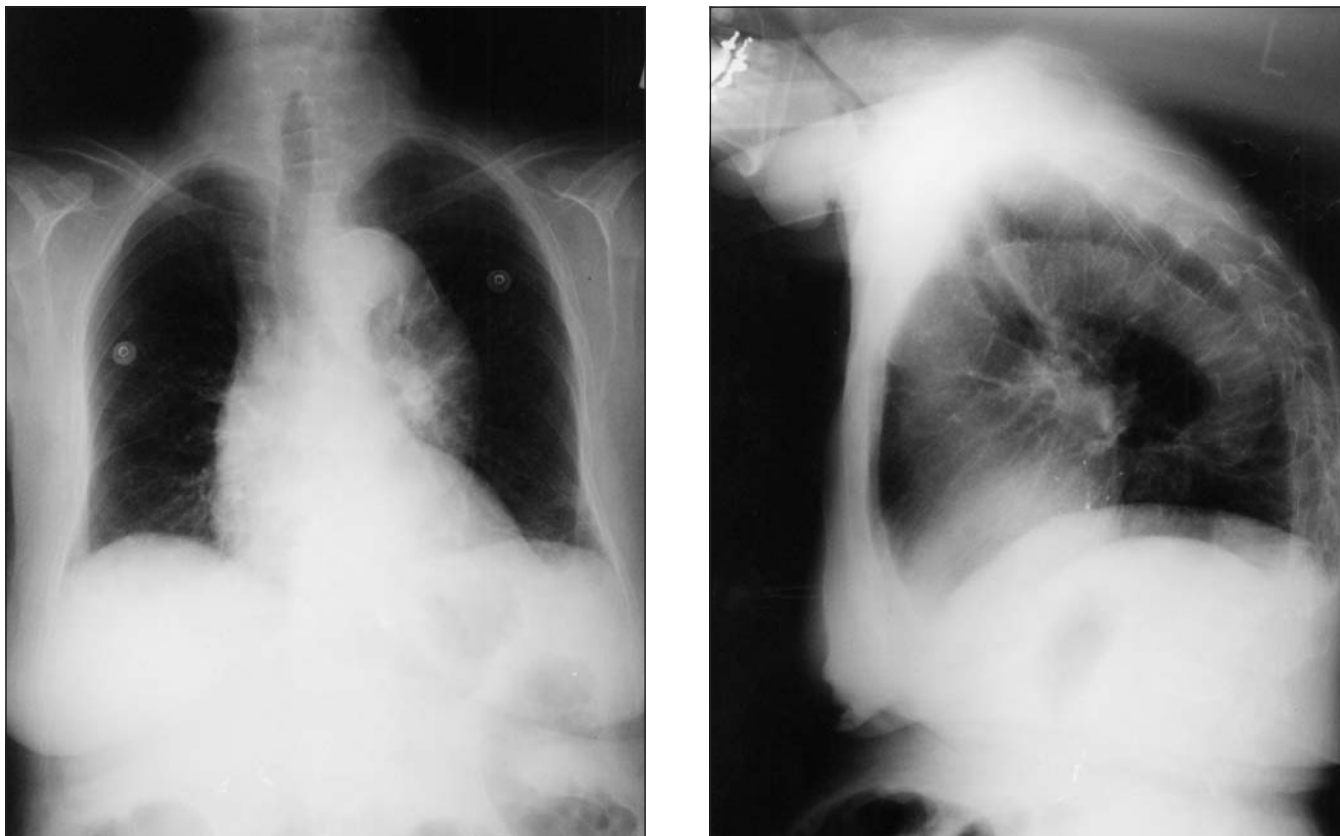


Figure 1) Chest roentgenogram of a 79-year-old female patient. **Left** Posterior-anterior view. **Right** Lateral view

bating the shunting. However, this phenomenon has also been attributed to intracardiac shunts. The mechanism of right to left shunting through the heart is well understood when right-sided cardiac pressures are increased, such as in severe chronic obstructive pulmonary disease, pulmonary emboli and congenital cardiac defects. The mechanism of right to left shunting is not as clear in cases where right-sided pressures are normal. It is also not certain why shunting increases when these patients change from a supine to an upright position. The following case is one of a few cases in the literature in which orthodeoxia and platypnea were found to be secondary to a patent foramen ovale (PFO) in the presence of normal right-sided cardiac pressures.

CASE PRESENTATION

A 79-year-old woman was admitted to hospital with intractable back pain secondary to osteoporotic vertebral fractures. Up until six months before admission, she had been quite active without any symptoms. Since then, she had complained of increasing difficulty with daily activities, but attributed this to her back discomfort. She denied significant cardiorespiratory symptoms. In hospital, she was noted to have orthodeoxia and platypnea. Her past medical history included inactive rheumatoid arthritis, hypertension and osteoporosis. Her medications on admission were enalapril, calcitonin, calcium and vitamin D. She had been a lifelong nonsmoker and denied alcohol use.

On examination, her heart rate was 90 beats/min and

her blood pressure was 120/70 mmHg. Her oxygen saturation was noted to fall from 98% to 80% when she sat up from a supine posture, associated with an increase in her respiratory rate from 15 to 28 breaths/min. Breath sounds were normal throughout her lung fields. Her pulses were normal. Her jugular veins were not distended and her heart sounds were felt to be normal, with no murmurs. Abdominal examination was normal, with no evidence of chronic liver disease.

Routine blood work, including liver enzymes and function, was normal. Chest x-ray revealed an ectatic aorta with normal lung parenchyma and multiple thoracic vertebral fractures with kyphosis (Figure 1). Computed tomography scans of the chest revealed no significant parenchymal abnormality. A two-dimensional echocardiogram with contrast showed the contrast appearing in the right heart and subsequently in the left atrium, which was best explained by a PFO. Hemodynamic assessment revealed normal pressures: right atrium 12/5 mmHg (mean 8 mmHg), right ventricle 26/8 mmHg (mean 15 mmHg) and pulmonary artery 29/14 mmHg (mean 19 mmHg). No intrapulmonary shunts were seen. A transesophageal echocardiogram revealed a PFO through which contrast was clearly moving from the right atrium to the left atrium. Her PFO was closed via cardiac catheterization using a clam shell device (3), with immediate resolution of her orthodeoxia and platypnea. There was some residual right to left shunting, but it was not clinically significant.

DISCUSSION

This case is one of a few in the literature that describe orthodeoxia and platypnea secondary to a right to left intracardiac shunt in the presence of normal right-sided cardiac pressures. Much of the discussion in the literature regarding how such shunting is possible suggests that venous return via the inferior vena cava (IVC) may be directed in a stream through the septal defect, without the need for a pressure gradient (4-10). In certain instances, a eustachian valve at the IVC-right atrial junction has been found to explain the directed blood flow (4). In circumstances where these valves are not present, other mechanisms have been postulated to alter the orientation of venous return and the atrial septal defect to facilitate shunting. In one case, a pericardial effusion was postulated to do this by distorting the right atrium (5). In two cases, an ectatic aorta was thought to distort the heart and facilitate shunting of venous return across a PFO (6,7). On two occasions (4,7), vertebral fractures and subsequent kyphosis were hypothesized to alter intrathoracic relationships to facilitate shunting. This mechanism of an altered intrathoracic anatomy has also been proposed to occur after pneumonectomy (8-10). It is suggested that the upright position may exaggerate these intrathoracic changes facilitating IVC blood to be directed across the PFO, resulting in orthodeoxia and platypnea.

In the present case, the platypnea and orthodeoxia were noted with the occurrence of multiple vertebral fractures. The patient was also noted to have a dilated thoracic aorta. It is possible that these two factors altered the orientation of the IVC to the PFO while the patient was in the upright position,

facilitating shunting of IVC blood across the PFO in the absence of elevated right atrial pressures. Traction on the atrial septum by the dilated aorta in the upright position also may have further opened the PFO. Follow-up echocardiogram studies show that a right to left shunt is still present at the atrial level but to lesser extent and no longer of clinical significance. This case highlights the successful use of a percutaneous procedure for dealing with a symptomatic PFO.

REFERENCES

1. Burchell HB, Helmoltz HF Jr, Wood EH. Reflex orthostatic dyspnea associated with pulmonary hypertension. *Am J Physiol* 1949;159:563-4.
2. Robin ED, Laman D, Horn BR, Theodore J. Platypnea related to orthodeoxia caused by true vascular lung shunts. *N Engl J Med* 1976;294:941-3.
3. Lock JE, Rome JJ, Davis R, et al. Transcatheter closure of atrial septal defects: Experimental studies. *Circulation* 1989;79:1091-9.
4. Thomas JD, Tabakin BS, Ittleman FP. Atrial septal defect with right to left shunt despite normal pulmonary artery pressure. *J Am Coll Cardiol* 1987;9:221-4.
5. Adolph EA, Lacy WO, Hermoni YI, Wexler LF, Javaheri S. Reversible orthodeoxia and platypnea due to right-to-left intracardiac shunting related to pericardial effusion. *Ann Intern Med* 1992;116:138-9.
6. Laybourn KA, Martin ET, Cooper RAS, Holman WL. Platypnea and orthodeoxia: shunting associated with an aortic aneurysm. *J Thorac Cardiovasc Surg* 1997;113:955-6.
7. Popp G, Melek H, Garnett AR Jr. Platypnea-orthodeoxia related to aortic elongation. *Chest* 1997;112:1682-4.
8. Ciafone RA, Aroesty JM, Weintraub RM, LaRaia PJ, Paulin S. Cyanosis in uncomplicated atrial septal defect with normal right cardiac and pulmonary arterial pressures. *Chest* 1978;74:596-9.
9. Seward JB, Hayes DL, Smith HC, et al. Platypnea-orthodeoxia: clinical profile, diagnostic workup, management, and report of seven cases. *Mayo Clin Proc* 1984;59:221-31.
10. Begin R. Platypnea after pneumonectomy. *N Engl J Med* 1975;293:342-3.



Hindawi
Submit your manuscripts at
<http://www.hindawi.com>

