

A case of congenital cutis laxa (generalized elastolysis)

Paul Champion MB PhD FRCPC, Frank Ryan MB FRCPI FRCPC

P Champion, F Ryan. A case of congenital cutis laxa (generalized elastolysis). *Can Respir J* 2005;12(3):151-152.

Cutis laxa (generalized elastolysis) is characterized by sagging folds of loose skin on the face and trunk. Although grouped with hyperelastic skin conditions such as Ehlers-Danlos syndrome, cutis laxa shows an almost total lack of skin elasticity. Because it is a generalized state, it may present as an abnormality in the connective tissue of more than one organ system. The authors report a patient who had end-stage renal failure related to heavy chain disease, a recognized association of cutis laxa. Although the patient's vascular abnormalities were significant, she died of respiratory failure at 41 years of age from cutis laxa-induced emphysema.

Key Words: *Cutis laxa; Emphysema; Heavy chain disease; Renal failure; Respiratory failure*

The patient was referred by the Renal Dialysis Program, Vancouver General Hospital, Vancouver, British Columbia, because of dyspnea. Cutis laxa was diagnosed by skin biopsy when she was in her late 20s. She underwent a number of cosmetic surgeries as well as correction of a urethral prolapse. She developed glomerulonephritis due to heavy chain disease in her 30s. When initially evaluated for dyspnea at 37 years of age, she was a lifelong nonsmoker, was employed as a community support worker and had trained as a respiratory therapist. There was no childhood or past history of respiratory illness. She developed exertional dyspnea that showed symptomatic improvement with bronchodilator therapy. Pulmonary function tests revealed some airflow obstruction and gas trapping with normal gas exchange initially, but over five years, her diffusing capacity decreased to 60% of predicted. She underwent a cadaveric renal transplantation, which failed after three years. Therapy at the time of evaluation included cyclosporine, low-dose prednisone, azathioprine, amlodipine, quinapril and furosamide.

PHYSICAL EXAMINATION

The patient was a thin Caucasian woman who weighed 55 kg and looked much older than her stated age. She had loose skin over the entire surface of her body. There was no finger clubbing or tachypnea. Her chest was hyper-resonant to percussion and her breath sounds were diminished in intensity with no

Cas de *cutis laxa* congénital (élastolyse généralisée)

La *cutis laxa* (élastolyse généralisée) est caractérisée par des replis de peau lâches au niveau du visage et du torse. Bien que faisant partie des maladies cutanées hyperélastiques, comme le syndrome d'Ehlers-Danlos, la *cutis laxa* se présente avec une quasi-absence d'élasticité cutanée. Étant donné qu'il s'agit d'un état généralisé, il peut s'observer sous la forme d'une anomalie des tissus conjonctifs affectant plus d'un système organique. Les auteurs signalent le cas d'une patiente souffrant d'insuffisance rénale terminale associée à une maladie des chaînes lourdes dont on connaît le lien avec la *cutis laxa*. Malgré d'importantes anomalies vasculaires, c'est une insuffisance respiratoire et un emphysème imputable à la *cutis laxa* qui a emporté la patiente à l'âge de 41 ans.

wheeze. Her blood pressure was normal. There was a short aortic diastolic murmur but no evidence of heart failure. Her abdomen was scaphoid and there was no palpable aneurysmal change in the aorta.

INVESTIGATIONS

The patient's forced vital capacity was 3.5 L (90% of predicted) and her forced expiratory volume in 1 s was 1.6 L (50% of predicted), which increased by 300 mL (20%) following the administration of a bronchodilator. The patient's residual volume was 223% of predicted and her diffusing capacity was 55% of predicted. Analysis of the patient's arterial blood gases demonstrated a pH of 7.38, PCO₂ of 30 mmHg, PO₂ of 87 mmHg and bicarbonate level of 17 mmol/L. In addition, her alpha-1-antitrypsin level was normal. Previous blood work had shown a gammopathy compatible with heavy chain disease.

The chest radiograph (Figure 1) demonstrated bullous emphysema with a predominantly lower zone distribution and aortic tortuosity. The chest computed tomography scan showed emphysematous changes (Figure 2).

Cardiac catheterization that had been performed previously showed a probe-patent atrial septal defect or foramen ovale, ectasia of the proximal coronary artery distribution and tortuosity of the aorta.

The patient's skin biopsy showed an absence of elastin fibres, typical of the dermatological changes of cutis laxa.

Respiratory and Internal Medicine; Vancouver Hospital and Health Sciences Centre; and the University of British Columbia, Vancouver, British Columbia

Correspondence: Dr Paul Champion, UBC Respiratory Clinic, 2775 Heather Street, Vancouver, British Columbia V5Z 3J5.
E-mail pchamp@interchange.ubc.ca

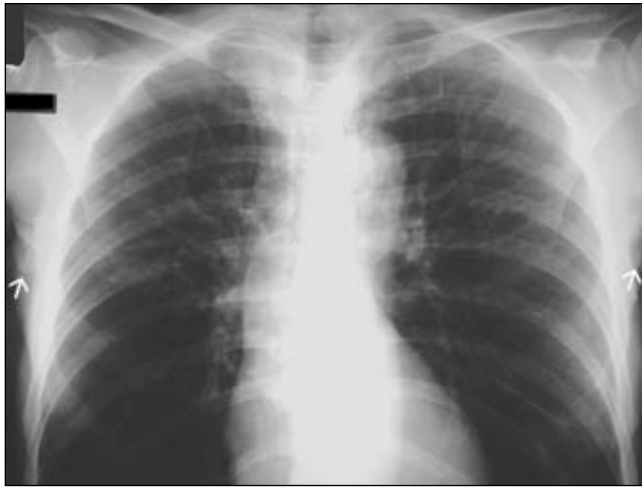

Figure 1) Plain chest radiograph showing emphysematous changes predominantly in the lower lung zones and the tortuosity of the aorta. Note the sagging, redundant folds of skin in the patient's axillae (arrows)

CLINICAL COURSE

The patient's condition deteriorated gradually over a four-year period of follow-up. Because of multisystemic disease, she was considered to be unsuitable for lung transplantation. She received ambulatory and overnight supplemental O₂. During a subsequent admission for the management of an acute infective exacerbation, nasal bilevel positive airway pressure was used for a short period. She died from respiratory failure at 41 years of age. An autopsy was not performed.

COMMENT

The present case of cutis laxa had some of the features considered to be typical of the condition (1,2) including dermatological changes with a history of cosmetic surgery, aortic ectasia, renal disease related to gammopathy, urethral prolapse and progressive emphysematous changes of the lungs. Without these associated features, the pulmonary manifestations might otherwise have suggested alpha-1-antitrypsin deficiency in this young, nonsmoking woman. Emphysema is an almost invariable complication of cutis laxa. Other pulmonary complica-

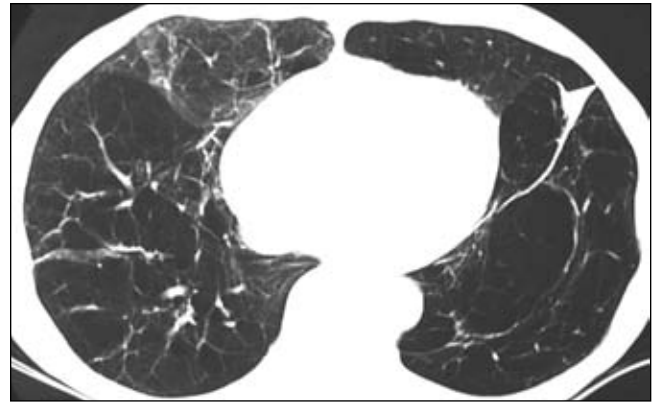


Figure 2) Computed tomography scan of the lower lung fields showing extensive emphysematous changes

tions that have been described include peripheral pulmonary artery stenosis and diaphragmatic eventration (3,4). Diverticula of the gastrointestinal and genitourinary tract have also been reported (3,4).

Cutis laxa may be either an autosomal dominant or recessive condition. An X-linked form is usually referred to as Ehlers-Danlos syndrome. An acquired form of cutis laxa has been described in association with heavy chain disease (5). The skin biopsy typically shows a lack of elastin or the fragmentation of elastin fibres with normal dermatological collagen.

REFERENCES

1. Dingman RO, Grabb WC, Oneal RM. Cutis laxa congenita – generalized elastolysis. *Plast Reconstr Surg* 1969;44:431-5.
2. Polsen C, Netscher DT, Green L, Polsen J. Generalized elastolysis (cutis laxa): Case study illustrating associated medical and surgical conditions. *South Med J* 1995;88:753-8.
3. Meine F, Grossman H, Forman W, Jackson D. The radiographic findings in congenital cutis laxa. *Radiology* 1974;113:687-90.
4. Lally JF, Gohel VK, Dalinka MK, Coren GS. The roentgenographic manifestations of cutis laxa (generalized elastolysis). *Radiology* 1974;113:605-6.
5. Tan S, Pon K, Bargman J, Ghazarian D. Generalized cutis laxa associated with heavy chain deposition disease. *J Cutan Med Surg* 2003;7:390-4.



Hindawi
Submit your manuscripts at
<http://www.hindawi.com>

