

Burkholderia pseudomallei infection in a cystic fibrosis patient from the Caribbean: A case report

Dimas Mateos Corral MD¹, Allan L Coates MDCM¹, Yvonne CW Yau MD², Raymond Tellier MD², Mindy Glass MD³, Steven M Jones PhD⁴, Valerie J Waters MD MSc⁵

D Mateos Corral, AL Coates, YCW Yau, et al. *Burkholderia pseudomallei* infection in a cystic fibrosis patient from the Caribbean: A case report. *Can Respir J* 2008;15(5):237-239.

Burkholderia pseudomallei is a pathogen identified with increasing frequency in the respiratory tracts of cystic fibrosis (CF) patients from endemic areas such as Southeast Asia and northern Australia. The following report describes the first known reported case in a CF patient from the Caribbean attending a North American CF clinic.

Key Words: *Acute pulmonary exacerbation; Burkholderia pseudomallei; Cystic fibrosis; Melioidosis*

CASE PRESENTATION

The patient was a 17-year-old Caucasian male with cystic fibrosis (CF) from the British Virgin Islands. From three to six months of age, he developed mild wheezing, intermittent cough and failure to thrive, as well as severe gastrointestinal symptoms. He was diagnosed with pancreatic-insufficient CF at the age of six months, based on two positive sweat chloride tests. He had no family history of CF at the time of diagnosis. He was followed intermittently in the CF clinics at the Royal Brompton Hospital in London, England, and at The Hospital for Sick Children in Toronto, Ontario. Since the age of two years, his sputum cultures had consistently grown *Staphylococcus aureus* and intermittently grown *Haemophilus influenzae*. He developed sporadic acute pulmonary exacerbations and was treated with oral antibiotics and chest physiotherapy. He was also treated with pancreatic enzymes and multivitamins. However, he was often noncompliant with these medications and chest physical therapy, and he had never been on inhaled antibiotics.

He was noted to have an increased cough and sputum production on June 30, 2006. He was assessed initially at the Royal Brompton Hospital and was diagnosed with right middle lobe pneumonia. His sputum culture grew *S aureus* and he was treated with a two-week course of oral ciprofloxacin followed by another three weeks of oral azithromycin. Despite antibiotic therapy, he continued to be symptomatic.

On August 11, 2006, he presented to the CF clinic at The Hospital for Sick Children with a persistent cough. His forced expiratory volume in 1 s was 71% predicted, which was

Une infection à *Burkholderia pseudomallei* chez un patient atteint de fibrose kystique d'origine antillaise : Rapport de cas

Le *Burkholderia pseudomallei* est un pathogène qu'on décèle de plus en plus souvent dans les voies respiratoires des patients atteints de fibrose kystique (FK) de régions endémiques comme l'Asie du Sud-Est et l'Australie septentrionale. Le rapport suivant décrit le premier cas déclaré connu d'un patient atteint de FK des Antilles qui fréquentait une clinique de FK nord-américaine.

decreased from 94% measured 15 months earlier. His chest radiograph showed severe bronchiectasis and mucous plugging, which was significantly worse than his previous radiographic studies. Sputum cultures at the time of his visit revealed a heavy growth of *S aureus*, a Gram-negative bacillus (Figure 1A) that required further identification, and a scant amount of *Pseudomonas aeruginosa*. The *S aureus* isolate was susceptible to cloxacillin but resistant to clindamycin and erythromycin. The *P aeruginosa* isolate was susceptible to piperacillin, ceftazidime and all the aminoglycosides. He was unable to stay in hospital for treatment at that time. He was started on inhaled tobramycin for an acute pulmonary exacerbation due to *P aeruginosa* and was discharged to return to the British Virgin Islands.

The unidentified Gram-negative bacillus was isolated from *Burkholderia cepacia*-selective agar after overnight incubation. The organism was identified as *B cepacia* by the BD Phoenix automated system (Becton, Dickinson and Company, USA), but as low discrimination for *Burkholderia pseudomallei* (47.9%), *B cepacia* (45.3%) and *P aeruginosa* (4.8%) by the API NE system (bioMérieux, France). The isolate was submitted for amplification and sequencing of the 16S ribosomal RNA gene, because of the discrepancies in its identification. After amplification by polymerase chain reaction, approximately one-half of the gene was sequenced and aligned with the corresponding sequences of related species. Figure 1B shows that the sequence of the isolate unequivocally clusters with *B pseudomallei* and *Burkholderia mallei*. In addition, at position 75, the isolate had the nucleotide consistently associated

¹Division of Respiratory Medicine, Department of Paediatrics; ²Division of Microbiology, Department of Paediatric Laboratory Medicine, The Hospital for Sick Children, Toronto, Ontario; ³Bacterial Zoonoses Branch, Division of Foodborne, Bacterial and Mycotic Diseases, Centers for Disease Control and Prevention, Atlanta, Georgia, USA; ⁴Immunopathology, Special Pathogens Program, National Microbiology Laboratory, Winnipeg, Manitoba; ⁵Division of Infectious Diseases, Department of Paediatrics, The Hospital for Sick Children, Toronto, Ontario
Correspondence: Dr Dimas Mateos Corral, Division of Respiratory Medicine, Room 4534, 4th Floor, Roy C Hill Wing, The Hospital for Sick Children, 555 University Avenue, Toronto, Ontario M5G 1X8. Telephone 416-813-6346, fax 416-813-6246, e-mail dimasmateos@yahoo.com

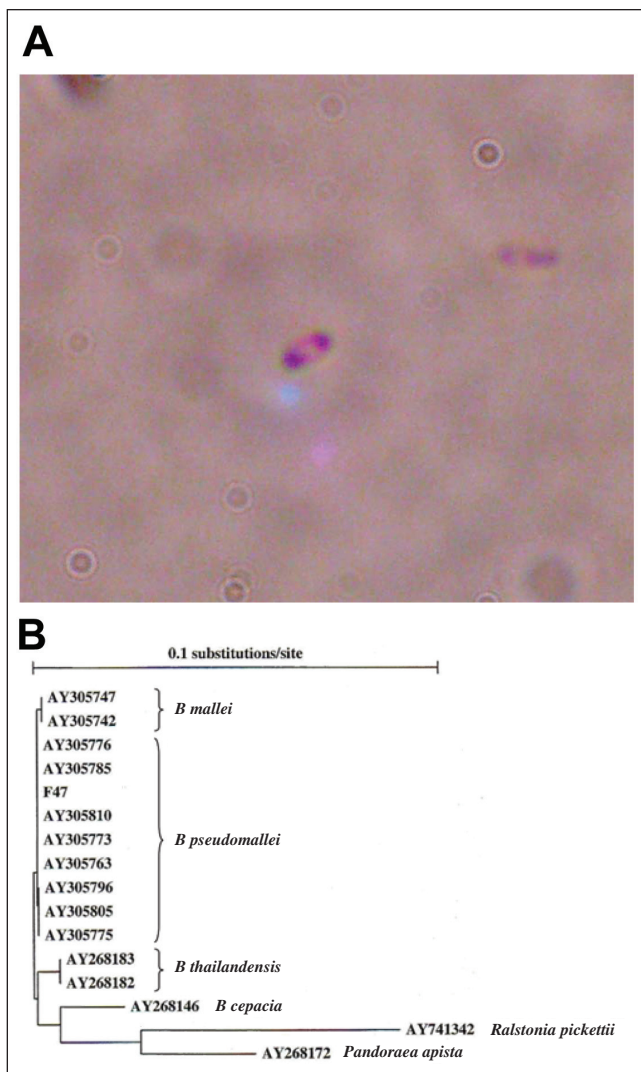


Figure 1 A Gram stain of *Burkholderia pseudomallei* showing typical bipolar 'safety pin' pattern (original magnification 100×). B Phylogenetic tree calculated from an alignment of the 16S ribosomal RNA gene sequence of the isolate (F47) with sequences from several representative strains of *B. pseudomallei* and *Burkholderia mallei*, as well as sequences from closely related species. Strains are identified by the GenBank accession numbers. The alignment was calculated with ClustalX for Windows version 1.81, and the phylogenetic tree was drawn with Treecon for Windows version 1.3b

with *B. pseudomallei* (1). The identification was further confirmed by the amplification of four target genes in *B. pseudomallei* by real-time polymerase chain reaction performed at the National Microbiology Laboratory (Winnipeg, Manitoba). The patient's *B. pseudomallei* isolate was susceptible to ceftazidime, imipenem and trimethoprim-sulfamethoxazole (TMP-SMZ).

Six laboratory workers performed what the Centers for Disease Control and Prevention deemed as high-risk manipulations on the patient's specimen (2). This included any procedures where the isolates were manipulated outside of a biosafety cabinet or if there was a potential of aerosol or droplet formation during the manipulation (2). All six received chemoprophylaxis; four with TMP-SMZ and two with doxycycline for three weeks. Of the four who were given TMP-SMZ, two people developed serum sickness-like symptoms

requiring a change in therapy to doxycycline. None developed symptoms of melioidosis. Serology testing on acute and convalescent paired sera, using the Melioidosis immunoglobulin M and immunoglobulin G Cassette Test kits (PanBio, Australia) (3), did not detect any seroconversion.

Once *B. pseudomallei* was identified, the family was informed and the patient was treated at the Royal Brompton Hospital.

DISCUSSION

B. pseudomallei is the etiological agent of melioidosis (4). Melioidosis is endemic to Southeast Asia and northern Australia, although sporadic case reports have been described in the Caribbean, Africa and the Middle East. *B. pseudomallei* is typically found in moist soil and pooled surface water, and infection is believed to occur through inhalation or percutaneous inoculation. The most common clinical presentation of melioidosis is pneumonia but it can also present as septicemia, skin ulcers and abscesses of the spleen, liver or kidneys. Diabetes, alcoholism, renal disease and chronic lung disease have been reported as the most common risk factors for melioidosis.

Although CF has not been specifically identified in studies as a risk factor for melioidosis, five reports of *B. pseudomallei* infection in CF patients have been published (5-9). They have described a total of 11 CF patients with *B. pseudomallei*, eight of whom developed respiratory symptoms following isolation of the organism from their respiratory tracts. All of the patients had been living in or travelling to Southeast Asia or northern Australia. This is the first reported case, to our knowledge, of *B. pseudomallei* in a CF patient from the Caribbean identified in a North American CF clinic. Our patients' respiratory deterioration may have been due to his chronic noncompliance with CF therapies or infection with *P. aeruginosa* or *S. aureus*. However, the heavy growth of *B. pseudomallei* could not be ignored given previous reports of its role as a pathogen in the respiratory tract of CF patients, and antibiotic therapy was recommended.

Diagnosing *B. pseudomallei* infection can be challenging. Isolation of *B. pseudomallei* from patient samples remains the 'gold standard' in diagnosis and requires the use of selective media for nonsterile specimens (4). *B. pseudomallei* can be mistaken as *B. cepacia* in routine cultures of sputum samples obtained from patients with CF (6). Although *B. pseudomallei* colonies have a slightly drier and wrinkled appearance and an earthy odour, these phenotypic differences are not easily appreciated in laboratories in nonendemic areas. The reliability of the API NE system in the identification of *B. pseudomallei* remains controversial (4), and there are no published data on the performance of the BD Phoenix automated system. The use of conventional biochemical tests may take up to one week for species confirmation. These limitations highlight the importance of molecular testing to confirm *B. pseudomallei*. 16S ribosomal RNA gene sequencing has long been used for the identification of bacterial species and is a reliable method for identifying *B. pseudomallei* (1). It is not, however, available in all microbiology laboratories. A high index of suspicion is thus needed when identifying organisms from the sputum of CF patients from an endemic area or with a suggestive travel history.

Because laboratories in nonendemic countries are frequently not familiar with the diagnosis of melioidosis, in addition to misidentification, there is the potential for laboratory exposure.

Although infection is not easily acquired from routine, open-bench laboratory work (10), there have been numerous reports of laboratory-acquired infection with *B. pseudomallei* (11,12). Because the infection is commonly acquired by inhalation, any procedure that could lead to aerosol formation should be conducted in a biosafety cabinet. 'Sniff testing' of culture plates should not be performed if *B. pseudomallei* is suspected. If cultures of the organism are inadvertently manipulated outside of biosafety level 2 conditions, postexposure prophylaxis may be considered (2). Recommendations for postexposure prophylaxis with TMP-SMZ or doxycycline for three weeks are based on in vitro and animal data because no published data for humans are available.

Treatment of melioidosis generally consists of an initial intensive phase for a minimum of 14 days with ceftazidime or a carbapenem (plus or minus TMP-SMZ) followed by an eradication phase for a minimum of three months with TMP-SMZ

(plus or minus doxycycline) (4). Similar regimens have been used successfully in CF patients; however, eradication often proves to be more difficult once colonization is established in a bronchiectatic lung (6).

CONCLUSION

The present report further documents the endemicity of *B. pseudomallei* in subtropical areas outside of Southeast Asia, including the Caribbean, and provides support for the view that CF patients may become infected with this bacterium. Hence, it is important to obtain a detailed travel history in CF patients to safely and correctly identify *B. pseudomallei* in cultures of the respiratory tract.

ACKNOWLEDGEMENTS: The authors thank Louise Taylor (The Hospital for Sick Children, Toronto, Ontario) for her continued care of the patient.

REFERENCES

1. Gee JE, Sacchi CT, Glass MB, et al. Use of 16S rRNA gene sequencing for rapid identification and differentiation of *Burkholderia pseudomallei* and *B. mallei*. *J Clin Microbiol* 2003;41:4647-54.
2. Centers for Disease Control and Prevention. Laboratory exposure to *Burkholderia pseudomallei* – Los Angeles, California, 2003. *MMWR Morb Mortal Wkly Rep* 2004;53:988-90.
3. Wuthiekanun V, Amornchai P, Chierakul W, et al. Evaluation of immunoglobulin M (IgM) and IgG rapid cassette test kits for diagnosis of melioidosis in an area of endemicity. *J Clin Microbiol* 2004;42:3435-7.
4. Cheng AC, Currie BJ. Melioidosis: Epidemiology, pathophysiology, and management. *Clin Microbiol Rev* 2005;18:383-416.
5. Holland DJ, Wesley A, Drinkovic D, Currie BJ. Cystic fibrosis and *Burkholderia pseudomallei* infection: An emerging problem? *Clin Infect Dis* 2002;35:e138-40.
6. O'Carroll MR, Kidd TJ, Coulter C, et al. *Burkholderia pseudomallei*: another emerging pathogen in cystic fibrosis. *Thorax* 2003;58:1087-91.
7. Schülin T, Steinmetz I. Chronic melioidosis in a patient with cystic fibrosis. *J Clin Microbiol* 2001;39:1676-7.
8. Visca P, Cazzola G, Petrucca A, Braggion C. Travel-associated *Burkholderia pseudomallei* infection (Melioidosis) in a patient with cystic fibrosis: A case report. *Clin Infect Dis* 2001;32:E15-6.
9. Dance DA, Smith MD, Aucken HM, Pitt TL. Imported melioidosis in England and Wales. *Lancet* 1999;353:208.
10. Ashdown LR. Melioidosis and safety in the clinical laboratory. *J Hosp Infect* 1992;21:301-6.
11. Green RN, Tuffnell PG. Laboratory acquired melioidosis. *Am J Med* 1968;44:599-605.
12. Schlech WF III, Turchik JB, Westlake RE, Jr, Klein GC, Band JD, Weaver RE. Laboratory-acquired infection with *Pseudomonas pseudomallei* (melioidosis). *N Engl J Med* 1981;305:1133-5.

