

## Case Report

# Myocardial Infarction due to Endocarditis

**Jaya D. Bathina and Syed Wamique Yusuf**

*Department of Cardiology, University of Texas MD Anderson Cancer Center, Unit 1451, 1515 Holcombe Boulevard, Houston, TX 77030, USA*

Correspondence should be addressed to Syed Wamique Yusuf, syusuf@mdanderson.org

Received 30 September 2010; Accepted 10 January 2011

Academic Editor: Jean-Bernard Durand

Copyright © 2011 J. D. Bathina and S. W. Yusuf. This is an open access article distributed under the Creative Commons Attribution License, which permits unrestricted use, distribution, and reproduction in any medium, provided the original work is properly cited.

We present a case of a 43-year-old man who sustained a myocardial infarction due to infective endocarditis.

## 1. Introduction

Myocardial infarction (MI) is usually due to underlying atherosclerosis, but can also occur uncommonly due to embolic phenomenon associated with endocarditis.

## 2. Case Report

A 43-year-old male with a history of acute myeloid leukemia and multiple episodes of bacteremia presented to the hospital with syncope. A computerized tomographic (CT) scan of the head showed multiple cerebral infarcts. One week later he developed chest pain. On examination his blood pressure was 118/65 mm Hg with no signs of heart failure. A 12-lead electrocardiogram showed ST elevation in inferior leads, V5 and V6 (Figure 1). Laboratory tests showed an elevated Troponin I with a peak value of 6.9 ng/mL (normal value <0.4 ng/mL) and normal blood cultures. A diagnosis of ST elevation myocardial infarction (MI) was made, and the patient was treated with aspirin, beta-blockers, and nitrates. The diagnosis of MI due to endocarditis in our case was made on clinical grounds, and coronary angiogram was not done. Heparin was not given due to a history of severe thrombocytopenia. A transesophageal echocardiogram showed vegetations on mitral and aortic

valves, mitral regurgitation, with normal left ventricular systolic function (Figure 2). CT scan showed multiple infarcts in lungs, spleen, and kidneys. He died one week later due to new cerebral infarcts. Postmortem examination was not carried out.

## 3. Discussion

Systemic and pulmonary embolization is the most common presentation of nonbacterial thrombotic endocarditis (NBTE) [1]. Stroke is the commonest embolic event, frequently affecting the middle cerebral artery territory [2]. MI is not uncommon in NBTE patients with an incidence of 7.5% [3]. The management of MI in patients with endocarditis is similar to general population, but the use of thrombolytics can lead to bleeding complications [4]. Although heparin is traditionally used in cases of NBTE to prevent recurrent thromboemboli, there are no large scale trials of anticoagulants in patients with MI associated with NBTE. There are only few case reports of MI due to endocarditis, and both inferior and anterior wall MI has been documented in these cases [5, 6]. In cases where angiogram has been done, no specific pattern of coronary involvement has been documented [6].

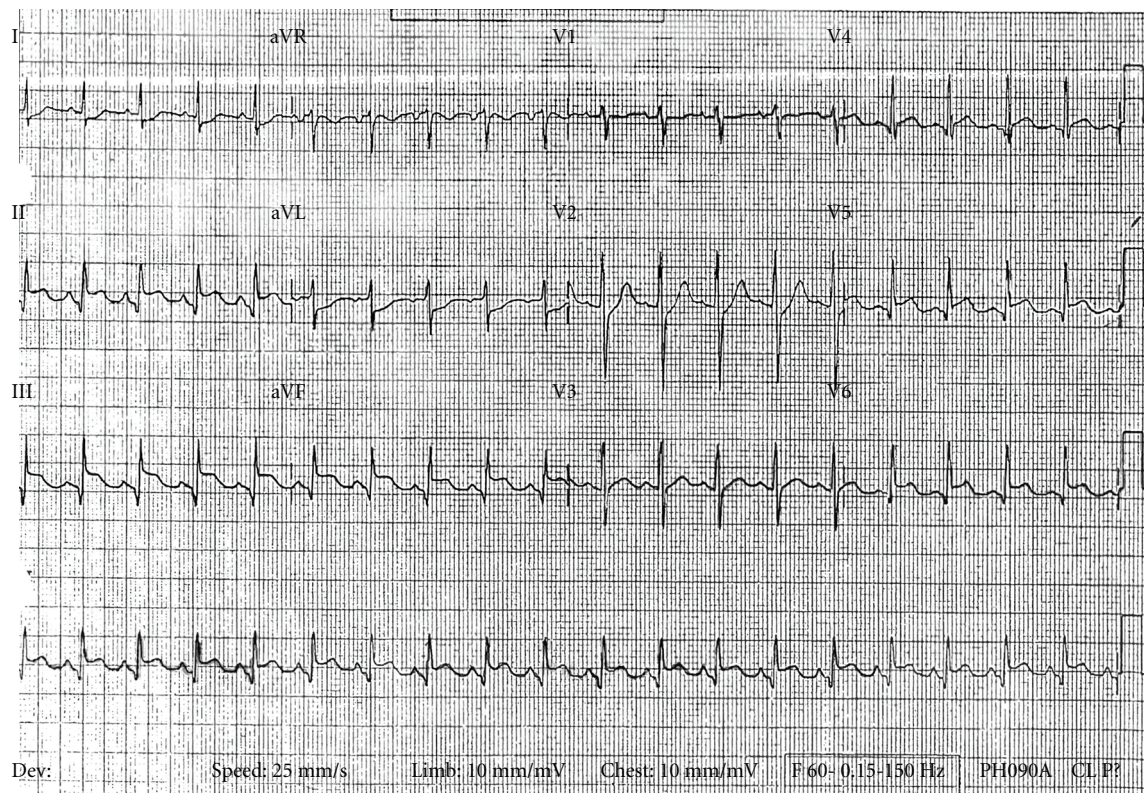


FIGURE 1: A 12-lead electro cardiogram showing ST elevations in lead II, III, aVF, V5, and V6.

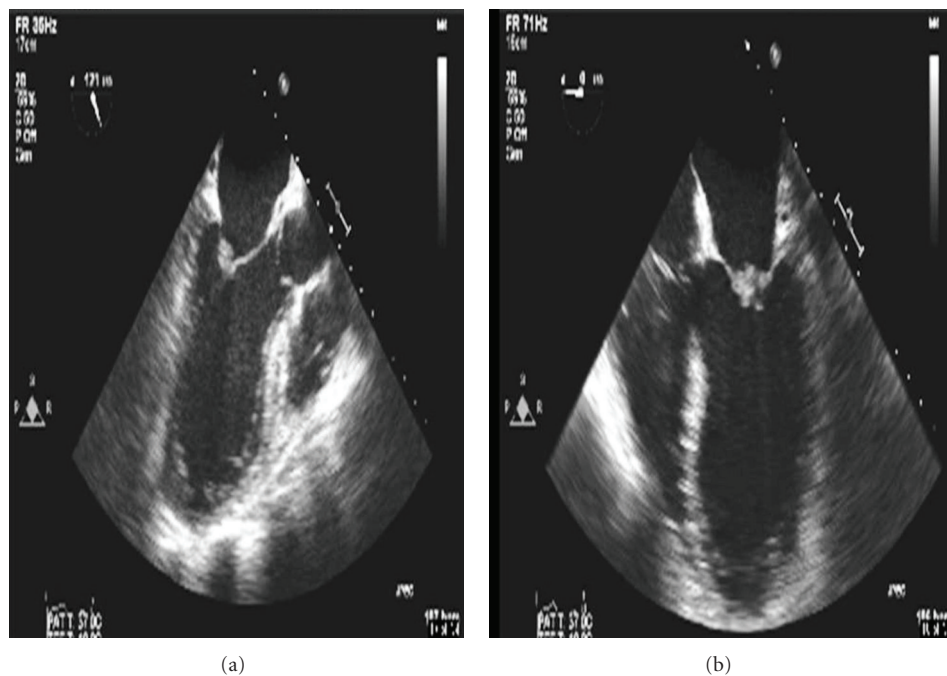


FIGURE 2: A transesophageal echocardiogram showing vegetation on the mitral valve.

## References

- [1] I. Steiner, "Nonbacterial thrombotic endocarditis—a study of 171 case reports," *Ceskoslovenska Patologie*, vol. 29, no. 2, pp. 58–60, 1993.
- [2] A. B. Singhal, M. A. Topcuoglu, and F. S. Buonanno, "Acute ischemic stroke patterns in infective and nonbacterial thrombotic endocarditis: a diffusion-weighted magnetic resonance imaging study," *Stroke*, vol. 33, no. 5, pp. 1267–1273, 2002.
- [3] F. Chino, A. Kodama, M. Otake, and D. S. Dock, "Nonbacterial thrombotic endocarditis in a Japanese autopsy sample. A review of eighty cases," *American Heart Journal*, vol. 90, no. 2, pp. 190–198, 1975.
- [4] J. Ortega-Carnicer, F. Ruiz-Lorenzo, and A. Benedicto, "Thrombolytic therapy for acute myocardial infarction in unsuspected infective endocarditis," *International Journal of Cardiology*, vol. 103, no. 1, pp. 108–110, 2005.
- [5] J. D. Bathina, I. N. Daher, J. B. Durand, and S. W. Yusuf, "Acute myocardial infarction associated with non-bacterial thrombotic endocarditis," *Texas Heart Institute Journal*, vol. 37, pp. 208–212, 2010.
- [6] C. J. Roxas and A. J. Weekes, "Acute myocardial infarction caused by coronary embolism from infective endocarditis," *Journal of Emergency Medicine*. In press.



