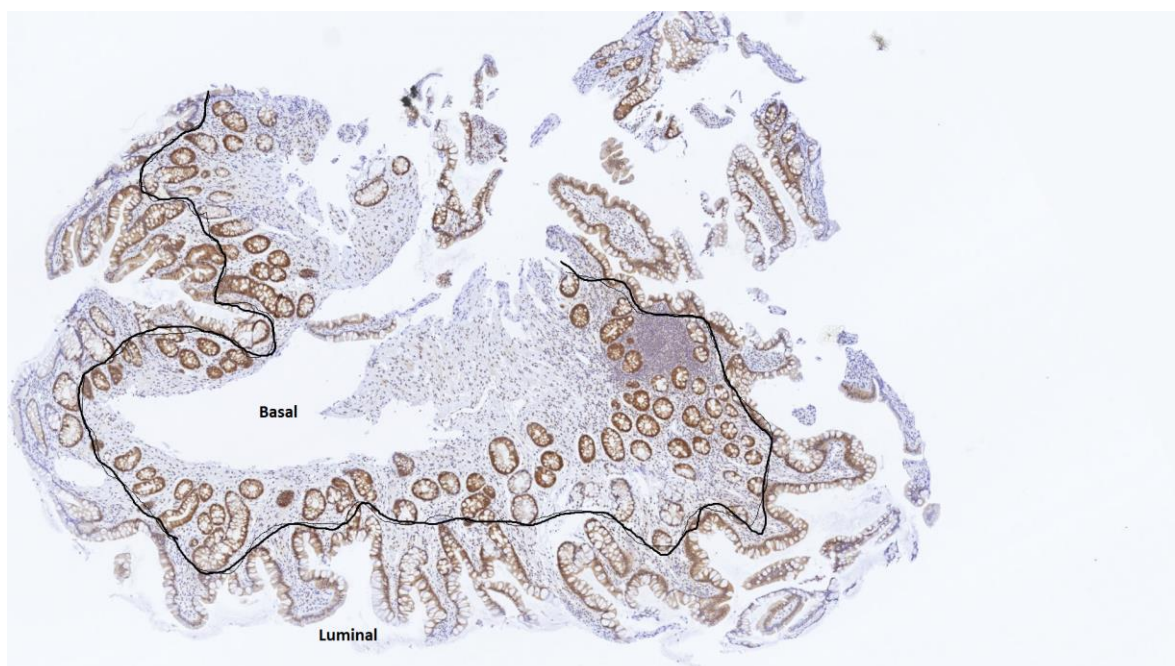


Supplementary Figure 1

Supplementary Figure 1. Immunohistochemical staining of SMAD4 on an ileal biopsy from a rCD patient. Luminal and basal part of the biopsy is separated by a black drawing.