

Research Article

Risk Factors for Contralateral Occult Papillary Thyroid Carcinoma in Patients with Clinical Unilateral Papillary Thyroid Carcinoma: A Case-Control Study

Liu Yihao ¹, Li Shuo,¹ Xi Pu,¹ Wang Zipeng,¹ Sun Hanlin,¹ Chang Qungang,¹ Wang Yongfei,¹ and Yin Detao ^{1,2,3}

¹Thyroid Surgery Department, The First Affiliated Hospital of Zhengzhou University, Zhengzhou, China

²Engineering Research Center of Multidisciplinary Diagnosis and Treatment of Thyroid Cancer of Henan Province, Zhengzhou, China

³Key Medicine Laboratory of Thyroid Cancer of Henan Province, Zhengzhou, China

Correspondence should be addressed to Yin Detao; detaoyin@zzu.edu.cn

Received 6 January 2022; Accepted 6 June 2022; Published 28 June 2022

Academic Editor: Aman Rajpal

Copyright © 2022 Liu Yihao et al. This is an open access article distributed under the Creative Commons Attribution License, which permits unrestricted use, distribution, and reproduction in any medium, provided the original work is properly cited.

Introduction. Papillary thyroid cancer (PTC) is one of the most prevalent endocrine malignancies that has increased in recent decades around the world. Although the indicator for navigating the surgical extent in PTC patients is still in debate, a key issue is how to predict that there are undetected preoperative tumors in the contralateral thyroid lobe. This study aims to find risk factors for contralateral occult papillary thyroid cancer (COPTC) to facilitate more accurate surgical decisions made for patients with PTC. **Materials and Methods.** In our study, we included 229 patients who underwent total thyroidectomy plus central and ipsilateral lateral lymph nodes dissection from January 1, 2019, to September 1, 2021. Univariate and multivariate logistic regression analyses were conducted to assess the association between COPTC and clinical-pathological characteristics, as well as the relation between the diameter of the occult lesions and predictors. The forest plot was plotted to visualize the prediction factors from the output of the multivariate regression analysis. A ROC curve was used to evaluate the combining potency of all the risk factors. **Results.** Of the 229 patients included in our study, 46 with COPTC were assigned to the case group, representing 20.1% in this study. Multifocality in one lobe (OR = 2.21, $P = 0.03$), intact capsule (OR = 2.54, $P = 0.01$), central lymph node metastasis (OR = 3.00, $P = 0.02$), and Hashimoto's thyroiditis (OR = 2.08, $P = 0.04$) are more prone to present contralateral occult papillary thyroid carcinoma. The ROC curve of the aggregate potency of the risk factors presents AUC = 0.701 ($P < 0.001$), and the best cutoff value was 2.02, with a sensitivity of 78.3% and specificity of 55.2%. Furthermore, there was no statistical correlation between the diameter of the occult tumor and the four obtained variables. **Conclusion.** Patients with multifocality in one lobe, intact capsule, central lymph node metastasis, and HT may harbor contralateral papillary thyroid carcinoma. It is essential to be prudent to make a surgical or follow-up decision on these patients. In addition, more clinical rather than postoperative pathological indicators need to be revealed in the future.

1. Introduction

Thyroid cancer, as one of the most common malignant endocrine neoplasms, has increased in all parts of the world in recent decades [1], which mainly results from the prevalence of differentiated thyroid carcinoma (DTC), which accounts for above 90% of all types of thyroid carcinoma, and papillary thyroid carcinoma (PTC) is the most common

pathological subtype of DTC [2,3]. Therefore, many emerging studies on the diagnosis, treatments, prognosis, biomarkers, and genomics of PTC have been helpful in the diagnosis and treatment. Fine-needle aspiration biopsy (FNAB) navigated by Doppler ultrasound combined with genetic tests of BRAFv600e and RAS can help discriminate poorly defined nodules by imaging examinations [4,5]; serum thyroglobulin (sTg) can also contribute to the diagnosis

and monitoring of recurrence [6,7], and serum thyroid-stimulating hormone (TSH) can also be a valuable tool for the management and follow-up of patients who underwent surgery [8]. Generally, in fact, the prognosis of PTC is excellent based on precise diagnosis, normative operations, TSH suppression therapy, and postoperative iodine radiotherapy over the years, and the mortality and occurrence remain stable [1], while also partly due to which may be its inertness.

Preoperative Doppler ultrasound plays an essential role in the detection of thyroid nodules for an economical and convenient reason instead of computed tomography (CT), magnetic resonance imaging (MRI), or 18F-FDG-PET scans [9]. By describing the size, location, calcification type, margin, blood supply, and lymph node morphology of the neck region from skilled sonographers, surgeons can preliminarily judge the necessity and method of surgery. However, for those micronodules, usually 5 mm or less, even high-resolution ultrasounds are challenging to detect [10]. Limitations of preoperative ultrasound can omit some occult lesions, regardless of malignant or benign nodules.

Surgery is undoubtedly the irreplaceable way to treat most papillary thyroid cancers and aims to eliminate primary tumors, reduce the risk of cancer recurrence, and allow postoperative iodine therapy, if necessary. However, the choice of lobectomy and total thyroidectomy remains a dilemma. According to the 2015 ATA guidelines, for tumors lesser than 4 cm, confined to one lobe, absent of extra-thyroidal extension (ETE), and clinical lymph nodes metastasis (LNM), the extent of surgery was recommended as either lobectomy or total thyroidectomy (TT) [11], depending on the intentionality from patients and surgery team. However, some scholars argued that total thyroidectomy has the advantage of allowing individualized postoperative risk stratification and surveillance [12], and some other previous studies have reported that in patients with unilateral thyroid cancer who underwent total thyroidectomy, contralateral malignant tumors, defined as occult thyroid carcinoma, also represented a nonnegligible proportion [13–17]. Furthermore, evidence indicates that multifocality, including occult contralateral or bilateral thyroid cancer, is an independent risk predictor of recurrence after lobectomy [18]. Indetermination of contralateral occult thyroid cancer risk factors results in unnecessary bilateral thyroid dissection or insufficient surgery. Some researchers have tried to seek contralateral thyroid cancer risk factors, while the evidence obtained is still limited. As a result, we conducted this study to explore the predictors of contralateral occult papillary thyroid carcinoma (COPTC) in clinical unilateral thyroid cancer patients based on the ultrasound and pathological characteristics of the primary detected lesions in a circumstance of time-consuming debating between total and unilateral thyroidectomy.

2. Materials and Methods

2.1. Definitions. We define unilateral papillary thyroid cancer as malignant nodules located in only one thyroid lobe. Then, contralateral occult papillary thyroid cancers

(COPTC) were defined as malignant tumors undetected by preoperative imaging, mainly Doppler ultrasound, located in the contralateral lobe of the primary unilateral carcinoma detected by at least two pathologists postoperatively. The location (upper or other) and diameter of the primary largest tumor foci were based on preoperative Doppler ultrasound examination description, which was reported by at least one experienced ultrasound physician. Furthermore, multifocality of ipsilateral carcinoma, the diameter of the contralateral occult lesions, capsular status, tracheal invasion, strap muscle invasion, central lymph node metastasis (CNM), and lateral lymph node metastasis (LNM) were based on postoperative paraffin section diagnosed by at least two experienced pathologists.

2.2. Samples. This retrospective case-control study consisted of patients in a high-volume thyroid surgery unit of The First Affiliated Hospital of Zhengzhou University, who underwent total thyroidectomy plus bilateral central and ipsilateral lateral lymph node dissection from January 1, 2019, to September 1, 2021. Patients with the following conditions were excluded: (1) contralateral undetermined nodules detected by preoperative image examination or pathology; (2) distant metastasis at diagnosis on pathological or clinical analysis; (3) history of other malignant tumors; (4) history of head and neck radiation exposure; (5) non-PTC confirmed by postoperative pathology (follicular, medullary, anaplastic, or benign); (6) recurrence for reoperation; and (7) lesions located in the isthmus lobe. Finally, we had 229 patients included in this study, in which 46 patients who were diagnosed with bilateral thyroid papillary cancer postoperatively were brought into the case group, which means they had COPTC, and 183 patients with unilateral PTC with or without contralateral benign nodules were assigned to the control group. This process is shown in Figure 1. Clinical pathological characteristics such as age, sex, body mass index (BMI), ipsilateral multifocality of the primary tumor, location and diameter of the primary largest tumor foci, diameter of the contralateral lesions, capsular status, trachea invasion, strap muscles invasion, central lymph nodes metastasis (CNM), ipsilateral lateral lymph nodes metastasis (LNM), BRAFv600e mutation, serum thyroglobulin (Tg), and presence of Hashimoto's thyroiditis (HT) were collected.

2.3. Statistical Analysis. All statistical analyses were performed by SPSS v26.0 software (Chicago, IL, USA). Continuous variables were expressed as means \pm standard deviations (SD), and classified variables were presented as frequency and percentages. Student's t-test and Pearson's chi-square test were conducted for the comparison between the case and control groups. Univariate logistic regression analyses were performed to initially identify risk factors for contralateral thyroid cancer. Then, all statistically significant variables in univariate analyses were included in multivariate logistic regression analyses to find the optimal COPTC indicators. The forest plot was plotted by using GraphPad Prism 9 to visualize the prediction factors from the output of

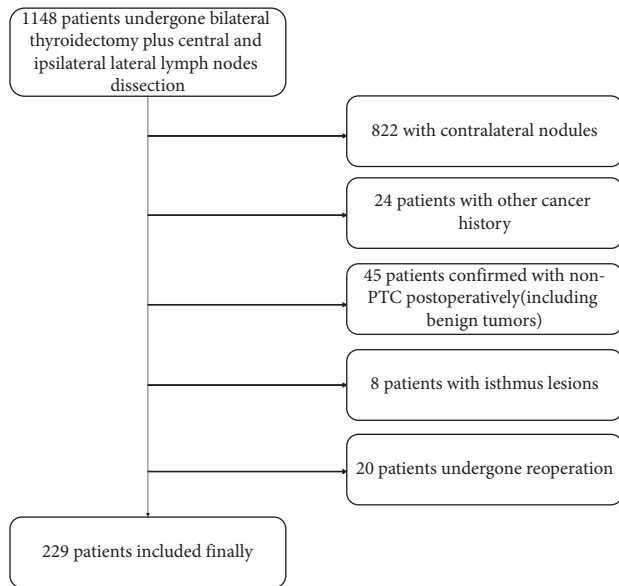


FIGURE 1: Flowchart illustrating the selection of the samples.

the multivariate regression analysis. A ROC curve was used to evaluate the combining potency of all the risk factors. Finally, we also evaluated the association between the diameter of the contralateral lesions and the four variables.

3. Results

Table 1 presents the distribution of clinical and pathological characteristics between the case and control groups. Of all patients included in our study, 159 were women and 70 were men, aged 15 to 71 years, and the incidence of COPTC in the patients was 20.1% (46 cases). No significant difference was found in age, gender, BMI, location, diameter, trachea invasion, strap muscle invasion, B-RAF mutation, and serum Tg. Yet there were significant differences with respect to ipsilateral multifocality (52.2% vs 33.3%, $P < 0.05$), intact capsule (43.5% vs 27.7%, $P < 0.05$), central lymph nodes metastasis (84.8% vs 68.9%, $P < 0.05$), and Hashimoto's thyroiditis (43.5% vs 27.3%, $P < 0.05$).

In univariate logistic regression analysis (Table 2), no significant association was found in diameter, LNM, and B-RAF mutation; hence, we excluded them from our multivariate logistic regression analysis. By multivariate analysis, variables significant in univariate analysis, including ipsilateral multifocality (OR=2.21, 95% CI=1.11–4.40, $P = 0.03$), intact capsule (OR=2.54, 95% CI=1.24–5.19, $P = 0.01$), CNM (OR=3.00, 95% CI=1.21–7.49, $P = 0.02$), and HT (OR=2.08, 95% CI=.02–4.23, $P = 0.04$), were also remarkably associated with COPTC. To visualize the prediction factors, we plotted a forest plot presented in Figure 2. Then based on the output of multivariate logistic regression, we had a ROC curve to evaluate the combining potency of the four statistically significant predicting factors and find an appropriate cutoff point, presented in Figure 3. In ROC analysis, the area under the curve (AUC) of the predicting model of contralateral occult carcinoma was 0.701(95% CI= 0.620–0.782, $P < 0.001$), and the Youden Index (0.335) was used to obtain the cutoff value of the

model (cutoff = 2.02, sensitivity = 78.3%, and specificity = 55.2%), indicating the power of discriminating of the model is acceptable.

In Table 3, we further evaluated the association between the diameter of the occult lesions and the obtained variables but find that when 3 mm was used as the cutoff value, there was no statistical correlation between the diameter of occult tumor and the four obtained variables.

4. Discussion

Although the incidence of papillary thyroid cancer has increased worldwide over the recent years, the prognosis seems to remain stably excellent [19], and recurrence, rather than death, becomes the main burden of PTC patients, which partly has a relation with the approach and extent of initial surgery strategies. The option between total thyroidectomy and lobectomy plays a crucial role in discussing the strategy to treat papillary thyroid cancer. With increasing emphasis on risk-stratified management, lobectomy as an initial approach for unifocal tumors less than 4 cm without extrathyroidal extension (ETE) and LNM has been acceptable in some centers. With one lobe intact, patients may avoid complications relating to total thyroidectomy (such as hypocalcemia, hoarse, or even dysphonia) and prevent themselves from lifelong TSH repression therapy. Meanwhile, for those tumors < 1 cm (defined as papillary thyroid microcarcinoma, PTMC), milder tactics, always called active surveillance (AS), have been supported by some scholars for the reason of sluggishness of such mini tumors [20,21]. However, not all PTC has an excellent prognosis [22,23], and what is more important is that undetected contralateral occult thyroid carcinoma may lead to local-regional recurrence and even reoperation in those patients with clinical unilateral thyroid cancer. Furthermore, the precision of ultrasound in detecting lesions with diameters less than 5 mm was only 53.8% [10], and FNAC-diagnosed undetermined nodules also have a malignant risk of 18% or higher [24]. The effort to explore what kind of patients will benefit from total thyroidectomy is worthwhile.

In our study, the incidence of contralateral occult thyroid cancer is 20.1%. We found that multifocality of the ipsilateral lobe was an independent risk factor of the presence of COPTC in unilateral clinical PTC, meeting the same conclusion from some studies [25–28]. However, dissimilar to several previous studies [14,26], we excluded all the patients with contralateral nodules indicated by preoperative ultrasound, even those with TI-RADS < 3, for the reason of the limitation of the US to differentiate malignancies from benign nodules [29], which may lead to bias, and patients with occult contralateral benign nodules confirmed by postoperative pathology were assigned to control group. Several studies show that multifocality is an independent risk factor that predicts aggressive behavior and poor prognosis, even in terms of PTMC, for whom total thyroidectomy rather than lobectomy seems to be a preferable option. According to a large-scale cohort study from Kim [30], with a median follow-up period of 5 years, in patients who had a local recurrence, 58% of recurrent

TABLE 1: Distribution of clinical and pathological characteristics in 229 patients.

Variables	Group		F	Statistical values	
	Case (N = 46)	Control (N = 183)		Chi-square	P
Age, years, mean \pm SD	39.20 \pm 11.65	39.06 \pm 11.80	0.67		0.944
Gender, %				0.00	0.983
Female	32 (69.6)	127 (69.4)			
Male	14 (30.4)	56 (30.6)			
BMI, mean \pm SD	24.00 \pm 3.34	24.34 \pm 3.94	1.47		0.592
Multifocality, %				5.59	<0.05
Presence	24 (52.2)	61 (33.3)			
Absence	22 (47.8)	122 (66.7)			
Location, %				0.28	0.597
Upper	12 (26.1)	55 (30.1)			
Otherwise	34 (73.9)	128 (69.9)			
Diameter, %				0.32	0.574
<1 cm	18 (39.1)	80 (43.7)			
\geq 1 cm	28 (60.9)	103 (56.3)			
Diameter of COPTC %					
<3 mm	36 (78.3)	—			
\geq 3 mm	10 (32.7)	—			
Capsule, %				5.64	<0.05
Intact	20 (43.5)	47 (25.7)			
Invasion	26 (56.5)	136 (74.3)			
Trachea invasion, %				0.14	0.706
Presence	3 (6.5)	15 (8.2)			
Absence	43 (93.5)	168 (91.8)			
Strap muscle invasion, %				0.10	0.753
Presence	5 (10.9)	23 (12.6)			
Absence	41 (89.1)	163 (87.4)			
CNM, %				4.63	<0.05
Presence	39 (84.8)	126 (68.9)			
Absence	7 (15.2)	57 (31.1)			
LNM, %				1.24	0.265
Presence	32 (69.6)	111 (60.7)			
Absence	14 (30.4)	72 (39.3)			
B-RAF mutation, %				0.13	0.716
Presence	35 (76.1)	143 (78.6)			
Absence	11 (23.9)	39 (21.4)			
Serum Tg*, %				2.38	0.304
\leq 5 μ g/L	4 (10.3)	32 (20.4)			
5~40 μ g/L	20 (51.2)	77 (49.0)			
>40 μ g/L	15 (38.4)	48 (30.6)			
HT, %				4.52	<0.05
Presence	20 (43.5)	50 (27.3)			
Absence	26 (56.5)	133 (72.7)			

*Thirty-three patients did not have a preoperative serum thyroglobulin test.

tumors were found in the contralateral lobes that had not been treated during the initial operation, and TT significantly reduced the risk of overall local, regional recurrence as well as outside of the remnant lobe in patients with multifocality (adjusted HR = 0.284, $P = 0.002$; adjusted HR = 0.342, $P = 0.020$, respectively). However, this conclusion was the opposite in a retrospective study by Harries [31], suggesting that multifocality did not increase overall recurrence. Until today, the role of multifocality in recurrence remains controversial, and further large-sample cohort studies are needed for more valuable evidence.

In this case-control study, we also found that the integrity of the tumor capsule and the metastasis of the central lymph nodes are both predictors of COPTC. Traditionally, tumor encapsulation was regarded as the boundary between benignity and malignancy [32]. In our practice, the capsular invasion was also seen as a symbol of intrathyroidal extension in PTC. Previous studies showed that encapsulation was correlated with multifocality and CNM [16,33,34]; therefore, we established a linear regression model based on these three variables to eliminate collinearity (VIF = 1.006 and 1.009, respectively). Furthermore, there were also

TABLE 2: Univariate and multivariate analyses of predicting factors of COPTC.

Variables	Crude OR (95% CI)	P	Adjusted OR (95% CI)	B	Wald	P
Multifocality						
Absence	1		1			
Presence	2.18 (1.13–4.20)	0.02	2.21 (1.11–4.40)	0.79	5.06	0.03
Diameter						
< 1 cm	1					
≥ 1 cm	1.21 (0.62–2.34)	0.57				
Capsular						
Invasion	1		1			
Intact	2.23 (1.14–4.35)	0.02	2.54 (1.24–5.19)	0.93	6.61	0.01
CNM						
Absence	1		1			
Presence	2.52 (1.06–5.98)	0.04	3.00 (1.21–7.49)	1.10	5.57	0.02
LNM						
Absence	1	0.27				
Presence	1.48 (0.74–2.97)					
HT						
Absence	1		1			
Presence	2.05 (1.05–3.99)	0.04	2.08 (1.02–4.23)	0.73	4.09	0.04
B-RAF						
Negative	1	0.72				
Positive	0.87 (0.40–1.86)					

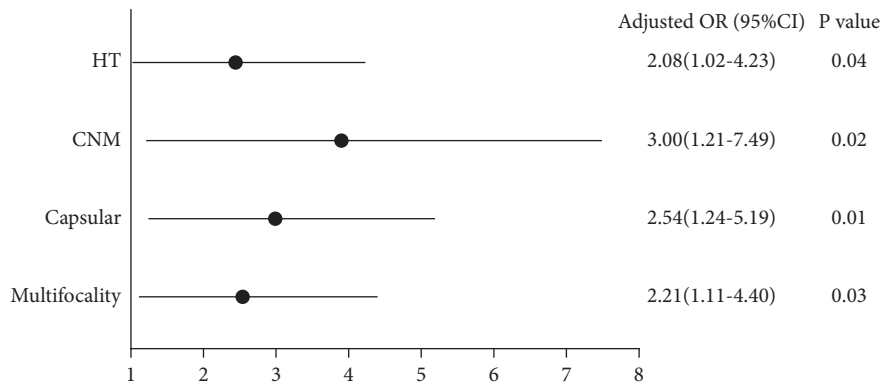


FIGURE 2: Forest plot of the significant factors in multivariate logistic regression of predicting contralateral occult papillary thyroid cancer.

studies [14,25,27], showing that capsular invasion was related to COPTC, which is contrary to our conclusion. That is interesting because some scholars defined multifocality as PTC with intrathyroidal extension with a hypothesis considering that the multiple foci result from a single primary lesion via intrathyroidal lymphatics [15]. However, there are also researchers who demonstrate that different foci may arise from different clonal copies that exhibit various biological behaviors from each other, underlying by some different gene mutations. In general, the causes of the multifocality of PTC are not clear. The volume may not present sequencing between the originally detected tumors and the COPTC. The value of capsular status needs to be discussed in the future.

Lymph node metastasis, especially CNM, where the most frequent recurrence occurs, is more common than an extrathyroidal extension or distant metastasis, the incidence of which reached up to 90%, and almost 50% of patients with

PTC present with CNM when prophylactic central lymph node dissection (CND) is performed [35]. We have obtained that CNM is an independent risk factor for contralateral thyroid carcinoma, similar to recent studies [24,36]. However, LNM did not appear to show statistical significance between the case and control groups, probably because all patients who underwent bilateral lateral lymph node dissection were excluded because they met the excluding criteria, and ipsilateral lateral lymph node dissection can lead to the unknown status of the contralateral neck region.

A similar conclusion was obtained in terms of B-RAF mutation. B-RAF presents in 77.7% of all patients included in our study, which is a subtype of RAF kinase, as an activation of the MAPK pathway, which plays an essential role in regulating tumor growth and proliferation [37], indicating a higher risk of recurrence and a worse prognosis [5]. Kim et al. [17,38] suggested that the B-RAF mutation was an independent predictor of bilateral thyroid cancer. Similarly,

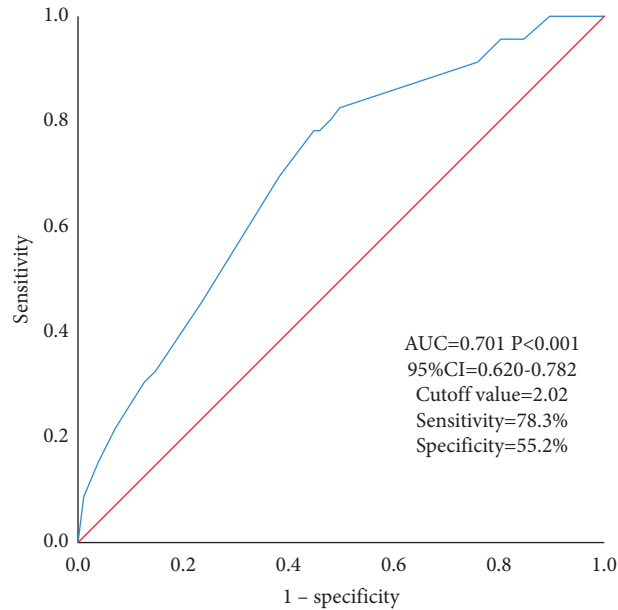


FIGURE 3: Receiver operating characteristic (ROC) curve to evaluate the combination prediction power of contralateral occult papillary thyroid cancer.

TABLE 3: Univariate and multivariate analyses between the diameter of the occult lesions and predictors.

Variables	Crude OR (95% CI)	P	Adjusted OR (95% CI)	P
Multifocality				
Absence	1		1	
Presence	1.50 (0.36–6.23)	0.58	1.46 (0.30–6.96)	0.64
Capsular				
Invasion	1		1	
Intact	2.09 (0.47–9.38)	0.34	2.19 (0.43–11.04)	0.34
CNM				
Absence	1		1	
Presence	0.65 (0.11–3.96)	0.64	0.33 (0.04–2.70)	0.30
HT				
Absence	1		1	
Presence	0.48 (0.11–2.15)	0.34	0.38 (0.07–1.99)	0.25

in a study that included 248 patients [39], Yan et al. also suggested that the presence of the B-RAF mutation played a pivotal role in the prediction of bilateral thyroid cancer. However, in other studies, this relationship is not significant in accordance with another case-control study by Lee et al. [14], similar to our findings. This diversity may be due to our insufficient sample, and a larger sample scale may help us obtain a more accurate conclusion. In addition, tumor diameter has always received a lot of attention in the fields of thyroid cancer study. Usually, tumors were divided into PTMC and non-PTMC according to a diameter equal to 1 cm, indicating potential biological differences between these two subtypes of PTC. Previous studies showed that tumor > 1 cm was an independent factor of COPTC [29,36], but we did not reach the same conclusion. Further larger sample size multicenter studies may contribute to a powerful conclusion.

The extrathyroidal extension (ETE) has been recognized as an indicator of recurrence and death in differentiated

thyroid cancer (DTC) [40]. The definition of ETE was the extension of the tumor outside the thyroid gland with invasion into surrounding structures such as the trachea, strap muscles, and recurrent laryngeal nerve (RLN). However, surgeons generally have difficulty differentiating between RLN and invasion of the trachea by the eyes. Consequently, RLN invasion was categorized as a subtype of trachea invasion. In our study, neither trachea nor strap muscle invasion was a significant indicator of the presence of COPTC. In fact, for patients with ETE, no matter if the association is absent or not, TT is always recommended, for ease of recurrence monitoring, and iodine therapy, due to the adverse future of such aggressive biological behaviors.

Hashimoto's thyroiditis is the most common autoimmune inflammatory disease of the thyroid, and the prevalence rate of PTC in patients with HT is 1.2% in fine-needle aspiration specimens and 27.6% in thyroidectomy specimens [41]. Some evidence has shown that autoimmune

inflammation is a risk factor for thyroid cancer [42,43], while PTC patients with HT seem to have a better outcome [44]. Previous studies showed that compared to Graves' disease, patients with chronic lymphocytic thyroiditis are more likely to have incidental thyroid cancer [45]. In this study, we found that HT was an indicator of contralateral occult thyroid cancer. In fact, chronic autoimmune inflammation is widely recognized to cause precancerous conditions through the expression of inflammation genes and the induction of genomic instability. However, convincing mechanisms are still being debated, and whether autoimmune inflammation will lead to bilateral multifocal thyroid cancer is also an inevitable question that will require more biological research in the future. Furthermore, based on many experiences at our center, we found that the thyroid with HT always behaves in a blood-rich, bulky, and heterogeneous state, which can also lead to difficulties finding tiny lesions for sonographers.

There are some limitations to our study. Firstly, patients with PTC with solitary clinical lesions, no imaging evidence of lymph node metastases, and unfavorable behaviors were more prone to be performed lobectomy at our center, so those included in this study were all in advanced disease status, resulting in an overestimation of the predictive power of lymph node metastases. Secondly, considering advances in ultrasound technology and improved imaging diagnostics, only patients in the last two years were considered in our study, leading to a restricted sample size. Thirdly, active surveillance in the management of papillary thyroid microcarcinoma (always diameter < 1 cm) has been accepted by more and more scholars [46]. Since the occult lesions in the contralateral lobe were all less than 5 mm in this study, we used 3 mm as the cutoff value to conduct a correlation analysis between the discovered four independent risk factors and the diameter, but no statistical correlation was found. In fact, further prospective clinical studies are needed to determine whether such occult cancers need to be managed. Finally, because the risk factors we found depend on pathological determination, physicians' choice of final surgical method may rely on intraoperative frozen section, generating pressure on surgeons and patient concerns. Consequently, future researchers should explore imaging, serology, and gene-based prediction factors further.

5. Conclusions

PTC patients with multifocality in one lobe, intact capsule, central lymph node metastasis, or HT are more prone to harbor contralateral occult thyroid carcinoma. These patients should undergo more accurate clinical assessments to facilitate more appropriate surgical and follow-up procedures. Furthermore, further studies are also needed to find precise serum and genome indicators that predict COPTC.

Data Availability

The data that support the findings of this study are available from the corresponding author upon reasonable request.

Conflicts of Interest

The authors declare that there are no conflicts of interest regarding the publication of this paper.

Acknowledgments

This study was funded by General Project of Natural Science Foundation of Henan Province (222300420568), Key Medical Science and Technology Project of Henan Province (SBGJ202101014), Major Scientific Research Projects of Traditional Chinese Medicine in Henan Province (20-21ZYZD14), Cultivation of Young and Middle-aged Health Science and Technology Innovation Leading Talents in Henan Province (YXKC2020015).

References

- [1] C. La Vecchia, M. Malvezzi, C. Bosetti et al., "Thyroid cancer mortality and incidence: a global overview," *International Journal of Cancer*, vol. 136, no. 9, pp. 2187–2195, 2015.
- [2] C. M. Kitahara and J. A. Sosa, "The changing incidence of thyroid cancer," *Nature Reviews Endocrinology*, vol. 12, no. 11, pp. 646–653, 2016.
- [3] J. P. Brito, J. C. Morris, and V. M. Montori, "Thyroid cancer: zealous imaging has increased detection and treatment of low risk tumours," *BMJ*, vol. 347, 2013.
- [4] J. H. Yoon, J. Y. Kwak, H. J. Moon, M. J. Kim, and E. K. Kim, "The diagnostic accuracy of ultrasound-guided fine-needle aspiration biopsy and the sonographic differences between benign and malignant thyroid nodules 3 cm or larger," *Thyroid*, vol. 21, no. 9, pp. 993–1000, 2011.
- [5] M. Xing, W. H. Westra, R. P. Tufano et al., "BRAF mutation predicts a poorer clinical prognosis for papillary thyroid cancer," *Journal of Clinical Endocrinology and Metabolism*, vol. 90, no. 12, pp. 6373–6379, 2005.
- [6] F. C. Holsinger, U. Ramaswamy, M. E. Cabanillas et al., "Measuring the extent of total thyroidectomy for differentiated thyroid carcinoma using radioactive iodine imaging," *JAMA Otolaryngology-Head & Neck Surgery*, vol. 140, no. 5, pp. 410–415, 2014.
- [7] A. Algeciras-Schimmich, "Thyroglobulin measurement in the management of patients with differentiated thyroid cancer," *Critical Reviews in Clinical Laboratory Sciences*, vol. 55, no. 3, pp. 205–218, 2018.
- [8] B. Schmidbauer, K. Menhart, D. Hellwig, and J. Grosse, "Differentiated thyroid cancer-treatment: state of the art," *International Journal of Molecular Sciences*, vol. 18, 2017.
- [9] L. R. Remonti, C. K. Kramer, C. B. Leitão, L. C. Pinto, and J. L. Gross, "Thyroid ultrasound features and risk of carcinoma: a systematic review and meta-analysis of observational studies," *Thyroid*, vol. 25, no. 5, pp. 538–550, 2015.
- [10] S. M. Ha, J. K. Kim, and J. H. Baek, "Detection of malignancy among suspicious thyroid nodules <1 cm on ultrasound with various thyroid image reporting and data systems," *Thyroid*, vol. 27, no. 10, pp. 1307–1315, 2017.
- [11] B. R. Haugen, E. K. Alexander, K. C. Bible et al., "2015 American thyroid association management guidelines for adult patients with thyroid nodules and differentiated thyroid cancer: the American thyroid association guidelines task force on thyroid nodules and differentiated thyroid cancer," *Thyroid*, vol. 26, pp. 1–133, 2016.

- [12] M. Luster, C. Aktolun, I. Amendoeira et al., "European perspective on 2015 American thyroid association management guidelines for adult patients with thyroid nodules and differentiated thyroid cancer: proceedings of an interactive international symposium," *Thyroid*, vol. 29, no. 1, pp. 7–26, 2019.
- [13] S. Y. Park, Y. S. Jung, C. H. Ryu et al., "Identification of occult tumors by whole-specimen mapping in solitary papillary thyroid carcinoma," *Endocrine-Related Cancer*, vol. 22, no. 4, pp. 679–686, 2015.
- [14] Y. C. Lee, Y. G. Eun, Y. M. Sohn et al., "Predictive factors for occult contralateral carcinoma in patients with unilateral papillary thyroid microcarcinoma by preoperative ultrasonographic and pathological features," *World Journal of Surgery*, vol. 39, no. 7, pp. 1736–1741, 2015.
- [15] N. Wang and L. X. Qian, "Predictive factors for occult bilateral papillary thyroid carcinoma," *Academic Radiology*, vol. 28, no. 3, pp. 328–332, 2021.
- [16] J. L. Roh, J. M. Kim, and C. I. Park, "Central lymph node metastasis of unilateral papillary thyroid carcinoma: patterns and factors predictive of nodal metastasis, morbidity, and recurrence," *Annals of Surgical Oncology*, vol. 18, no. 8, pp. 2245–2250, 2011.
- [17] S. K. Kim, I. Park, J. W. Woo, J.-H. Choe, J.-H. Kim, and J. S. Kim, "Predicting factors for bilaterality in papillary thyroid carcinoma with tumor size <4 cm," *Thyroid*, vol. 27, no. 2, pp. 207–214, 2017.
- [18] L. S. Albinsaad, W. W. Kim, Y. M. Lee, T. Y. Sung, K. W. Chung, and S. J. Hong, "The appropriateness of thyroid lobectomy as an initial surgery for preoperatively detected unilateral multifocal papillary carcinoma," *Asian Journal of Surgery*, vol. 44, no. 8, pp. 1050–1055, 2021.
- [19] L. Davies and H. G. Welch, "Current thyroid cancer trends in the United States," *JAMA Otolaryngology-Head & Neck Surgery*, vol. 140, no. 4, pp. 317–322, 2014.
- [20] R. M. Tuttle, J. A. Fagin, G. Minkowitz et al., "Natural history and tumor volume kinetics of papillary thyroid cancers during active surveillance," *JAMA Otolaryngology-Head & Neck Surgery*, vol. 143, no. 10, pp. 1015–1020, 2017.
- [21] H. M. Gweon, E. J. Son, J.-A. Kim, and J. H. Youk, "Predictive factors for active surveillance of subcentimeter thyroid nodules with highly suspicious US features," *Annals of Surgical Oncology*, vol. 24, no. 6, pp. 1540–1545, 2017.
- [22] J. C. McCaffrey, "Aerodigestive tract invasion by well-differentiated thyroid carcinoma: diagnosis, management, prognosis, and biology," *The Laryngoscope*, vol. 116, no. 1, pp. 1–11, 2006.
- [23] K. Segal, T. Shpitzer, A. Hazan, G. Bachar, G. Marshak, and A. Popovtzer, "Invasive well-differentiated thyroid carcinoma: effect of treatment modalities on outcome," *Otolaryngology-Head and Neck Surgery*, vol. 134, no. 5, pp. 819–822, 2006.
- [24] J. W. Feng, J. Ye, W. X. Wu, H. Pan, and A.-C. Qin, "Management of clinically solitary papillary thyroid carcinoma patients according to risk-scoring model for contralateral occult carcinoma," *Frontiers in Endocrinology*, vol. 11, 2020.
- [25] T. Lv, C. Zhu, and Z. Di, "Risk factors stratifying malignancy of nodules in contralateral thyroid lobe in patients with preoperative ultrasound indicated unilateral papillary thyroid carcinoma: a retrospective analysis from single centre," *Clinical Endocrinology*, vol. 88, no. 2, pp. 279–284, 2018.
- [26] B. S. Koo, H. S. Lim, and Y. C. Lim, "Occult contralateral carcinoma in patients with unilateral papillary thyroid microcarcinoma," *Annals of Surgical Oncology*, vol. 17, no. 4, pp. 1101–1105, 2010.
- [27] F. Zhang, B. Zheng, X. Yu, X. Wang, S. Wang, and W. Teng, "Risk factors for contralateral occult carcinoma in patients with unilateral papillary thyroid carcinoma: a retrospective study and meta-analysis," *Frontiers in Endocrinology*, vol. 12, Article ID 675643, 2021.
- [28] K. J. Lee, Y. J. Cho, J. G. Kim, and D. H. Lee, "How many contralateral papillary thyroid carcinomas can be missed?" *World Journal of Surgery*, vol. 37, no. 4, pp. 780–785, 2013.
- [29] Z. G. Wu, X. Q. Yan, R. S. Su, Z. S. Ma, B. J. Xie, and F. L. Cao, "How many contralateral carcinomas in patients with unilateral papillary thyroid microcarcinoma are preoperatively misdiagnosed as benign?" *World Journal of Surgery*, vol. 41, no. 1, pp. 129–135, 2017.
- [30] S. K. Kim, I. Park, J. W. Woo, J. H. Lee, and J.-H. Choe, "Total thyroidectomy versus lobectomy in conventional papillary thyroid microcarcinoma: analysis of 8,676 patients at a single institution," *Surgery*, vol. 161, no. 2, pp. 485–492, 2017.
- [31] V. Harries, L. Y. Wang, M. McGill et al., "Should multifocality be an indication for completion thyroidectomy in papillary thyroid carcinoma?" *Surgery*, vol. 167, no. 1, pp. 10–17, 2020.
- [32] M. Nishino and J. Jacob, "Invasion in thyroid cancer: controversies and best practices," *Seminars in Diagnostic Pathology*, vol. 37, no. 5, pp. 219–227, 2020.
- [33] K. Cupisti, N. Lehwald, M. Anlauf et al., "Encapsulation status of papillary thyroid microcarcinomas is associated with the risk of lymph node metastases and tumor multifocality," *Hormone and metabolic research = Hormon- und Stoffwechselforschung = Hormones et metabolisme*, vol. 46, pp. 138–144, 2014.
- [34] D. Akbulut, E. D. Kuz, N. Kursun, and S. Dizbay Sak, "Capsular invasion matters also in "papillary patterned" tumors: a study on 121 cases of encapsulated conventional variant of papillary thyroid carcinoma," *Endocrine Pathology*, vol. 32, no. 3, pp. 357–367, 2021.
- [35] H. Zhao, T. Huang, and H. Li, "Risk factors for skip metastasis and lateral lymph node metastasis of papillary thyroid cancer," *Surgery*, vol. 166, no. 1, pp. 55–60, 2019.
- [36] X. Chen, Z. Zhong, M. Song et al., "Predictive factors of contralateral occult carcinoma in patients with papillary thyroid carcinoma: a retrospective study," *Gland Surgery*, vol. 9, no. 4, pp. 872–878, 2020.
- [37] Cancer Genome Atlas Research Network, "Integrated genomic characterization of papillary thyroid carcinoma," *Cell*, vol. 159, pp. 676–690, 2014.
- [38] S. K. Kim, J. W. Woo, J. H. Lee et al., "Role of BRAF V600E mutation as an indicator of the extent of thyroidectomy and lymph node dissection in conventional papillary thyroid carcinoma," *Surgery*, vol. 158, no. 6, pp. 1500–1511, 2015.
- [39] C. Yan, M. Huang, X. Li, T. Wang, and R. Ling, "Relationship between BRAF V600E and clinical features in papillary thyroid carcinoma," *Endocrine Connections*, vol. 8, no. 7, pp. 988–996, 2019.
- [40] T. Ibrahimasic, R. Ghossein, J. P. Shah, and I. Ganly, "Poorly differentiated carcinoma of the thyroid gland: current status and future prospects," *Thyroid*, vol. 29, no. 3, pp. 311–321, 2019.
- [41] S. I. Noureldine and R. P. Tufano, "Association of Hashimoto's thyroiditis and thyroid cancer," *Current Opinion in Oncology*, vol. 27, no. 1, pp. 21–25, 2015.
- [42] S. D. Larson, L. N. Jackson, T. S. Riall et al., "Increased incidence of well-differentiated thyroid cancer associated with Hashimoto thyroiditis and the role of the PI3k/Akt pathway,"

Journal of the American College of Surgeons, vol. 204, no. 5, pp. 764–773, 2007.

- [43] Y. Lun, X. Wu, Q. Xia et al., “Hashimoto’s thyroiditis as a risk factor of papillary thyroid cancer may improve cancer prognosis,” *Otolaryngology-Head and Neck Surgery*, vol. 148, no. 3, pp. 396–402, 2013.
- [44] M. Ehlers and M. Schott, “Hashimoto’s thyroiditis and papillary thyroid cancer: are they immunologically linked?” *Trends in Endocrinology and Metabolism*, vol. 25, no. 12, pp. 656–664, 2014.
- [45] R. D. Papanicolaou, E. Karvounis, D. Bantouna et al., “Incidentally discovered papillary thyroid microcarcinomas are more frequently found in patients with chronic lymphocytic thyroiditis than with multinodular goiter or Graves’ disease,” *Thyroid*, vol. 30, no. 4, pp. 531–535, 2020.
- [46] I. Sugitani, Y. Ito, D. Takeuchi et al., “Indications and strategy for active surveillance of adult low-risk papillary thyroid microcarcinoma: consensus statements from the Japan association of endocrine surgery task force on management for papillary thyroid microcarcinoma,” *Thyroid*, vol. 31, no. 2, pp. 183–192, 2021.