Hindawi
International Journal of Zoology
Volume 2021, Article ID 3151609, 7 pages
https://doi.org/10.1155/2021/3151609

Research Article

Gross Anatomy and Histological Features of *Gymnarchus niloticus* (Cuvier, 1829) from the River Niger at Agenebode in Edo State, Nigeria

M. O. Agbugui,[1] **F. E. Abhulimen**,[1] **and H. O. Egbo**[2]

[1]*Department of Biological Sciences, Edo State University Uzairue, Iyamho, Edo, Nigeria*
[2]*Department of Morbid Anatomy and Histopathology, Edo State University Uzairue, Iyamho, Edo, Nigeria*

Correspondence should be addressed to M. O. Agbugui; agbugui.marian@edouniversity.edu.ng

Received 8 April 2021; Revised 28 May 2021; Accepted 11 June 2021; Published 19 June 2021

Academic Editor: Joao Pedro Barreiros

This study was conducted to record the anatomy and histological features of the gastrointestinal tract of the trunk fish *Gymnarchus niloticus* captured at Agenebode in the Lower River Niger, Edo State. The gastrointestinal tract was segmented into the mouth, oesophagus, stomach, pyloric caeca, and intestine. The slender (taeniform) body that is fuller at the head tappers at its end. There are no spines on this fish, and the fins used for locomotion are the dorsal fins and not the typical pectoral fins as in other fish. The oesophagus, stomach, pyloric caeca, intestine, and cloaca (anterior, intermediate, posterior, and rectum) were analysed for histological examination. The stomach had significantly higher villi and thicker inner circular muscles compared to the intestine and oesophagus. The lamina propria was thickest in the stomach which is significantly higher when compared with the oesophagus, but not with the intestine. However, the intestine showed significantly thicker outer longitudinal muscle, while gastric glands were observed only in the stomach. The histological features were closely associated with the functions of the different segments of the gastrointestinal tract. In conclusion, the histological features of the gastrointestinal tract of *G. niloticus* are consistent with the feeding habit of a carnivorous fish. In conclusion, the GIT is a complex structure composed of organs that reveals that it is a higher vertebrate created for a hardy survival, consistent with the feeding habit of a carnivorous fish. The histology reveals a GIT formed by four conspicuous layers from the inside to the outside of the mucosa, submucosa, and an inner longitudinal layer of the muscularis and the outer circular of the muscularis typical of higher vertebrates.

1. Introduction

Gymnarchus niloticus (Cuvier 1829), commonly known as the Nile knife fish, trunk fish, or aba, is one of the most valued fishes along the River Niger mostly by the inhabitants of Agenebode and Idah. The trunk fish is highly valued for its good taste, rich nutrients, though oily flesh, ability to grow as large as 25 kg, highly valued in customary rites for marriage and community celebrations. The aforementioned makes the trunk fish a highly priced economic commodity which is often preferred fresh or smoked. It is called eta by the Afemai of Bode, Asa in Idah.

G. niloticus is endemic to the freshwaters of tropical Africa. It is an electric fish and the only species in the genus Gymnarchus, family Gymnarchidae. Despite these attributes and imports, *G. niloticus* has not received any extensive study of its biology [1].

In recent times, *G. niloticus* has been enlisted as an endangered species in Nigeria, although it is classified as least concerned (LC) to the rest of the continent [2]. Its decline (due to irregular and unauthorized fishing practices, destruction of habitat, overfishing, and human activities along the river) as a need for conservation has been reported by [3, 4]. To avoid this highly and economically valued fish from going into extinction, crucial measures need to be put in place to enhance the preservation of this fish species, protecting its habitat, breeding, production, culture, and propagation at a commercial scale. It is, therefore, necessary that ample knowledge of the biology of *G. niloticus* be studied to provide maximal information that should provide

baseline information with a view to effectively manage the species for sustainable fisheries. Hence, this research is aimed at the study of the biology of *G. niloticus* in the River Niger at Agenebode to determine the anatomy and physiology and histology of its mouth and gastrointestinal tract.

2. Materials and Methods

2.1. Study Area and Description. The River Niger is the longest river in West Africa discharging into the Atlantic Ocean in Nigeria. It rises up to 240 km and runs 4180 km. The river is known to harbour 36 families of fresh water fish and nearly 250 species of which 20 are found nowhere else on Earth but Nigeria. From Lokoja, the lower part of the River Niger, the river runs through Agenebode-Ida, to Forcados in delta, then the Nun River in rivers, and further. The river is clean, relatively clear, carrying only a tenth of much sediment. The River Niger floods yearly beginning from September and peaks in November to January. Agenebode is located at latitude 7.10512 and longitude 6.69381 and stretches through an area of 1133 km^2 (Figure 1). Agenebode water front is a very busy part of the Niger located in Edo State, Nigeria, serving portable water for domestic and industrial uses. Active fishing activities take place along the river for subsistence and commercial fishing.

2.2. Collection and Preparation of Specimens. Twenty samples of *G. niloticus* comprising different sizes (length and weight) were purchased from fisher folks at landing sites of fisher folks using nets, traps, and baskets in the River Niger at Agenebode, Edo State, Nigeria. Immediately after collection, the samples were rinsed with water and wiped dry. Samples of fishes were transported to the Laboratory of the Department of Biological Sciences, Edo State University Uzairue, Edo State. Fishes were rinsed, wiped dry, and identified to species level using guides, keys, and pictures provided by [5–7]. The mouths and intestinal tracts were removed. The oesophagus, stomach, and intestines were gently slit open; their contents were rinsed off in gently flowing tap water and, thereafter, fixed in 10% formaldehyde.

2.3. Anatomy and Histology. The samples were then dehydrated through a standard ethanol series to 100%, cleared in xylene and embedded in paraffin wax, then sectioned with a rotatory microtome set at 5-6 pm, deparaffinized, and stained with haemotoxylin and eosin. Prepared slides of the gastrointestinal tract will be mounted and examined with the electronic Olympus microscope (model Bino Cxi IS4381) (PL120) to view and capture features of biological interest.

Pictures of the mouth, jaws, and pharyngeal teeth are taken with digital Samsung camera (Model X650B).

3. Results

G. niloticus possesses a long, slender (taeniform) body that is fuller at the head and tappers at its end. The body has no caudal fins, anal fins, and pelvic fins. The dorsal fin stretches to its tail and making it blunt, the fins have no spines, the straight head of the trunk fish is devoid of scales, but the entire body is covered with small cycloid scales. There are no spines on fins or body of this fish. The tail is the main organ used for locomotion. The dorsal fin and pectoral fins consist of soft rays. *G. niloticus* does not exhibit sexual dimorphism. The small mouth of the trunk fish is terminal, nonretractable, and opens up to 5% of its total body length; the head is covered with thick flesh making the eyes well proofed. There are two pairs of nostrils on the head for efficient intake of air (Figures 2–4). Figure 5 shows the gap mouth of *G. niloticus* with its thick tongue that is protrusible.

The mandibular teeth (lower jaw) and maxillary teeth are equipped with one row of nonfused incisor teeth. The tongue is long and thick and has no teeth. There are no pharyngeal teeth in the mouth.

Four gills are present on the left and right side of the fish. These gills are small and bony, and prominent gill arches, gill rackers (11), and gill filaments are fused in pairs (63 pairs).

G. niloticus possesses a gastrointestinal tract (GIT) that is composed of long and longitudinally organized organ of a long and tubular oesophagus, long tubular stomach, one lung, two pyloric caeca, a straight intestine, and cloaca that were well enveloped by the peritoneal serosa (Figure 6). Figure 7 shows the composite and neat arrangement of the GIT. The intestine is neatly folded and compacted to accommodate its length in the stomach of the fish. The oesophagus leads to a long extensible, tubular-shaped stomach with a posterior rounded end.

On one side of the stomach arises a pair of long pyloric caeca. The left side of the stomach reveals the intestine that is 78% of the total body length and ends in the cloaca. The stomach is hardly visibly distinguished in with an anterior large intestine and a posterior small intestine.

A single lung arises from a slit in the right side of the pharynx seated on the right side of the fish, and these organs are held together by sheaths of connective tissue and blood vessels. The liver and pancreas are located on the right side of the stomach.

The guts of *G. niloticus* were formed by four major layers, which is typical of higher vertebrate animals composed of four conspicuous layers from the inside to the outside of mucosa, submucosa, and inner longitudinal layer of the muscularis and outer circular of the muscularis (Figures 8–10).

The gastrointestinal tract of the Nile aba revealed typical layers seen in fish: the serosa, muscle layers (circular and longitudinal muscle layers), submucosa, and mucosa (Figure 8). The structure of the oesophagus was a long and wide tube with numerous longitudinal folds in the mucosa, and the columnar epithelium had numerous goblet cells. The stomach of *G. niloticus* was a long tubular-shaped organ; its mucosa was thick, dense, and filled with numerous glandular structures; the columnar epithelium revealed numerous gastric pits, gastric glands, and gastric cells (Figure 9). The intestine was a straight tube that was not distinguished into small and large intestine and ends in the cloaca (Figure 10).

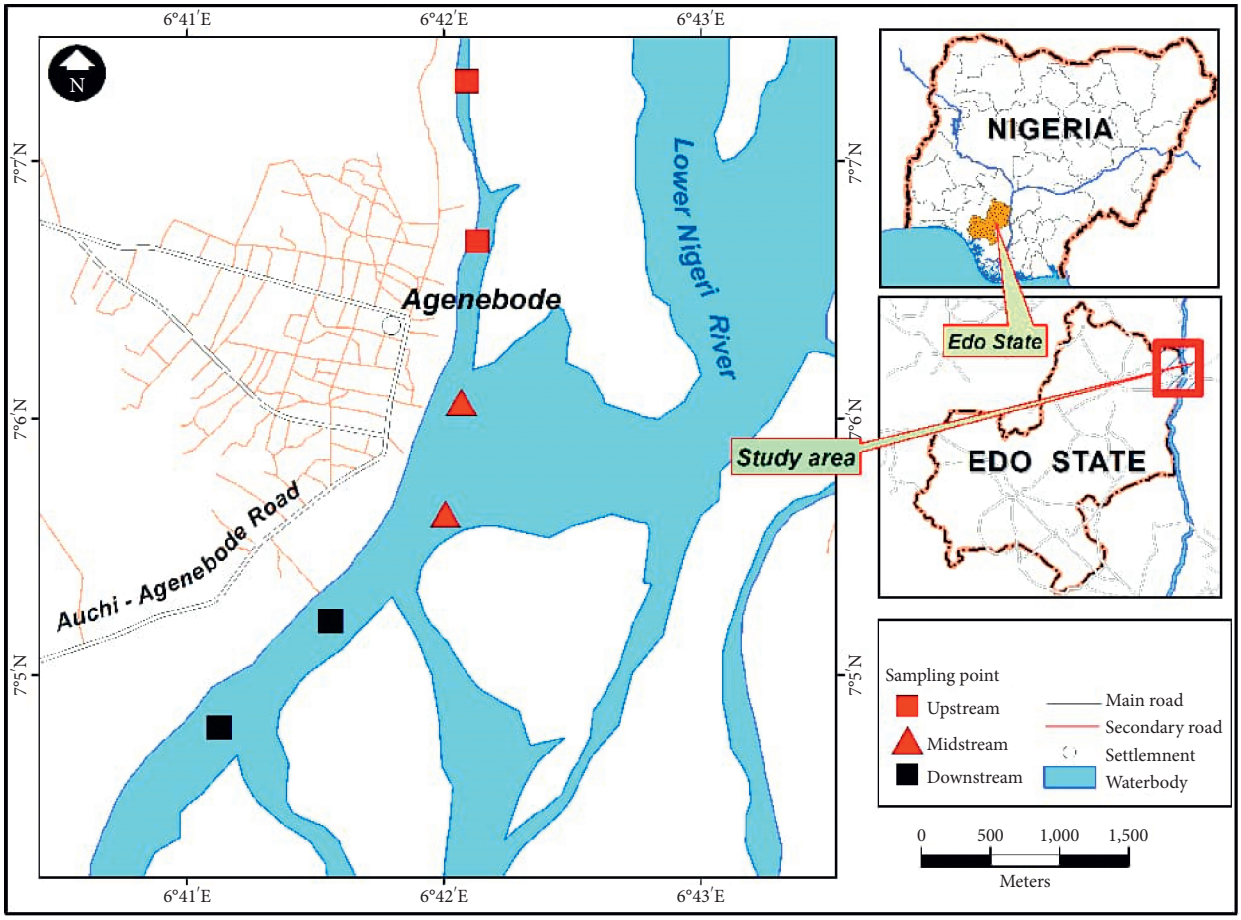

Figure 1: Map of the study area showing sampling stations.

Figure 2: Body of *Gymnarchus niloticus*.

4. Discussion

The body of *G. niloticus* is long, slender (taeniform) with no scales on the straight head, no caudal fin, anal fins, and pelvic fins. The dorsal fin extends to the end of a blunt tail with no spines; the entire body is covered with small cycloid scales. With no prominent paired fins, the tail, like most marine fish, is used for movement and gliding from place to place in its environment. *G. niloticus* does not exhibit sexual dimorphism. Hence, the exposure of the internal cavity is the most appropriate way to sex the fish is the presence or absence of ovaries to classify as males or females. The ossified nonretractable mouth, which opens to 5% of the species total body length, enables the niloticus to swallow a prey 5% of its size, bearing in mind that the slim mouth, throat, and oesophagus should naturally prefer small-sized prey. The presence of nonfused incisors avails the fish with the opportunity to tear the prey immediately when it gets into the mouth. The long thick tongue which is devoid of teeth probably holds the prey in place for swallowing. The gills possess paired and numerous gill filaments making it possible to filter small food particles and retain many small-sized food items. The long, elongated, and tubular gut of *G. niloticus* is a typical characteristic of bottom dwelling carnivorous species.

On one side of the stomach arises a pair of long pyloric caeca. The left side of the stomach reveals the intestine that is 78% of the total body length and ends in the cloaca. The stomach is hardly visibly distinguished in with an anterior large intestine and a posterior small intestine.

Figure 3: Head of *Gymnarchus niloticus* showing two pairs of nostrils, eyes, and a pair of pectoral fins.

Figure 4: Gap mouth of *Gymnarchus niloticus*.

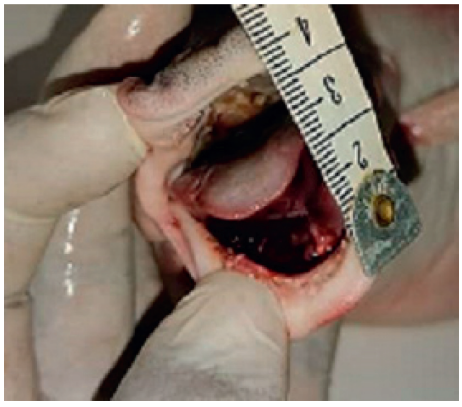

Figure 5: Gape mouth of *G. niloticus* showing long thick tongue.

A single lung arises from a slit in the right side of the pharynx seated on the right side of the fish, and these organs are held together by sheaths of connective tissue and blood vessels. The liver and pancreas are located on the right side of the stomach.

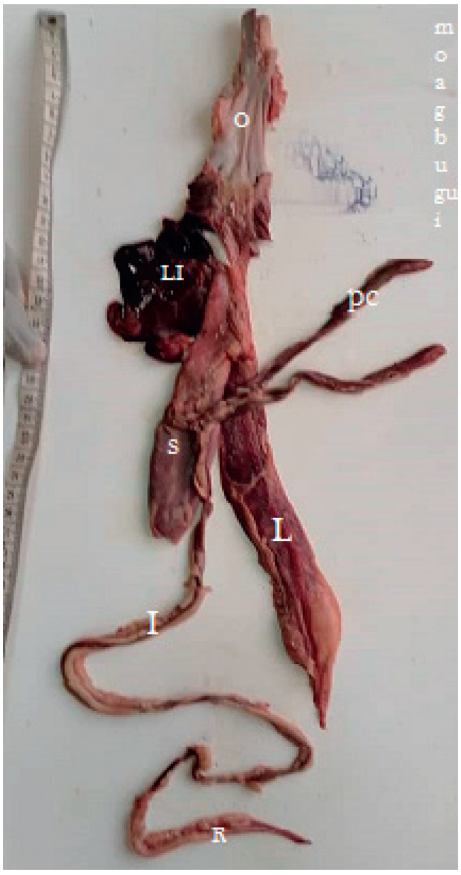

Figure 6: Alimentary canal of *G. niloticus*. o: oesophagus; LI: liver; s: stomach; pc: pyloric caeca; L: lungs; I: intestine; R: rectum.

The guts of *G. niloticus* were formed by four major layers, which are typical of higher vertebrate animals. The oesophagus is composed of four conspicuous layers from the inside to the outside of the mucosa, submucosa, and an inner longitudinal layer of the muscularis and the outer circular of the muscularis. The mucosa showed large amounts of the esophageal length of the lumen of the oesophagus giving oval-shaped appearance in all sections. The submucosa had numerous rounded folds which were broad, thick with numerous gastric glands. The longitudinal muscle fibre was distinct. It is worthy of note that the thickness of mucosal projections and the thickness of muscularis of the oesophagus greatly decreased from the anterior to the posterior part. This may be because the anterior oesophagus first receives food and will need greater contraction and movements to move the food bolus caudally during peristalsis. It is also reported that the muscularis layer of carnivorous fish is thick, which is to prevent any damage or engorgement to the mucosa during swallowing of prey [8–10]. The stomach of *G. niloticus* is a long tube that can be stretched longitudinally, suggesting a feeding pattern of carnivorous fish. The organ can act as a holding area for larger bolus such as small fish that they eat. The histology of this stomach showed dense regions of the gastric gland

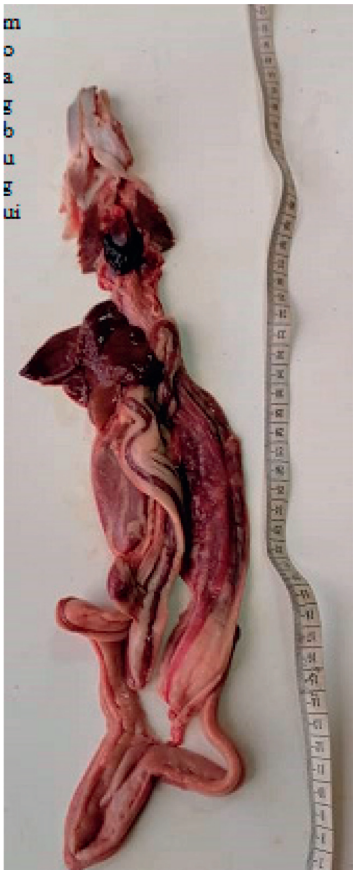

Figure 7: The gut enveloped in peritoneum serosa. The intestines are folded in a "U"-shaped form to accommodate length.

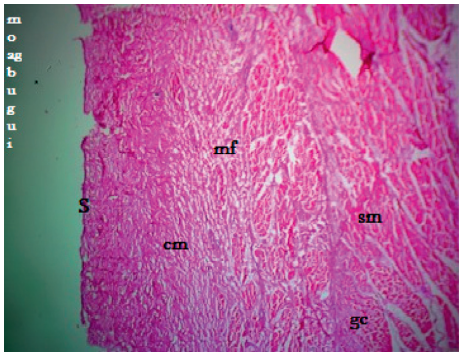

Figure 8: LM of the oesophagus of *G. niloticus*. s: serosa; cm: circular muscle; mf: muscle fibre; SM: submucosa; GC: goblet cells.

revealing gastric cells. The mucosa of the stomach consists of surface and gastric epithelium. The surface epithelium is made up of a single layer of columnar epithelial cells, and the gastric epithelium consists of gastric glands. The longitudinal muscle fibre is thicker than the circular muscle fibre. The gastric glands are at the base of the submucosa. The columnar epithelium is visible in cells. In the pyloric caeca, the muscularis consists of the outer longitudinal and an inner thick circular muscle layer and the submucosa has many mucus secreting cells with a visible columnar epithelium which agree with the findings of [11]. The mucosa is

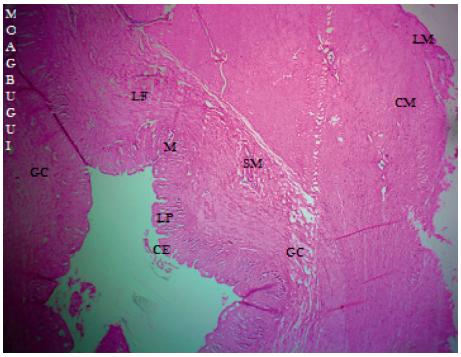

Figure 9: LM of the stomach of *G. niloticus*. GC: goblet cell; LF: longitudinal fibre; SM: submucosa; M: mucosa; PL: lamina propria; CE: columnar epithelium.

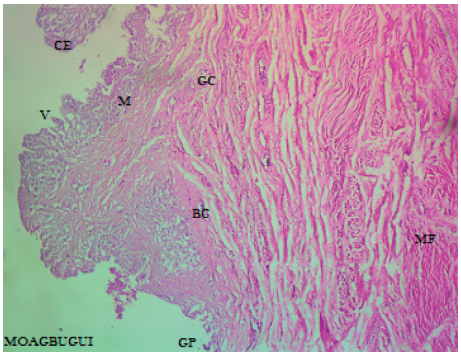

Figure 10: LM of the intestine of *G. niloticus*. M: mucosa; GC: goblet cell; MF: muscle fibre; GP: gastric pits; V: villi; CE: columnar epithelium.

short. The intestine is a slender elongated tubular organ where food from the stomach passes through to start an alkaline digestion before the absorption of nutrients [12]. In fish, the length of the intestine varies and depends on the diet. The amount of vegetal material in diet is the main determination factor for intestinal length. Usually, herbivorous fish have longer intestines compared to carnivorous fish [13]. In this study, however, the feeding habits show a carnivorous diet. Fish, crustaceans, and arthropods were the main components of the diet found in the alimentary canal. A preference for fleshy food and prey was observed as the fish size increased. The length of the intestine could probably be attributed to the length of the fish and to provide measure for adequate digestion and nutrient absorption of flesh. In this study, the intestinal segments did not show any difference histologically. In the intestine, gastric pits, and glands, the mucosal folds are numerous, and the presence of large villi is prominent. The columnar epithelium is distinct. The intestine has a thick and dense circular muscle, the submucosa has very reduced gastric glands and gastric pits, and the columnar epithelium and lamina propria is short. The authors of [14] reported that, in the intestine, the columnar surface epithelial cells are arranged with long fibrovascular cores to produce a pattern of villi, increasing the absorptive surface area. There are increasing numbers of pale, mucin-secreting goblet cells intermixed in the

epithelium. The lamina propria underlies the epithelium and, just beneath, is thin muscularis mucosae. The brush border epithelium of the intestine of *G. niloticus* is similar to that found in the carnivorous species *Anguilla bicolor*, *Anguilla Anguilla*, and *Salvelinus alpinus.* An increase in the number of goblet cells was found in the posterior region of the intestine. These differences are important in the process of expulsion of feces that needs mucus substances for lubrication to ease the excretion [15]. This study revealed that the thickness of intestinal villi gradually decreased from the anterior to the posterior section. The remnants of food particles that were not absorbed in the anterior intestine then migrate into the intermediate intestine where the absorption process continues. Since the amounts of food particles that migrate to the intermediate and posterior intestine were lesser, the number and length of villi were significantly reduced. The fishes demonstrated the highest villi measurement when observed in the anterior part of the intestine, compared to the posterior part. Finally, the remaining unabsorbed food particles and wastes migrate into the rectum, waiting to be removed from the body through the anus. The villous folding and microvilli function to increase the intestinal surface areas, which are important for nutrient absorption. The muscularis of *G. niloticus* was divided into an inner circular layer and an outer longitudinal layer, which agreed with the findings of [8]. Carnivorous fish consume various kinds of protein sources and need strong muscle contraction at the rectal area to defecate [16]. The propulsive contractions are caused by the muscularis externa. Because of this the thickness of the muscle is more remarkable at the posterior part of the intestine. The findings agreed with the findings of [16].

5. Conclusion

The results obtained from this study show the following:

(1) The anatomical organization and histology of the mouth and gastrointestinal tract of *Gymnarchus niloticus*

(2) The GIT is a complex structure composed of organs that reveals that it is a higher vertebrate created for a hardy survival, consistent with the feeding habit of a carnivorous fish

(3) The histology reveals a GIT formed by four conspicuous layers from the inside to the outside of the mucosa, submucosa, and an inner longitudinal layer of the muscularis and the outer circular of the muscularis typical of higher vertebrates

Data Availability

The data used to support the findings of this study are available within the article.

Ethical Approval

The care and use of experimental animals in this study were obtained from catch landings of fisher folks. Fishes are for sale and as such can be used for research.

Conflicts of Interest

The authors declare that there are no conflicts of interest regarding the publication of this paper.

Acknowledgments

This research was self-funded. The authors acknowledge Prof. Sunnie Joshua Oniye for research mentorship and Mr. Fran E. Abhulimen, Department of Biological Science, Laboratory Science Unit, Edo State University Uzarue, Edo State, Nigeria, for dissection and laboratory assistance.

References

[1] R. Froese and Pauly, "Distribution of *Gymnarchus niloticus. Gymnarchus niloticus*," 2020, http://www.fishbase.com.

[2] A. Azeroual, M. Entsua-Mensah, A. Gethun, P. Laleye, T. Moelants, and E. Vreven, "Gymnarchus niloticus," *IUCN red list of threaatened species*, 2010.

[3] B. A. Falaye, S. O. E. Sadiku, A. N. Okaeme, and A. A. Eyo, "Preliminary investigation into implication of a single cell organism in fish feed bouyancy and flotation," in *Proceedings of the 19th Annual Conference of the Fisheries Society of Nigeria (FISON)*, pp. 493–499, Fisheries Society of Nigeria, Ilorin, Nigeria, September 2005.

[4] M. O. Agbugui and J. Umaru, "*Gymnarchus niloticus* (Cuvier, 1830), a threatened fish species in the lower river Niger at Agenebode, Nigeria; the need for its conservation," *International Journal of Fisheries and Aquatic Research*, vol. 6, no. 1, pp. 54–65, 2020.

[5] W. Reed, J. Burchard, A. J. Hopson, J. Jenness, and I. Yaro, *Fish and Fisheries of Northern Nigeria*, Vol. 22, Ministry of Agriculture, Abuja, Nigeria, 1967.

[6] K. Pandey and J. P. Shukla, *Fish and Fisheries. A Text Book for University Students*, Rastogic Publications, Meerut, India, 2005.

[7] R. Froese and Pauly, "*Gymnarchus niloticus*," 2021, http://www.fishbase.com.

[8] N. S. Nasruddin, M. N. A. Azmai, A. Ismail, M. A. Saad, H. M. Daud, and S. Z. Zulkifli, "Histological features of the gastrointestinal tract of wild Indonesian shortfin eel, *Anguilla bicolor bicolor* (McClelland, 1844), captured in peninsular Malaysia," *The Scientific World Journal*, vol. 2014, Article ID 312670, 8 pages, 2014.

[9] M. O. Agbugui, S. J. Oniye, J. Auta, and P. T. Bolorundo, "Gastrointestinal tract of *Pomadasys jubelini* (curvier, 1860) in the new calabar-bonny river, rivers state, Nigeria," *International Journal of Engineering and Scientific Research*, vol. 7, no. 10, pp. 1086–1105, 2016.

[10] M. O. Agbugui and S. J. Oniye, "The mouth and gastro-intestinal tract of the lung fish *Protopterus annectens* (owen, 1839) in River Niger at Agenebode, Edo state, Nigeria," *Egyptian Journal of Aquatic Biology and Fisheries*, vol. 23, no. 4, pp. 181–188, 2019.

[11] B. L. Silagan, "Histology of the digestive system," 2011, https://www.slideshare.net/IamBrentsls/histology-of-digestive-system-stomach-small-intestines.

[12] B. W. S. Canan, N. B. Nascimento, D. Silva, and S. Chellappa, "Morphohistology of the digestive tract of the damsel fish *Stegastes fuscus* (Osteichthyes: pomacentridae)," *The Scientific World Journal*, vol. 9, 2012.

[13] N. E. R. El-Bakary and H. L. El-Gammal, "Comparative histological, histochemical and ultrastructural studies on the

proximal intestinal of flathead grey mullet (*Mugil cephalus*) and sea bream (*Sparus aurata*)," *World Applied Science Journal*, vol. 8, no. 4, pp. 477–485, 2010.

[14] M. L. D. Santos, F. P. Arantes, T. C. Pessali, and J. E. D. Santos, "Morphological, histological and histochemical analysis of the digestive tract of Trachelyopterusstriatulus (Siluriformes: auchenipteridae)," *Zoologia (Curitiba)*, vol. 32, no. 4, pp. 296–305, 2015.

[15] H. M. Murray, G. M. Wright, and G. P. Goff, "A comparative histological and histochemical study of the post-gastric alimentary canal from three species of pleuronectid, the Atlantic halibut, the yellowtail flounder and the winter flounder," *Journal of Fish Biology*, vol. 48, no. 2, pp. 187–206, 1996.

[16] X. Dai, M. Shu, and W. Fang, "Histological and ultrastructural study of the digestive tract of rice field eel, *Monopterus albus*," *Journal of Applied Ichthyology*, vol. 23, no. 2, pp. 177–183, 2007.