Hindawi
Journal of Nanomaterials
Volume 2023, Article ID 8201449, 8 pages
https://doi.org/10.1155/2023/8201449

Research Article

Physicochemical Assessment of Zinc Oxide Nanoparticle and *Moringa oleifera* Supplementation on the Male Reproductive System of a Diabetic Rat Model

Arslan Shaukat,[1] Umair Rasool,[2] Farhan Saeed,[2] Yasir Abbas Shah,[3] Muhammad Afzaal,[3] and Mahbubur Rahman Khan[4]

[1]*Department of Physiology, Government College University, Faisalabad, Pakistan*
[2]*University of Agriculture, Faisalabad, Pakistan*
[3]*Food Safety and Biotechnology Lab, Department of Food Science, Government College University, Faisalabad, Pakistan*
[4]*Department of Food Processing and Preservation, Hajee Mohammad Danesh Science & Technology University, Dinajpur, Bangladesh*

Correspondence should be addressed to Mahbubur Rahman Khan; emon.1707047@std.hstu.ac.bd

Received 24 January 2023; Revised 14 October 2023; Accepted 18 October 2023; Published 1 December 2023

Academic Editor: Kaliannan Durairaj

The probable synergistic effect of chemically synthesized zinc oxide nanoparticles and locally secured *Moringa oliefera* was assessed on diabetic rats' model along with a potential effect on the male reproductive system and rat male serological markers. The plant *M. oliefera* was procured from the University of Agriculture Faisalabad step solvothermal method was utilized to synthesize the zinc oxide nanoparticles. The zeta sizer, UV–vis, and spectroscopic analysis of ZnO nanoparticles were undertaken. A total of 50 healthy male albino Wistar rats weighing 250 ± 10 g were used in the experimental research study having were divided into six stops designated as negative control, positive control (PC), standard control (Std. C), ZnO nanoparticle group (ZnO), *M. oliefera* Group (MO), and a group of combinations thereof (ZnONP + MO). The mean body weight was observed to be significantly normalized in group ZnONP + MO, i.e., 230 ± 6 g in contrast to PC, i.e., 162 ± 4 g; $P \leq 0.05$. The ZnONP + MO combination had a normoglycemic effect, i.e., 154.4 ± 4.5 mg/dl as in opposition to the PC, i.e., 315.7 ± 3 mg/dl. The serum level of rat testosterone in the ZnONP + MO group was observed at 0.958 ± 0.08 ng/ml in opposition to PC, which revealed it at 0.442 ± 0.02 ng/ml. The follicle-stimulating hormone level in the ZnONP + MO group was recorded at 10.04 ± 0.04 mlU/ml significantly varied from the PC, whose level was noted at 5.08 ± 0.09 mlU/ml. The level of LH in the ZnONP + MO group was observed at 6.89 ± 0.08 mIU/ml, significantly different from PC at 3.78 ± 0.08 mIU/ml. Histopathological changes in the rat testes treated with alloxan alone revealed the distortion in the epithelium of seminiferous tubules (H&E stain). However, the histopathology of testes isolated from rats treated with the zinc oxide nanoparticle and *M. oliefera* combination showed almost normal spermatogenic activity, the lumen of seminiferous tubules contained sperms, normal spermatids, and outer epithelium layer of seminiferous tubules was intact.

1. Introduction

Diabetes mellitus is a metabolic disorder associated with insufficient insulin secretion, insensitivity of the endogenous insulin to its receptors, and progressive failure of pancreatic β-cells resulting in hyperglycemia [1]. It is a syndrome resulting from the interactions of environmental and hereditary factors that affect metabolism involving proteins, carbohydrates, and fats in addition to the risk of damaging the pancreas, liver, kidney, and testes [2, 3]. There is a crucial link between diabetes and compromised reproductive functioning in males. Diabetes mellitus elicits a decrease in testosterone levels along with a reduction in the functionality and concomitant weight of the testes, vas deferens, epididymis, prostate gland, and seminal vesicle. Moreover, testicular histology of chronic diabetic subjects reveals a decrease in testicular volume and weight along with lysis of seminiferous tubules, disorientation of spermatids, and reduction in Leydig cells [4]. Diabetes mellitus is treated and managed by insulin

and oral hypoglycemic drugs [5]. However, effective therapy for diabetes mellitus is still not available in modern medicine, and oral synthetic hypoglycemic drugs are not completely successful in managing diabetes [6].

Zinc plays a crucial role in different metabolic pathways, including glucose metabolism [7]. Zinc is also known to augment the functioning of insulin and plays a vital role in insulin biosynthesis, storage, and secretion [8]. Bionanotechnology is the field of material science that arises at the intersection of biology and nanotechnology. Nanoparticles are the main products of this field. Nanoparticles are defined as ultra-small entities measuring 1–100 nm. They are being employed in fields as diverse as therapeutics, diagnostics, drug delivery, medical imaging, tumor suppression, etc. Within the context of DM, zinc oxide nanoparticles have been investigated to have promising potential and merit further investigations [9].

Zinc oxide nanoparticles (ZnONPs) are agents that have recently been utilized to deliver zinc and have implications in many disease therapies including diabetes mellitus [10]. ZnONPs have been shown to effectively mitigate diabetes-induced pancreatic structural, ultrastructural, and functional injuries [11]. Recent investigations have revealed that Zn and ZnONPs supplementation facilitates the normalization of blood glucose and serum insulin levels. It also restores the sensitivity of the insulin receptor to insulin [12].

Recent studies have demonstrated that supplementation with ZnONPs in rats exposed to nicotine significantly mitigates the adverse effects of such exposure by reducing oxidative stress and enhancing the expression of steroidogenic enzymes, thereby potentially enhancing male fertility [13]. Thus, the development of a zinc-based agent would be promising in the treatment of diabetes and its associated complications as zinc supplements have shown ameliorating effects in various studies [10, 14]. In this regard, ZnONPs merit further investigation within the context of their antidiabetic potential and their effect on the male reproductive system as this aspect has not been fully explored previously. Herbs that contain various phytoconstituents, such as flavonoids, terpenoids, saponins, carotenoids, alkaloids, and glycosides, have been reported to possess antidiabetic properties. In developing countries, medicinal plants are used to treat diabetes mellitus to overcome the burden cost of conventional medicine [15]. *Moringa oleifera* (MO), also known as the Drumstick tree, has been used to mitigate the effects of diabetes due to its antidiabetic properties. Leaves, fruits, and stem bark of this plant have been reported to have antidiabetic activity [16–20]. A recent study in alloxan-induced diabetic rats found that *M. oleifera* leaves had a hypoglycemic effect and prevented body weight loss [21]. However, the curative properties of this medical plant in alloxan-induced diabetes mellitus associated with the testicular gonadal axis and reproductive functionality are poorly understood and yet to be studied in detail. In the present study, we undertake such an endeavor. Hence, we aim to investigate the effects of ZnONPs singly and in combination with MO on alloxan-induced diabetic rats and the male rat gonadal tissue.

2. Experiments

2.1. Materials and Methods

2.1.1. Preparation of M. Oliefera Extract. The plant *M. oliefera*, oliefera, locally known as the Horse Reddish tree, was collected from fields of the University of Agriculture Faisalabad (UAF) in January. Plants were identified by the Department of Botany, GCUF. Identification number for *M. oliefera* was 284-bot-22. Plant leaves were separated and washed gently with water, cut into pieces, and kept for drying under shade. The leaves were dried completely after 25 days and then subjected to crushing and grinding to obtain a coarse powder. It was subjected to maceration. After complete maceration, the powder was filtered by using the Whatman number 2 filter paper twice. The filtrate obtained was evaporated using a rotary evaporator under reduced pressure until all the solvent evaporated leaving behind thick plant residue. A concentrated paste was obtained by drying in Petri plates. The leaf extracts were stored in bottles below 10°C in the refrigerator separately.

2.1.2. Zinc Oxide Nanoparticles Preparation. Zinc oxide nanoparticles were prepared in the Biochemistry Laboratory, UAF. A one-step solvothermal method was utilized to synthesize the zinc oxide nanoparticles. First, the dissolution of zinc acetate dihydrate (13.2 mmol) was undertaken in alcohols. A potassium hydroxide solution (28.4 mmol) was dropwise subjected to addition to the zinc acetate solution at 52°C. Nanoparticles started to precipitate and the solution became turbid. It was stirred rigorously for 2 hr after which it was allowed to sit for 1 hr. Excess liquid was removed and the precipitate was twice washed with 50 ml methanol and collected by 20 min centrifugation at 10^3 RPM. It was allowed to dry at room temperature for 1 day. The obtained solid was crushed to obtain white powder. It was subsequently dispersed in PVA with an ultrasonicator. The nanoparticles were stable and equally dispersed [22, 23]. The nanoparticles were characterized via, Zetasizer, UV–vis spectroscopy, and scanning electron microscopy.

2.1.3. Experimental Animal Used. A total of 50 healthy male albino Wistar rats weighing 250 ± 10 g were used in the experimental research study. Rats were obtained from the experimental animal house at the Institute of Pharmacy, Physiology, and Pharmacology, UAF. They were kept in well-aerated cages at 24 ± 2°C in a 12 hr light and dark cycle, with surrounding humidity (40%–60%). For 6 weeks, the animals were provided ad libitum standard diet and water. Cleaning and changing water and food were done for all animals twice a day. Ethical rules on care and utilization of animal models for human disease were taken from the institutional bioethics committee (Ref no. 145), University of Agriculture Faisalabad, Pakistan.

2.1.4. Induction of Experimental Diabetes. Experimental diabetes mellitus was induced by a single intraperitoneal injection of alloxan monohydrate (Sigma Chemical Co., Poole, Dorst, UK) having a dose rate of 130 mg/kg. Before induction

Table 1: Experimental design.

Group	Group ID	Administration route	Treatment
Negative control	NC	Oral gavage	Routine diet + normal saline (1.0 ml/kg of body weight)
Diabetic untreated positive control	PC	Oral gavage	Alloxan + routine diet + normal saline (1.0 ml/kg of body weight)
Standard treatment group	Std. C	Oral gavage	Glimepiride 0.1 mg/kg of body weight
The treatment group was given zinc oxide nanoparticles	ZnONP	Oral gavage	Zinc oxide nanoparticles dosage at 7.5 mg/kg of body weight
The treatment group was given *M. oleifera*	MO	Oral gavage	*M. oleifera* dosage at 250 mg/kg of body weight
The treatment group was given zinc oxide nanoparticles plus *M. oleifera*	ZnONP + MO	Oral gavage	Zinc oxide nanoparticles dosage at (7.5 mg/kg) of body weight plus *M. oleifera* dosage at 250 mg/kg of body weight

rats were kept for 12 hr in a fasting condition. After 72 hr of injection, fasting blood glucose was measured with the help of the blood glucose monitoring system (On-Call EZ II). Blood glucose test strips (On Call Plus ACON Laboratories, Inc., USA) and the rats with blood glucose levels over 200 mg/dl were considered diabetic and grouped in the diabetic group.

2.1.5. Experimental Design. Animals were randomly divided into six groups ($n = 8$). The trial was run in triplicate. Group 1 of animals was considered a negative control (NC) and received normal saline (1 ml/kg body wt.) along with a routine diet for the duration of the 6-week trial. Group 2, the positive control (PC), received a single intraperitoneal dose of Alloxan monohydrate (130 mg/kg). Group 3 received a standard commercially available antidiabetic medication glimepiride at a dose rate of 0.1 mg/kg of body weight. The remaining three treatment groups were treated with ZnONPs, MO, and a combination of the two (Table 1).

The optimum, safe, and effective dosages of the ZnO nanoparticles and *M. oleifera* were assessed from the already published wealth of literature [24–27]. ZnONPs were dissolved in water by constant magnetic stirring for 25 min at 37°C. The amount of ZnONPs and MO leaf extract for each adult rat was calculated based on their weight. The suspension was administered orally to each adult albino rat via oral gavage.

2.1.6. Determination of Body Weight, Serum Glucose, Serum Insulin, and Serum Glucagon. The body weight was evaluated at regular intervals of 7 days. The estimation of the blood glucose was done via the established strip method (*Accu-Check* by Roche®). The routinely employed enzyme-linked im-immunosorbent assay (ELISA) was employed for the assessment of serum insulin and glucagon (Ray biotech; Catalog no.: E-EL-R0425).

2.1.7. Determination of Reproductive Hormones. For quantitative determination of follicle-stimulating hormone (FSH), standard ELISA was employed (Rat FSH ELISA Kit Catalog no.: MBS2502190; My BioSource R). Luteinizing hormone (LH) was assessed by Rat LH ELISA Kit; Catalog no.: MBS764675; My BioSource R. Rat testosterone was evaluated via the rat testosterone ELISA kit; Catalog no.: SE120089; My BioSource R.

2.1.8. Histopathological Examination of Testes. At the end of the trial, rat testes were isolated, and preserved in Bouin's solution for histopathological examination. Then, tissues were embedded in paraffin, sectioned, and stained with hematoxylin and eosin (H&E). The composition of Bouin's solution is saturated picric acid (1,500 ml), formaldehyde (500 ml), and glacial acetic acid (100 ml).

2.1.9. Statistical Analysis. Statistical analysis was conducted by one-way analysis of variance (ANOVA) followed by Duncan's multiple ranges tests at 5% level significance ($P < 0.05$) [28]. Statistical Package for the Social Sciences (SPSS, version 16.0 and GraphPad Prism software version 8.00) was used for statistical analysis.

3. Results and Discussion

3.1. Nanoparticle Characterization: Zetasizer Analysis, UV–Vis Analysis, and Scanning Electron Microscopy Analysis. The spectroscopic analysis (V-730 UV–Visible Spectrophotometer, Jasco R) of ZnO nanoparticles was undertaken and showed a distinct peak at 370 nm, and it was found to agree with various research [23, 29] (Figure 1(a)). The nanoparticle size was corroborated by evaluating the nanoparticles with a zeta sizer (Malvern Zetasizer; Nano-ZS90). The size of the ZnO nanoparticles was noted to be in the range of 25–35 nm, as shown in Figure 1(b). Scanning electron micrography (JSM-IT200 InTouch Scope™; Jeol R) revealed the formation of spherical and rhomboidal nanoparticles within the specified range of 25–35 nm, as shown in Figure 1(c).

3.2. Assessment of Zinc Oxide Nanoparticle and Moringa oliefera and a Combination Thereof on the Concentration of Serum Glucose, Serum Insulin, and Glucagon and Mean Body Weight. The mean body weight was significantly normalized in the group ZnONP + MO, i.e., 230 ± 6 g as compared with the PC, i.e., 162 ± 4 g; $P \leq 0.05$. This effect was markedly better than the MO treatment alone revealing a mean body weight of 188 ± 3 g; $P \leq 0.05$ (Figure 2). The ZnONP + MO combination exerted a normoglycemic effect in the treatment group, i.e., 154.4 ± 4.5 mg/dl in contrast with the PC, i.e., 315.7 ± 3 mg/dl. This effect was followed by the effect of the *M. oliefera* treatment group, i.e., 212.6 ± 7 g. $P \leq 0.05$ (Figure 2(a)). The NC revealed 16.4 UI/ml of insulin

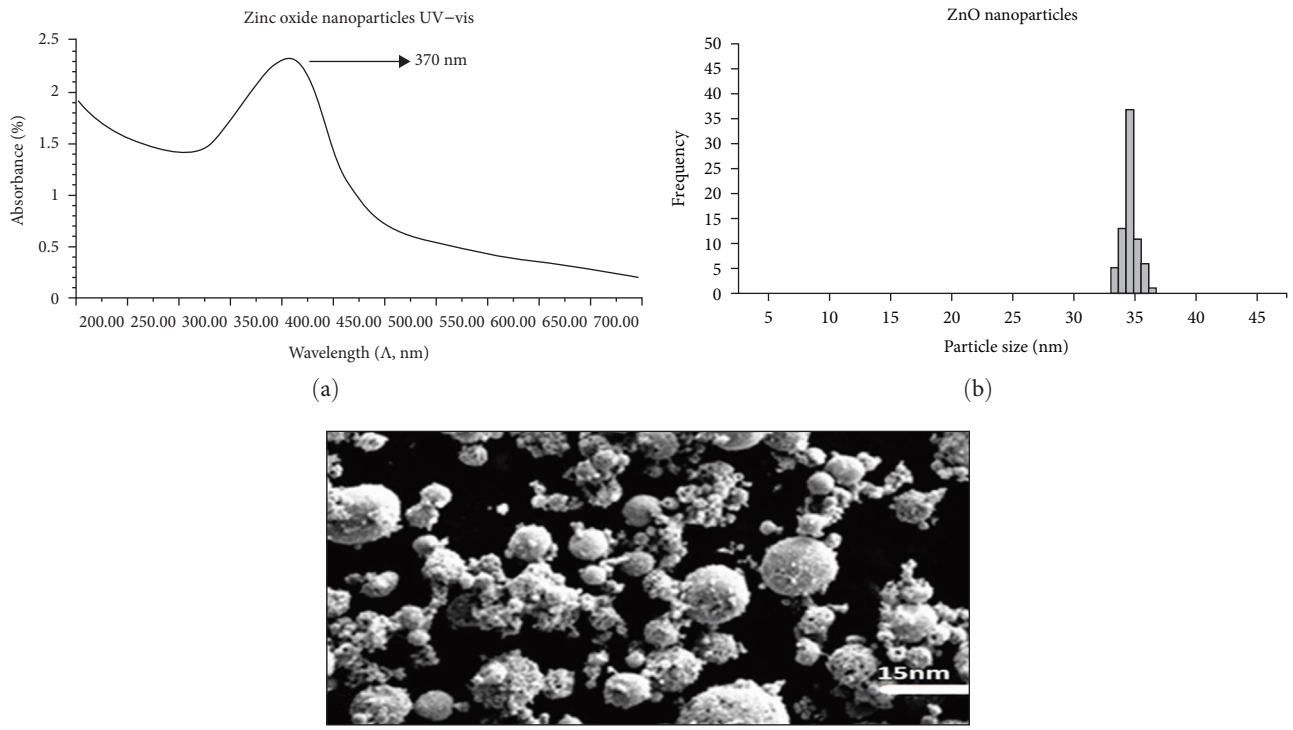

Figure 1: (a) ZnONP spectroscopy. (b) Zetasizer analysis. (c) SEM analysis.

concentration $P \leq 0.05$ (Figure 2(b)). ZnONP + MO combination exerted a normalizing effect on insulin secretion, i.e.,13.9 uIL/ml as in contrast with the PC, i.e., 6.2 uIL/ml $P \leq 0.05$ (Figure 2(b)). The serum glucagon concentration revealed $1{,}997 \pm 41.5$ pg/ml in contrast with the PC, i.e., $3{,}650 \pm 45$ pg/ml $P \leq 0.05$ (Figure 2(c)).

3.3. Assessment of Zinc Oxide Nanoparticle and Moringa oliefera and a Combination Thereof on the Concentration of Serum Testosterone, Luteinizing Hormone, and Follicle-Stimulating Hormone. The serum concentration of rat testosterone in the ZnONP + MO group was noted at 0.958 ± 0.08 ng/ml as contrasted with the PC, which revealed it at 0.442 ± 0.02 ng/ml (Figure 3(c); $P \leq 0.05$). The MO-treated group had a testosterone level of 0.776 ± 0.04 ng/ml as contrasted with NC at 0.96 ± 0.04 ng/ml (Figure 3(c); $P \leq 0.05$). The follicle-stimulating hormone level in the ZnONP + MO group was observed at 10.04 ± 0.04 mlU/ml, which was statistically significantly different from the PC, whose level was noted at 5.08 ± 0.09 mlU/ml (Figure 3(b); $P \leq 0.05$). Its level in NC was recorded at 10.77 ± 0.04 mlU/ml (Figure 3(b); $P \leq 0.05$). The level of LH in the ZnONP + MO group was observed at 6.89 ± 0.08 mIU/ml which was statistically significantly different than PC which revealed it at 3.78 ± 0.08 mIU/ml (Figure 3(a); $P \leq 0.05$).

3.4. Effect of Glimepiride, Zinc Oxide Nanoparticle, and Moringa oliefera on Histopathological Changes Induced by Alloxan in Testes of Rats. Histopathological changes in the testes of rats treated with alloxan alone showed the distortion in the epithelium of seminiferous tubules (Figure 4(a); 40x; H&E stain). In the PC, the lumen of tubules was empty, which indicates no spermatogenic activity (Figure 4(b); 40x; H&E stain). Immature spermatids were seen and tubules were reshaped, which ultimately reduced the testes' weight in the standard control (Figure 4(c); 40x; H&E stain). Distorted seminiferous epithelium with an empty lumen was seen when treated with ZnO nanoparticles alone (Figure 4(d); 40x; H&E stain). Destruction of the Leydig cells was noted which results in decreased testosterone production (Figure 4(e); 40x; H&E stain). However, the histopathology of testes isolated from rats treated with the zinc oxide nanoparticle and *M. oliefera* combination showed almost normal spermatogenic activity, the lumen of seminiferous tubules contained sperms, normal spermatids, outer epithelium layer of seminiferous tubules was intact (Figure 4(f); 40x; H&E stain).

Diabetes, now a day, has become one of the leading metabolic disorders in the world. It is on the rise, and its prevalence is increasing with each passing day, especially in the middle-income countries of the world. The available therapies have quite a few adverse effects in the present study, diabetes was induced in Wistar albino rats by alloxan monohydrate injected intraperitoneally at a dose of 130 mg/kg of body weight. Alloxan is a glucose analog having a toxic effect on pancreatic β-cells; it readily destroys them when administered to rodents. It was quickly and selectively taken ken up by β-cells followed by the production of reactive oxygen species ROS, superoxide radicals, and hydrogen peroxide by the redox cycle [30]. Consequently, the antihyperglycemic and gonad protective effect of *M. oliefera* (MO) and zinc oxide nanoparticles (ZnONPs) alone and in combination

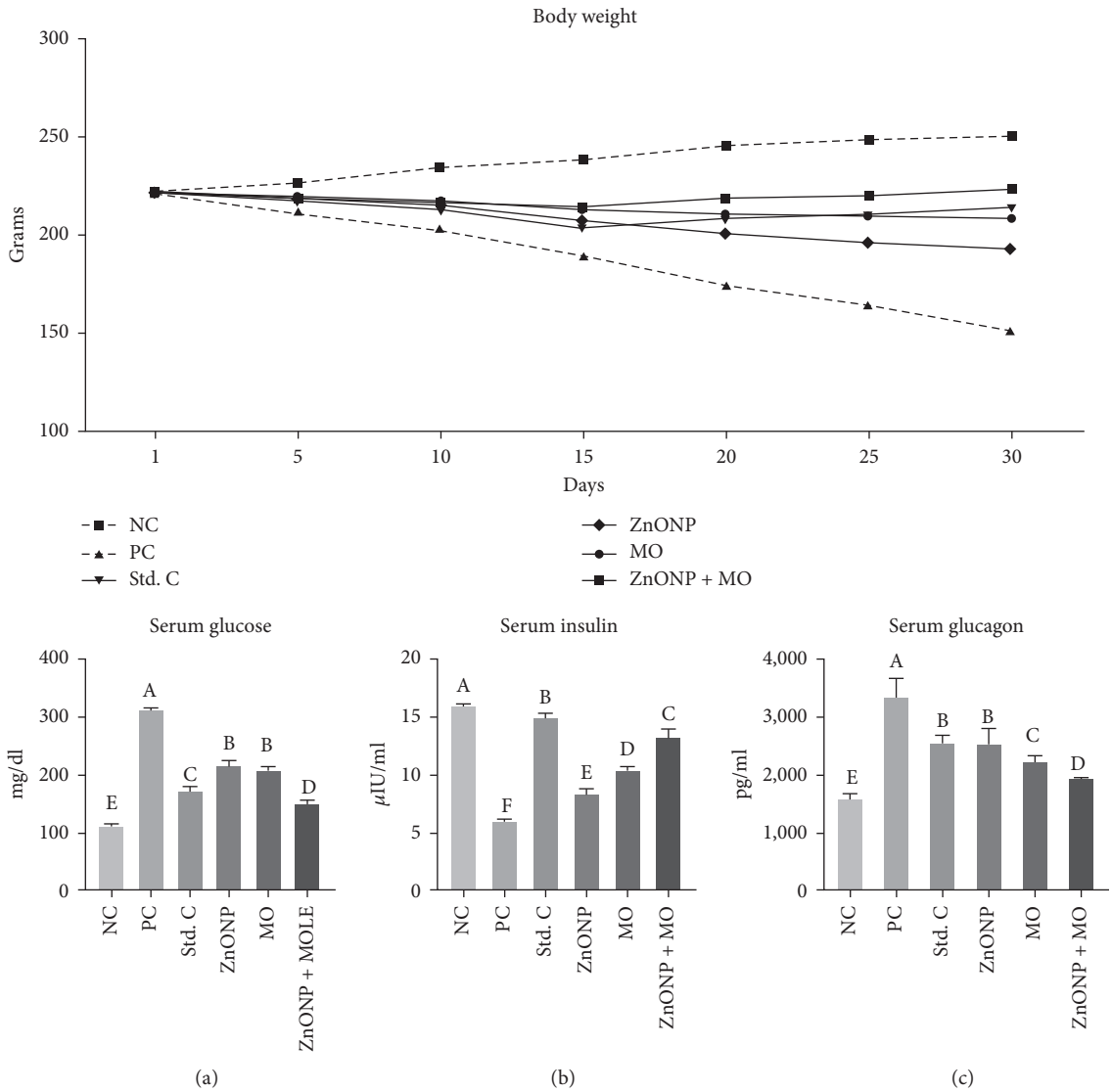

Figure 2: Assessment of zinc oxide nanoparticle and *M. oliefera* and a combination thereof on the concentration of serum glucose (a), serum insulin (b), and serum glucagon (c) and mean body weight. [A,B,C,D,E,F]Different superscript letters indicate significant differences ($P<0.05$).

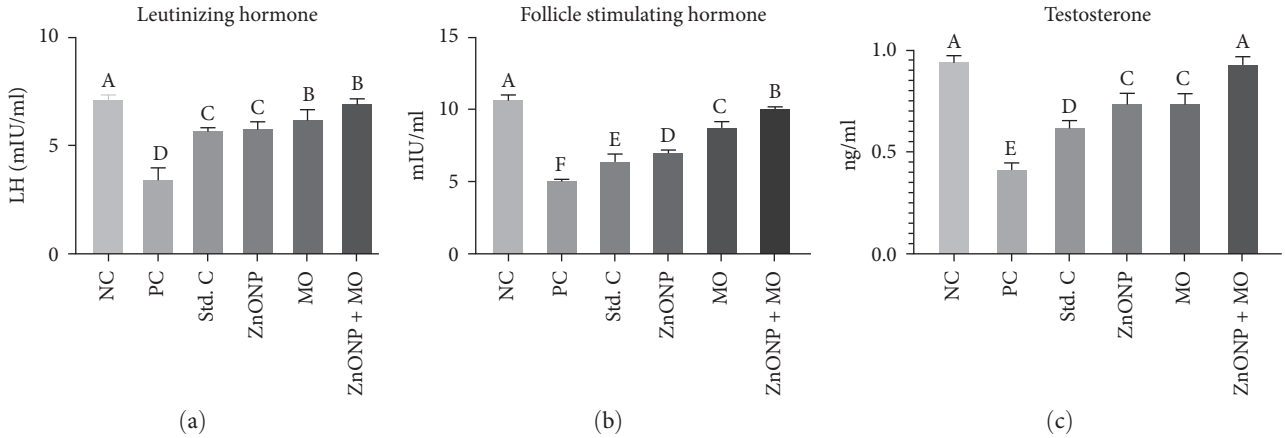

Figure 3: Assessment of zinc oxide nanoparticle and *M. oliefera* and a combination thereof on luteinizing hormone (a), follicle-stimulating hormone (b), and serum testosterone (c). [A,B,C,D,E,F]Different superscript letters indicate significant differences ($P<0.05$).

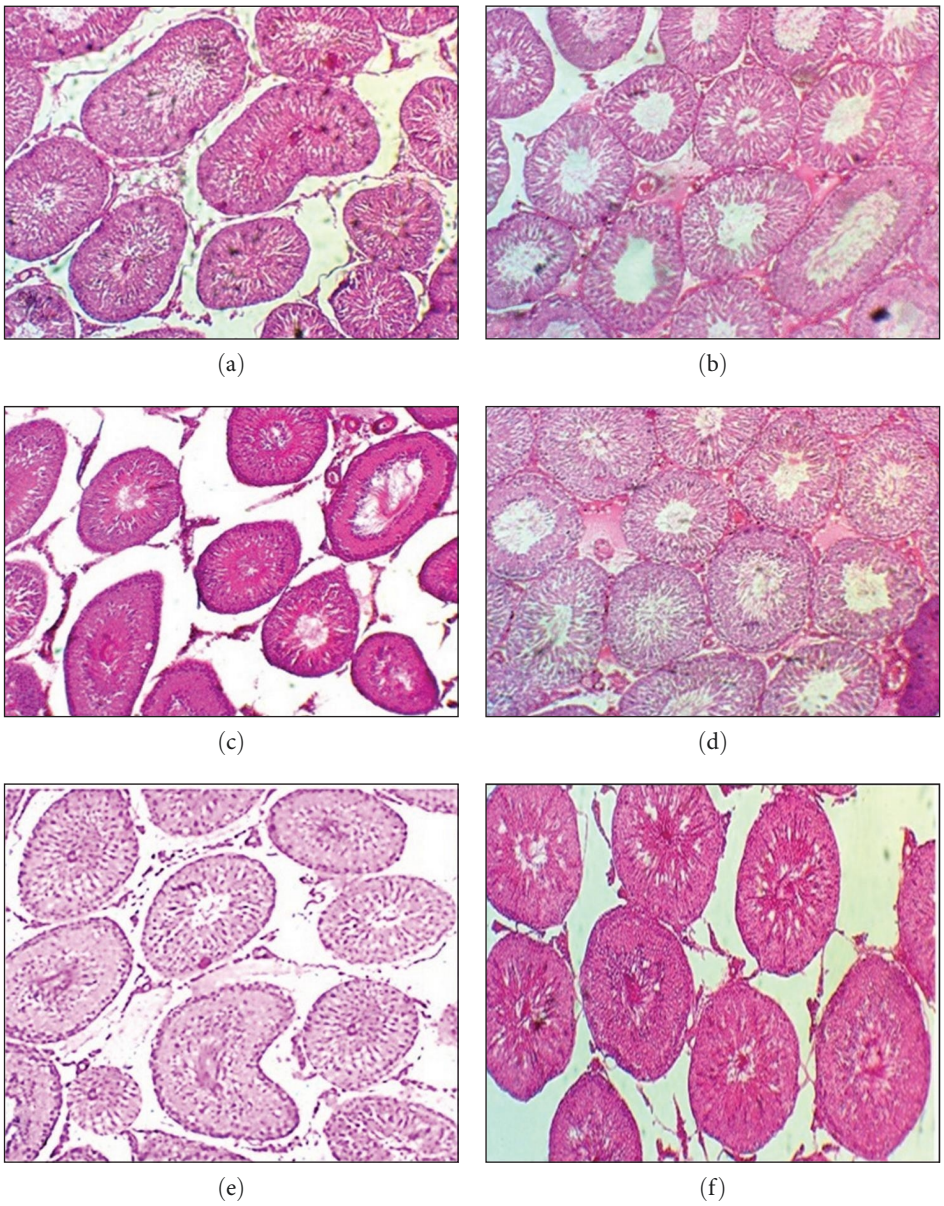

Figure 4: Assessment of zinc oxide nanoparticle and *M. oliefera* and combination thereof on testes histology: (a) NC, (b) PC, (c) Std., (d) ZnONP, (e) MO, and (f) ZnONP + MO.

thereof was assessed. The one-step solvothermal method utilized in the present study was found to be a highly effective, cost-effective, and efficient method for nanoparticle synthesis. The nanoparticles synthesized were generally of uniform shape and within the size range of 25–35 nm. We report that one-step solvothermal process for zinc oxide nanoparticle synthesis can be upscaled for the bulk amount of nanoparticle production as well. The current study was designed to investigate the antidiabetic activity of the plant *M. oleifera* in Alloxan-induced diabetic rats. This plant was selected because it is taken as food and is also used as a medicinal plant for the treatment of the respiratory system, digestive system, ulcers, urinary system, and for inflammation. It has been reported to be used traditionally as an antidiabetic agent. The treated diabetic rats with a high dose of *M. oleifera* extract recorded a significant decrease in blood glucose level and a significant increase in insulin and this was in agreement with a previous study [31]. Concerning the antidiabetic effects of MO, it is plausible that its active constituents are responsible for it. These include the antidiabetic constituents (glucoside, quercetin, chlorogenic acid, and moringinine). The therapeutic property of this plant may be due to its regenerative potential affecting pancreatic β-cell, increasing insulin secretion and uptake in skeletal muscles, and decreasing insulin resistance. However, further studies are needed to evaluate the precise mechanism of action for this beneficial herbal plant [32].

Oral administration of zinc oxide nanoparticles resulted in significant antidiabetic effects, that is, improved glucose tolerance, higher serum insulin, and reduced blood glucose. Nanoparticles were systemically absorbed resulting in elevated zinc levels. Nanoparticles were safe up to 7.5 mg/kg body weight and previous studies have shown that they are

safe up to 300 mg/kg dose in rats [11]. In the present study, the ZnONP + MO combination exerted a normoglycemic effect in the treatment group F, i.e., 154.4 ± 4.5 mg/dl as in contrast with the PC, i.e., 315.7 ± 3 mg/dl. This effect was followed by the effect of *M. oliefera* treatment group, i.e., 212.6 ± 7 g.

The main causal rationale behind these observed effects probably is because zinc has been shown to have an antihyperglycemic effect and it lowers blood glucose by increasing the uptake of glucose from the blood into the cells. Our observation agrees with earlier studies [33, 34]. Our work reveals that ZnONP + MO had a protective effect on the overall parenchymatous structure of the male reproductive tract including the seminiferous tubule shape, spermatogenesis activity, and presence or absence of Leydig cell. Within this context, research has already shown that the bulk form of zinc had a protective effect on the rat male reproductive system [35].

The present study supports their finding and we report that the combination of ZnONP + MO can plausibly be a suitable alternative to bulk supplementation by zinc. However, further work is still required to elucidate whether the protective effect of ZnONP + MO is localized or global within the context of the entire biochemical machinery of the organism.

4. Conclusion

Diabetes adversely affects the rat's testes. There is increased blood glucose level, decreased body weight, decreased testicular weight, poor oral glucose tolerance, and unusual hematological parameters. Histopathology showed the disrupted epithelium of seminiferous tubules, the empty lumen of the tubules indicated no spermatogenic activity, and the destruction of Leydig cells. Diabetes-induced (morphological and histopathological) changes are recovered with zinc oxide nanoparticles and *M. oleifera* having a synergistic antidiabetic effect and protective effect on the rat reproductive system and LH, FSH, and testosterone levels. Histopathology of treated groups showed intact epithelium and sperms in the lumen of seminiferous tubules.

Data Availability

Even though adequate data have been given in the form of tables and figures; however, all authors declare that if more data are required then the data will be provided on a request basis.

Disclosure

The preprint of the paper is already published by Shoukat et al. 2022. "Shaukat, A., Rasool, U., Saeed, F., Shah, Y. A., & Afzaal, M. (2022). Functional assessment of Zinc oxide nanoparticle and *Moringa oleifera* supplementation on the male reproductive system of a diabetic rat model."

Conflicts of Interest

The authors declare that they have no conflicts of interest.

Authors' Contributions

Arslan Shaukat and Umair Rasool proposed this idea and conducted this research. Farhan Saeed and Muhammad Afzaal prepared the manuscript and also aided in conducting this research. Yasir Abbas Shah and Mahbubar Rahman Khan helped in and in validation and preparation of figures and tables.

Acknowledgments

The authors are thankful to the Government College University Faisalabad and the University of Agriculture Faisalabad for providing technical support and laboratory facilities during research work.

References

[1] A. P. Rolo and C. M. Palmeira, "Diabetes and mitochondrial function: role of hyperglycemia and oxidative stress," *Toxicology and Applied Pharmacology*, vol. 212, no. 2, pp. 167–178, 2006.

[2] S. Ghosh and S. A. Suryawanshi, "Effect of vinca rosea extracts in treatment of alloxan diabetes in male albino rats," *Indian Journal of Experimental Biology*, vol. 39, no. 8, pp. 748–759, 2001.

[3] D. Cheng, B. Liang, and Y. Li, "Antihyperglycemic effect of Ginkgo biloba extract in streptozotocin-induced diabetes in rats," *BioMed Research International*, vol. 2013, Article ID 162724, 7 pages, 2013.

[4] W. R. Scarano, A. G. Messias, S. U. Oliva, G. R. Klinefelter, and W. G. Kempinas, "Sexual behaviour, sperm quantity and quality after short-term streptozotocin-induced hyperglycaemia in rats," *International Journal of Andrology*, vol. 29, no. 4, pp. 482–488, 2006.

[5] B. T. Francis and S. Sudha, "Histopathological changes on streptozotocin induced diabetic rats following administration of polyherbal extract: a study on pancreas and kidney," *World Journal of Pharmaceutical Sciences*, vol. 5, pp. 1188–1200, 2016.

[6] S. Kumar, "Preclinical evaluation of antidiabetic and hypolipidemic effects of hibiscus tiliaceus," *World Journal of Pharmaceutical Research*, vol. 3, no. 10, pp. 5041–5048, 2014.

[7] H. Haase, S. Overbeck, and L. Rink, "Zinc supplementation for the treatment or prevention of disease: current status and future perspectives," *Experimental Gerontology*, vol. 43, no. 5, pp. 394–408, 2008.

[8] Q. Sun, R. M. van Dam, W. C. Willett, and F. B. Hu, "Prospective study of zinc intake and risk of type 2 diabetes in women," *Diabetes Care*, vol. 32, no. 4, pp. 629–634, 2009.

[9] G. K. Rohela, Y. Srinivasulu, and M. S. Rathore, "A review paper on recent trends in bio-nanotechnology: implications and potentials," *Nanoscience & Nanotechnology-Asia*, vol. 9, no. 1, pp. 12–20, 2018.

[10] K. S. Tang, "The current and future perspectives of zinc oxide nanoparticles in the treatment of diabetes mellitus," *Life Sciences*, vol. 239, Article ID 117011, 2019.

[11] R. D. Umrani and K. M. Paknikar, "Zinc oxide nanoparticles show antidiabetic activity in streptozotocin-induced type 1 and 2 diabetic rats," *Nanomedicine*, vol. 9, no. 1, pp. 89–104, 2014.

[12] R. M. El-Gharbawy, A. M. Emara, and S. E.-S. Abu-Risha, "Zinc oxide nanoparticles and a standard antidiabetic drug restore the function and structure of beta cells in type-2

diabetes," *Biomedicine & Pharmacotherapy*, vol. 84, pp. 810–820, 2016.

[13] D. A. Mohamed and S. A. Abdelrahman, "The possible protective role of zinc oxide nanoparticles (ZnONPs) on testicular and epididymal structure and sperm parameters in nicotine-treated adult rats (a histological and biochemical study)," *Cell and Tissue Research*, vol. 375, no. 2, pp. 543–558, 2019.

[14] J. U. Ukperoro, N. Offiah, T. Idris, and D. Awogoke, "Antioxidant effect of zinc, selenium and their combination on the liver and kidney of alloxan-induced diabetes in rats," *Mediterranean Journal of Nutrition and Metabolism*, vol. 3, no. 1, pp. 25–30, 2010.

[15] G. Arumugam, P. Manjula, and N. Paari, "A review: anti diabetic medicinal plants used for diabetes mellitus," *Journal of Acute Disease*, vol. 2, no. 3, pp. 196–200, 2013.

[16] A. Kar, B. K. Choudhary, and N. G. Bandyopadhyay, "Comparative evaluation of hypoglycaemic activity of some Indian medicinal plants in alloxan diabetic rats," *Journal of Ethnopharmacology*, vol. 84, no. 1, pp. 105–108, 2003.

[17] S. Semenya, M. Potgieter, and L. Erasmus, "Ethnobotanical survey of medicinal plants used by bapedi healers to treat diabetes mellitus in the Limpopo Province, South Africa," *Journal of Ethnopharmacology*, vol. 141, no. 1, pp. 440–445, 2012.

[18] R. Maiti, H. González Rodríguez, A. Kumari, and N. Chandra Sarkar, "Macro and micro-nutrient contents of 18 medicinal plants used traditionally to alleviate diabetes in nuevo leon, northeast of Mexico," *Pakistan Journal of Botany*, vol. 48, no. 1, pp. 271–276, 2016.

[19] B. Geleta, E. Makonnen, A. Debella, A. Abebe, and N. Fekadu, "In vitro vasodilatory activity and possible mechanisms of the crude extracts and fractions of moringa stenopetala (Baker f.) Cufod. leaves in isolated thoracic aorta of guinea pigs," *Journal of Experimental Pharmacology*, vol. 8, pp. 35–42, 2016.

[20] A. M. Dièye, A. Sarr, S. N. Diop et al., "Medicinal plants and the treatment of diabetes in Senegal: survey with patients," *Fundamental & Clinical Pharmacology*, vol. 22, no. 2, pp. 211–216, 2008.

[21] A. Villarruel-López, D. A. López-de la Mora, O. D. Vázquez-Paulino et al., "Effect of moringa oleifera consumption on diabetic rats," *BMC Complementary and Alternative Medicine*, vol. 18, no. 1, pp. 1–10, Article ID 127, 2018.

[22] D. K. Singh, D. K. Pandey, R. R. Yadav, and D. Singh, "A study of nanosized zinc oxide and its nanofluid," *Pramana*, vol. 78, no. 5, pp. 759–766, 2012.

[23] A. K. Zak, R. Razali, W. H. A. Majid, and M. Darroudi, "Synthesis and characterization of a narrow size distribution of zinc oxide nanoparticles," *International Journal of Nanomedicine*, vol. 6, pp. 1399–403, 2011.

[24] H. J. Ryu, M. Y. Seo, S. K. Jung et al., "Zinc oxide nanoparticles: a 90-day repeated-dose dermal toxicity study in rats," *International Journal of Nanomedicine*, vol. 9, no. Suppl 2, pp. 137–144, 2014.

[25] A. K. Srivastav, M. Kumar, N. G. Ansari et al., "A comprehensive toxicity study of zinc oxide nanoparticles versus their bulk in Wistar rats: toxicity study of zinc oxide nanoparticles," *Human & Experimental Toxicology*, vol. 35, no. 12, pp. 1286–1304, 2016.

[26] R. Abbasalipourkabir, H. Moradi, S. Zarei et al., "Toxicity of zinc oxide nanoparticles on adult male wistar rats," *Food and Chemical Toxicology*, vol. 84, pp. 154–160, 2015.

[27] S. J. Stohs and M. J. Hartman, "Review of the safety and efficacy of moringa oleifera," *Phytotherapy Research*, vol. 29, no. 6, pp. 796–804, 2015.

[28] R. Steel, "Analysis of variance I: the one-way classification," in *Principles and Procedures of Statistics: A Biometrical Approach*, pp. 139–203, McGraw Hill, New York, NY, USA, 1997.

[29] B. N. Patil and T. C. Taranath, "Limonia acidissima L. leaf mediated synthesis of zinc oxide nanoparticles: a potent tool against mycobacterium tuberculosis," *International Journal of Mycobacteriology*, vol. 5, no. 2, pp. 197–204, 2016.

[30] T. Szkudelski, "The mechanism of alloxan and streptozotocin action in B cells of the rat pancreas," *Physiological Research*, vol. 50, no. 6, pp. 537–546, 2001.

[31] G. A. Asare, B. Gyan, K. Bugyei et al., "Toxicity potentials of the nutraceutical moringa oleifera at supra-supplementation levels," *Journal of Ethnopharmacology*, vol. 139, no. 1, pp. 265–272, 2012.

[32] S. Mahmood, *Hypoglycemic evaluation of berberis aristata (Sumlu) roots in normal and diabetic rabbits*, M. Phil thesis, Department of Physiology and Pharmacology, University of Agriculture Faisalabad, Pakistan, 2006.

[33] W. H. Almalki, E.-S. A. Arafa, A. Y. Abdallah et al., "Zinc chloride protects against streptozotocin-induced diabetic nephropathy in rats," *Pharmacology & Pharmacy*, vol. 07, no. 8, pp. 331–342, 2016.

[34] K. Hamden, S. Carreau, and A. Elfeki, "Inhibitory effects of zinc on hyperglycaemia and metabolic disorders in the liver of alloxan-induced diabetic rats," *Asian Biomedicine*, vol. 3, no. 6, pp. 745–750, 2009.

[35] H.-T. Gao, Q.-N. Di, L.-L. Qian et al., "Zinc supplement ameliorates phthalates-induced reproductive toxicity in male rats," *Chemosphere*, vol. 246, Article ID 125828, 2020.